



Animal &
Plant Health
Agency



Great Britain small ruminant quarterly report, disease surveillance and emerging threats

Volume 28: Quarter 4 – October to December 2025

Highlights

- Bluetongue page 3
- Chronic rhinitis in a ram page 4
- PGE and *Listeria ivanovii* infection in weaned lambs page 11
- *Bibersteinia trehalosi* septicaemia page 13
- Pine or cobalt deficiency page 16
- Yersiniosis in a goat page 17
- Ovine Protozoal Meningoencephalitis (OPM) page 20
- Oak or acorn poisoning page 23

Contents

Introduction and overview	2
APHA’s Emerging and Endemic Disease Alert System (EEDAS).....	2
Issues and trends	3
Bluetongue.....	3
Unusual diagnoses	4
Goat disease surveillance dashboard outputs	5
Sheep disease surveillance dashboard outputs.....	6
Changes in disease patterns and risk factors	7
Chemical food safety	23
Toxicity.....	23

Antimicrobial use and resistance	28
Centre of Expertise for Extensively Managed Livestock (COEEML).....	28
TSE.....	29
Horizon scanning	29
Publications of interest.....	30

Introduction and overview

This quarterly report reviews disease trends and threats for the fourth quarter of 2025 (Q4), October to December. It is compiled using data available at the time of writing. It contains interesting cases, and analyses carried out on disease data gathered from APHA, SRUC Veterinary Services division of Scotland’s Rural College (SRUC), and Surveillance Pathology Partners; and intelligence gathered through the Cattle Expert Group networks. We are aware that there were SRUC data missing from the database at the time of writing. This could not be rectified in time, and analysis and trends based on later updated data may therefore differ from this report. The focus will therefore be on trends detected in APHA data from England and Wales, plus interesting and unusual cases from the GB Surveillance Network. In addition, links to other sources of information, including reports from other parts of the APHA and Defra agencies, are included. A full explanation of [how data is analysed](#) is provided in the annexe available on GOV.UK.

APHA’s Emerging and Endemic Disease Alert System (EEDAS)

This is a component of the communications from our scanning surveillance network and a system that the APHA uses to keep you up to date with significant disease alerts and information, projects, publication of reports and other items. This is independent of the notifiable disease alert system.

To receive these notifications please respond to siu@apha.gov.uk, providing your preferred:

- email address you would like us to use
- mobile telephone number if you wish to receive text alerts

We hope that you find this EEDAS messaging system to be beneficial, and any suggestions or feedback are welcome.

Issues and trends

Weather

Details can be found at the [Met Office climate summaries](#) and the [Met Office UK temperature, rainfall and sunshine anomaly graphs](#).

Lamb sector update

Prices: GB deadweight lamb prices grew modestly in the last three months of 2025, with the New Season Lamb Standard Quality Quotation (NSL SQQ) averaging 712 pence per kilogram (p/kg) in the week ending 27 December. This was 21p/kg higher than the same period in 2024. Lamb numbers remained tighter through the quarter, supporting prices.

Production: Despite lower kills, Q4 sheep meat production was up 1% year-on-year to total 73,700 tonnes. Heavier carcass weights boosted production as producers capitalised on cheaper feed, averaging 20.6kg (+8kg). Total clean sheep slaughtering for the quarter totalled 3.2 million head, down 2% annually. Meanwhile, adult sheep slaughter declined by 4% on the year to 341,000 head.

Trade: UK fresh and frozen sheep meat imports in Q4 totalled 12,700 tonnes, a decrease of 7% year-on-year. Meanwhile, sheep meat exports were 1% up on the year to 24,400 tonnes for the quarter. Export values were up 7% on the year to £180 million, reflecting strong demand from Europe.

Demand: In the [12 weeks ending 28 December 2025](#), lamb saw a 3.8% increase in volumes purchased, accompanied by a 5.4% increase in spend year-on-year. Average prices paid increased by 1.6%. Lamb performed well during this period due to increased promotional activity at Christmas.

This sector update was provided by Hannah Clarke, Lead Analyst (Red Meat)
Agriculture and Horticulture Development Board

Bluetongue

The new 2025 to 2026 vector season started on the 1 July 2025. Between the start of the new season and 6 February 2026 there were 288 confirmed cases of bluetongue virus. In England, there have been 267 cases of bluetongue - including 259 cases of only BTV-3, 1 case of only BTV-8 and 7 cases with both BTV-3 and BTV-8. In Wales, there have been 21 cases of BTV-3. Figure 2 shows the distribution of cases. These interactive maps can be found at [Bluetongue Cases and Zones](#).

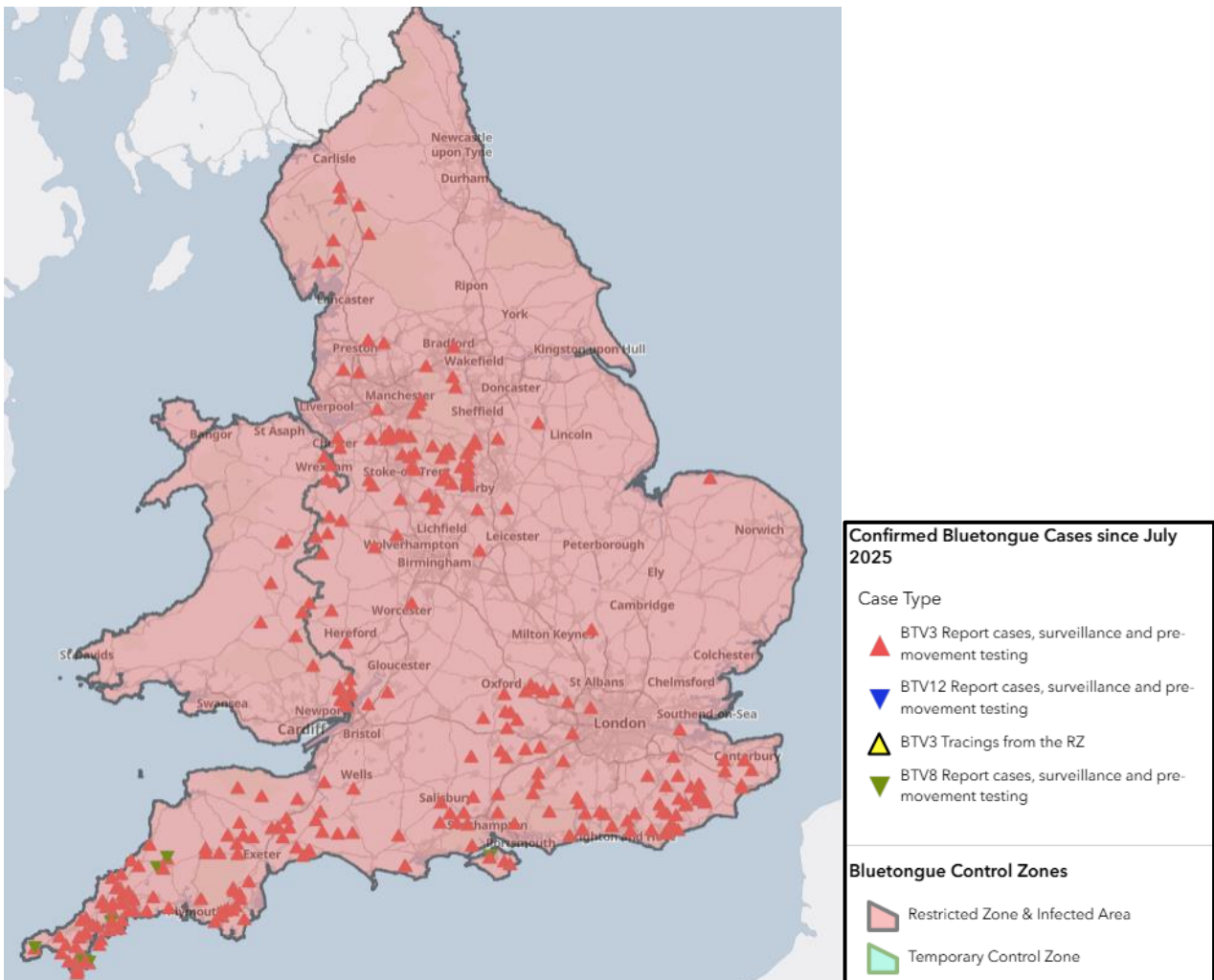


Figure 1: Map of England and Wales showing the confirmed bluetongue cases between 1 July 2025 and 6 February 2026

Images of the clinical signs can be found here: [Clinical signs of bluetongue | AHDB](#)

Bluetongue virus is a notifiable disease. Suspicion of bluetongue virus in animals must be reported to the Animal and Plant Health Agency on 03000 200 301 in England, on 03003 038 268 in Wales, and to the [local Field Services Office](#) in Scotland. Further guidance and information are available on the [Ruminant Health & Welfare site](#), [Bluetongue: information and guidance for livestock keepers \(GOV.UK\)](#) and on [Bluetongue: how to spot and report it \(GOV.UK\)](#).

Unusual diagnoses

Chronic rhinitis in a ram associated with *Salmonella enterica* subsp. *Diarizonae*

Salmonella enterica subsp. *Diarizonae* (serovar 61:k:1,5,7, sequence type 432) was isolated in a very heavy growth on direct bacterial culture of a nasal swab, submitted from a 2-year-old ram, that had a 6-month history of chronic pneumonia and a persistent nasal

discharge. *Salmonella enterica* subsp. *Diarizonae* (specifically serovar 61:k:1,5,(7)) can cause chronic proliferative rhinitis in sheep. Affected sheep develop inflammation and nasal polyps, particularly in the ventral turbinates, and can have a thick nasal discharge which may cause obstruction of the nasal passages and nasal stertor. It is unclear why some farms specifically see this presentation with *Salmonella enterica* subsp. *Diarizonae*, which is otherwise a common commensal bacterium in sheep. Other cofactors may play a role, such as an initiating inflammation from environmental respiratory irritants, or perhaps a prior nasal bot infection allowing the *Salmonella* infection to establish and persist.

Goat disease surveillance dashboard outputs

The most frequent diagnoses from goat submissions made in Q4 of 2025, compared to Q4 in 2024, and Q4 for 2016 to 2025 inclusive, through the Great Britain (England, Wales, and Scotland) scanning surveillance network, are illustrated in Table 1. These can be interrogated further using the interactive small ruminant [disease surveillance dashboard](#) which was launched in October 2017.

Table 1: Great Britain scanning surveillance five most frequent goat submission diagnoses in quarter 4 (Q4) of 2025, Q4 of 2024 and Q4 for 2016 to 2025

	5 most frequent diagnoses Q4 2025	5 most frequent diagnoses Q4 2024	5 most frequent diagnoses Q4 2015 to 2025
1	Parasitic gastroenteritis (PGE)	Parasitic gastroenteritis (PGE)	Parasitic gastroenteritis (PGE)
2	Johne's disease	Johne's disease	Johne's disease
3	<i>Clostridium perfringens</i> type D disease	PGE due to Haemonchosis	<i>Clostridium perfringens</i> type D disease
4	Coccidiosis	<i>Clostridium perfringens</i> type D disease	Coccidiosis
5	PGE due to Haemonchosis	Coccidiosis	PGE due to Haemonchosis

Parasitic gastroenteritis (PGE) excludes PGE due to Haemonchus and PGE due to Nematodirus.

Sheep disease surveillance dashboard outputs

The most frequent diagnoses from sheep submissions made in Q4 of 2025, compared to Q4 in 2024, and Q4 for 2016 to 2025 inclusive, through the Great Britain (England, Wales, and Scotland) scanning surveillance network, are illustrated in Table 2. These can be interrogated further using the interactive small ruminant [disease surveillance dashboard](#) which was launched in October 2017.

Table 2: Great Britain scanning surveillance 10 most frequent sheep submission diagnoses in Q4 of 2025, Q4 of 2024, and Q4 for 2016 to 2025

	10 most frequent diagnoses Q4 2025	10 most frequent diagnoses Q4 2024	10 most frequent diagnoses Q4 2016 to 2025
1	Parasitic gastroenteritis (PGE)	Parasitic gastroenteritis (PGE)	Parasitic gastroenteritis (PGE)
2	Hyposelenaemia	Hyposelenaemia	Hyposelenaemia
3	Systemic pasteurellosis	Systemic pasteurellosis	Systemic pasteurellosis
4	Pine or cobalt deficiency	Pneumonia due to M. haemolytica	Pine or cobalt deficiency
5	Pneumonia due to M. haemolytica	PGE due to Haemonchus	Pneumonia due to M. haemolytica
6	Pneumonia due to other causes	Chronic fascioliasis	Chronic fascioliasis
7	PGE due to Haemonchus	Pneumonia due to other causes	Pneumonia due to other causes
8	Pneumonia due to mycoplasma	OPA (Jaagsiekte)	Johne's Disease
9	Poisoning due to oak or acorn	Pneumonia due to mycoplasma	Sheep Scab

10	Tickborne fever	Pine or cobalt deficiency	OPA (Jaagsiekte)
----	------------------------	---------------------------	------------------

Parasitic gastroenteritis (PGE) excludes PGE due to Haemonchus and PGE due to Nematodirus.

Pneumonia due to other causes included abscessation and other bacteria not specifically described.

Changes in disease patterns and risk factors

Syndromic analysis for sheep

Syndromic alerts were raised this quarter, in comparison to the quarter average of the previous 5 years for England and Wales, for the following diseases:

Increases

- Abomasitis not otherwise specified
- Bibersteinia trehalosi septicaemia
- Endocarditis not otherwise specified
- Footrot caused by Dichelobacter
- Hyposelenaemia or hyposelenosis
- Pine or cobalt deficiency
- Poisoning caused by oak or acorn
- Tick-borne fever

Decreases

- Drenching gun or bolus injuries
- Fetopathy due to Campylobacter

Parasitology

GOATS

Parasitic gastroenteritis (PGE), coccidiosis and haemonchosis were in the top 5 VIDA diagnoses in quarter 4 for goats. One case of chronic fascioliasis was detected in Argyll and Bute (Scotland).

A PGE case in an adult billy pygmy goat submitted for postmortem examination; with a history of per-acute scour, hypothermia, recumbency, and death; is a typical example. The animal was in poor condition with limited carcass fat reserves and gelatinous coronary fat. Parasitology testing revealed a Trichostrongyle-type worm egg count of 800 eggs per

gram (epg) and histopathological findings supported a diagnosis of parasitic gastroenteritis. Other bacterial causes of scour (*Listeria*, *Yersinia* and *Salmonella*) were ruled out on bacterial culture.

Given the unvaccinated status and peracute nature of disease development, clostridial enterotoxaemia was high on the differential diagnosis list but laboratory testing did not confirm this diagnosis. Epsilon toxin is labile, which can limit detection, and equally histopathological brain changes in acute cases do not often have time to develop. Therefore, clostridial enterotoxaemia could not definitively be ruled out, and consideration of vaccination of the remaining goats was advised.

SHEEP

Parasitic gastroenteritis

Parasitic gastroenteritis (PGE) remains the most common recorded VIDA diagnoses for sheep, accounting for 23% of all the VIDA diagnoses in quarter 4 in 2025, and this has been a consistent trend over the past few years, as shown in figure 2.

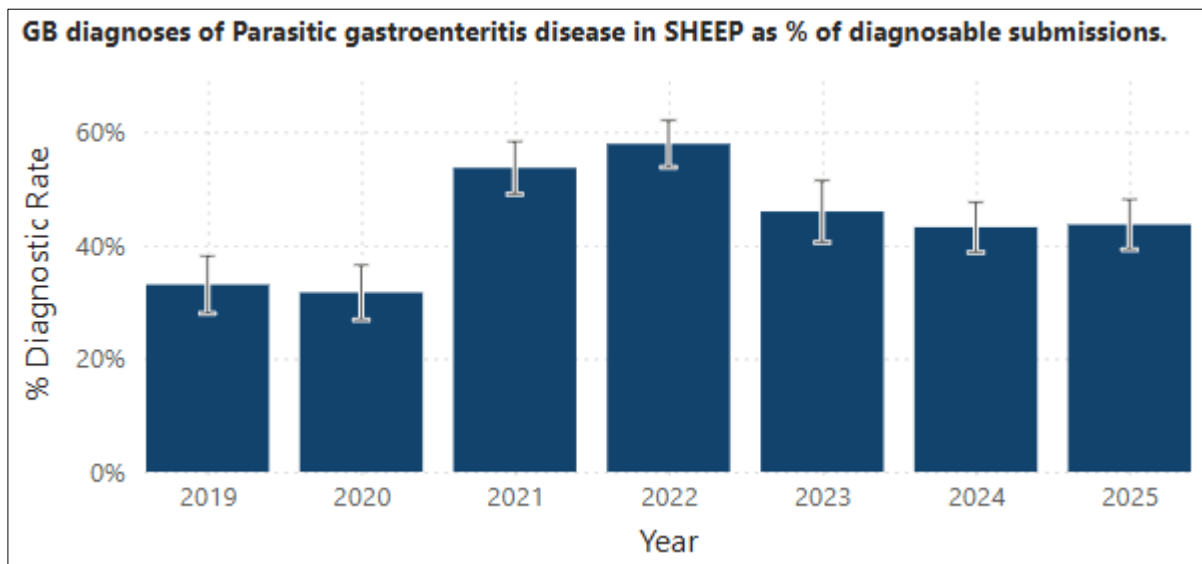


Figure 2: GB diagnoses in Q4 of Parasitic gastroenteritis in sheep as a percentage of diagnosable submissions, showing consistently high levels over the past few years. The error bars indicate a 95% confidence interval.

Mixed species PGE and concurrent conditions in lambs

Mixed worm burdens in combination with concurrent conditions were commonly diagnosed in this quarter. The case discussed below of a lamb submitted to Carmarthen VIC in October is a typical example.

A 6-month-old lamb was submitted to investigate the cause of ill-thrift, sunken eyes, diarrhoea, and death. Approximately 10% of the 1400 lamb crop had developed ill-thrift, with around 20-30 deaths over the previous month. The last worming treatment had been

a combination product of moxidectin and triclabendazole given 4-5 weeks prior to submission.

At PME, the lamb was in poor body condition, with dehydration and severe diarrhoea. PGE was confirmed by a Trichostrongyle-type egg count of 550epg, indicating a moderate infestation. The estimated total worm count demonstrated a mixed species infection, with a very high number of immatures indicating pasture contamination and an ongoing risk of reinfection. The count comprised 5,300 *Trichostrongylus axei*, 6,700 *Teladorsagia* spp., 22,400 immatures from the abomasum and 13,700 *Trichostrongylus* spp. and 6,600 immatures from the small intestine.

Urgent repeat anthelmintic treatment of the remaining at-risks lambs was advised, as well as testing the efficacy of subsequent anthelmintic treatment, more information on this is available at [How to Test | SCOPS](#).

Grossly this lamb also had mild to moderate pneumonia, likely to be secondary to debilitation due to PGE. *Mannheimia haemolytica* was isolated from lung. Liver cobalt and selenium concentrations were both in the deficient range. Blood sampling a few representative lambs from the cohort was recommended to further investigate.

SRUC reported that PGE in combination with trace element deficiency was a frequent diagnosis during Q4. A typical case involved a mob of 400 mixed mule and Scottish blackface (SBF) lambs which had been split into two equal groups and moved to a dairy farm for wintering. Rapid condition loss was noted towards the end of the first month, with more mules than SBF lambs affected. A mule lamb became recumbent and died 48 hours later. The carcass weighed 16 kg and was in poor body condition, with faecal soiling of the fleece. Faeces were soft rather than diarrhoeic, and the egg count of 10,500 strongyle eggs per gram (epg) plus 550 *Nematodirus battus* epg confirmed parasitic gastroenteritis. Liver selenium and cobalt results were very low at 0.175 mg/kg dry matter (DM) (reference range 0.9 – 3.5 mg/kg DM) and 0.039 mg/kg DM (reference range 0.08 – 0.35 mg/kg DM) respectively. Anthelmintic treatment and trace element supplementation was advised. The lambs had been treated with levamisole prior to being moved, but the exact date of treatment was unknown. An efficacy check was recommended.

Heavy mixed species PGE causing ill-thrift and deaths of adult ewes

A Speckled Mule ewe was submitted for postmortem examination to Penrith to investigate ill-thrift and deaths in a group of 200, 3-year-old ewes, in a 1200 ewe flock. Around 10-12 had died over the previous few weeks. They had had two lamb crops which had done well until weaning time, when ill-thrift persisted despite weaning the lambs, worm and fluke treatments, trace element boluses, and an iodine injection. A few individuals had had diarrhoea. Forty of the worst ewes had been housed and fed to increase body condition but failed to show any improvement. The submitted ewe was in a significantly poor body condition, with marked faecal soiling of the hindquarters. Many live lungworms were present in the trachea and bronchial tree, consistent in morphology with *Dictyocaulus* sp. worms. High numbers of lungworm can contribute to ill-thrift and predispose sheep to a secondary bacterial pneumonia. Around 50% of the left lung was consolidated, and heavy growths of *Mannheimia haemolytica* were isolated. Large intestinal contents had a

Trichostrongyle-type worm egg count of 10,650 eggs per gram, and worm washes identified abomasal worm counts of 8,000 *T. axei*, 31,000 *Teladorsagia* spp., 39,000 immatures, and from the small intestinal 60,000 *Cooperia* spp., 500 *Nematodirus battus*, 60,500 *Trichostrongylus* spp. and 3,500 immatures indicating a fatal worm burden in this ewe.

Generally, ewes in good health, that are well fed without pasture overstocking, and aren't exposed to heavily worm contaminated pastures, are relatively resilient to worms due to past exposure-derived immunity. However, issues attributed to one or several of these factors, or due to a lack of prior adequate immunity, can lead to disease in either a few individuals, or groups of adult sheep. Recovery from chronic endoparasitism-induced gastrointestinal inflammation requires removal from ongoing high worm exposure and good feeding, however affected sheep can take weeks to months to fully recover.

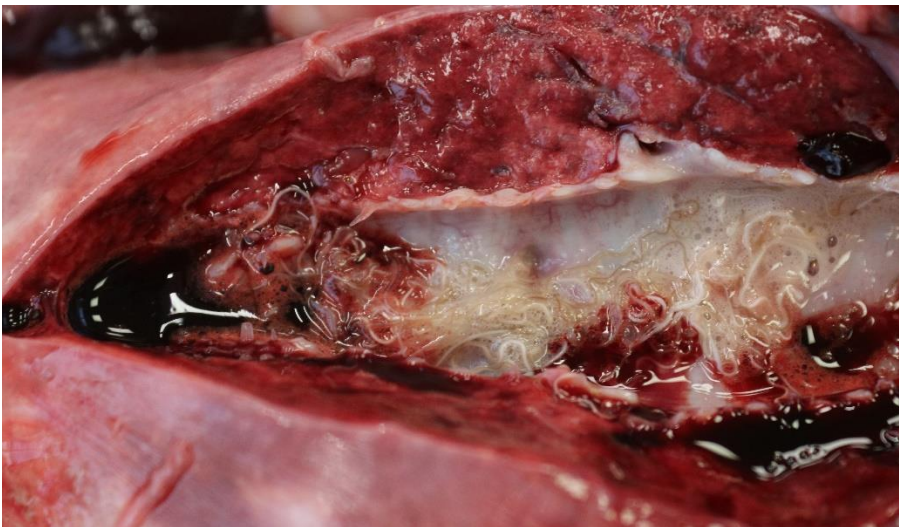

Figure 3: Large numbers of *Dictyoacaulus* sp. lung worm in the bronchus of a ewe with mixed species PGE

PGE and macrocyclic lactone resistance in lambs

Two 6-7-month-old lambs were submitted to Carmarthen VIC to investigate the cause of scouring and death. Out of the group of 100, approximately 40-50 had dirty hindquarters, and four had been found dead on the morning of submission. The lambs had been wormed with injectable ivermectin nine days prior to the submission.

Testing confirmed a fatal mixed worm burden in these lambs. Extremely high counts of immature worms indicated heavy pasture contamination and an ongoing risk of reinfection.

Bacteriology was suggestive of terminal colisepticaemia in Lamb 2, likely due to the loss of intestinal integrity.

Given the history provided, of ivermectin treatment having been given nine days previously, and the extremely high counts of worms remaining, concern was raised over a lack of anthelmintic efficacy. It was advised to discuss and review exact treatment dates, dosage given, route of administration, and calibration of equipment; and that all cases of

suspected lack of efficacy should be reported to the Marketing Authorisation Holder (MAH).

As there were a high number of lambs affected by diarrhoea and further deaths had occurred, urgent repeat anthelmintic treatment of the remaining at risks lambs was advised, with a product from an alternative wormer group.

Parasitic gastroenteritis (PGE) and *Listeria ivanovii* infection in weaned lambs

Shrewsbury VIC diagnosed PGE and *Listeria ivanovii* infection in weaned lambs at grass on two occasions.

The PME's revealed prominent mesenteric lymph nodes and significant worm burdens, consistent with parasitic gastroenteritis causing diarrhoea and deaths.

Listeria ivanovii was isolated in light pure growths from the enlarged livers with miliary white foci, and was likely to represent an ascending opportunistic infection of the liver following intestinal overgrowth, occurring secondary to worm induced inflammation

A series of APHA *Listeria ivanovii* cases was described in the Veterinary Record article referenced below. Interestingly during a review of these cases, it was suggested that *Listeria ivanovii* infection was more often diagnosed in a year where drought is followed by a wet late summer or autumn, as in 2025.

Reference

Dunnett, E., Florea, L., Thurston, L., Floyd, T., Collins, R. and Otter, A. (2020), Deaths of weaned lambs with visceral *Listeria ivanovii* infections. Vet Rec Case Rep, 8: e001254. <https://doi.org/10.1136/vetreccr-2020-001254>

Haemonchus

Haemonchus cases have declined from the high levels in quarter 4 in the previous 3 years, as shown in figure 3.

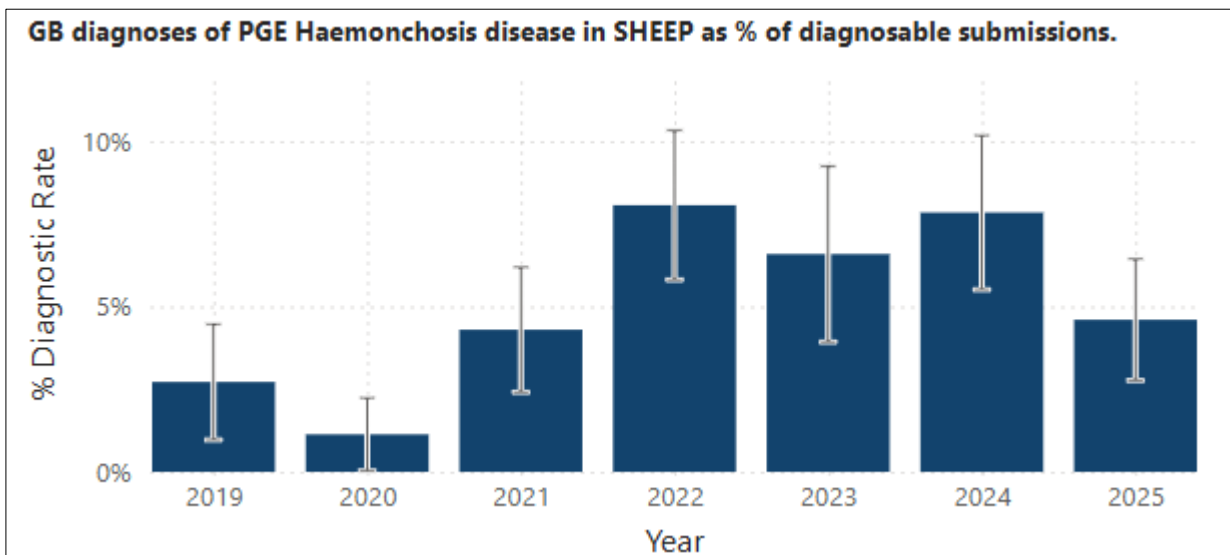


Figure 3: GB diagnoses in Q4 of PGE due to Haemonchosis in sheep as a percentage of diagnosable submissions, showing a decline this year compared to the previous 3 years. The error bars indicate a 95% confidence interval.

The following two cases are typical examples of haemonchosis cases where samples were submitted for *Haemonchus* sp. peanut agglutination differential egg staining.

Faeces were received from five-month-old rare-breed weaned lambs, to investigate the cause of poor body condition and diarrhoea, where all seven lambs were affected. The submitted faecal sample had a Trichostrongyle-type count of 4,320 eggs per gram, 98% of the eggs were identified as *Haemonchus*, suggesting *Haemonchus* worms were significantly involved.

Five rams had died over the summer, out of a group of 15, in a flock of 780 lowland sheep. An on-farm postmortem examination of a dead ram identified visible worms in the abomasum, and there was a faecal worm egg count of 15,000 Trichostrongyle-type eggs per gram. Peanut agglutination testing confirmed 88% of these eggs were *Haemonchus*, suggesting haemonchosis was the cause of death.

Fluke

There were no confirmed cases of acute fasciolosis in England or Wales, and two recorded cases in Scotland in quarter 4 this year, continuing the low trend seen over the previous few years, with acquisition of infections occurring later in the season. The very dry conditions earlier in the year will have played a significant part, by reducing the habitat of the intermediary host.

SRUC reported an investigation into poor lambing percentage, and loss of ewe condition between scanning and lambing in a flock, which was in part due to chronic fasciolosis. Only tupes were purchased. Four leaner Texel cross cull ewes were submitted for postmortem investigation, which revealed significant liver damage and biliary fibrosis due to chronic fasciolosis in all cases, with adult *Fasciola hepatica* present in three. The ewes

had been treated with a combination triclabendazole and ivermectin product three weeks prior to submission. Strongyle egg counts of 100 to 700 eggs per gram (epg) were also detected, and re-infection could have contributed to these. Further testing to assess triclabendazole and ivermectin efficacy was advised. Liver trace element analysis showed low copper status in three, with results of 265, 227 and 101 micromole per kilogram dry matter (umol/kg DM) (reference range 314-7850 umol/kg DM). This was unexpected in Texel cross ewes and the possibility of this being a consequence of liver damage was considered.

Systemic disease

Systemic listeriosis infections in ewes

The carcass of a heavily pregnant Dorset Horn ewe was submitted to Starcross VIC from a small flock of 18 breeding ewes with a history of malaise and seizure episodes. Although the PME was compromised by autolysis, multifocal 1-2mm diameter firm pale foci were scattered throughout the lung tissue, suspicious of a systemic listeriosis infection. Bacteriology confirmed this diagnosis, with the isolation of *Listeria monocytogenes* from the brain, liver, and lung. It was suspected that the immunosuppression of late pregnancy was a contributing factor to disease development.

Carmarthen VIC received an adult ewe to investigate three deaths over one week. The ewe was found dead; the others were seen to be recumbent before dying. They were vaccinated against clostridial diseases and pasteurellosis and had been recently treated for worms. They had been grazing with access to silage and mineral blocks. At PME, the ewe had diarrhoea and gross findings were suggestive of parasitic gastroenteritis, however a faecal worm egg count was low. The spleen was enlarged and there were irregular pale foci up to 2cm diameter throughout the liver. The enlarged spleen raised suspicion of tick-borne fever (TBF) however testing for this was negative. Bacteriology confirmed systemic listeriosis with *Listeria monocytogenes* cultured in pure growth from liver, lung and spleen. *Salmonella enterica* subspecies *diarizonae* was cultured from faeces on enrichment. This is a host adapted salmonella specifically to sheep. It can be found in the intestines, tonsils and upper respiratory tract of healthy carrier animals, as well as in sheep with salmonellosis. It was unlikely to be of any clinical significance in this case.

Listeria monocytogenes can be found widely in the environment and particularly in poorly preserved and/or soil contaminated silage. Excess soil ingestion due to poor grazing is also a risk factor. A review of the diet of the remaining flock was recommended in both cases.

***Bibersteinia trehalosi* septicaemia**

Bibersteinia trehalosi septicaemia has had a steady increase in the number of incidents diagnosed in Q4, since 2020, as shown in figure 4. A total of 64 were diagnosed in Q4, 2025 for GB, compared to 10 in Q4, 2020.

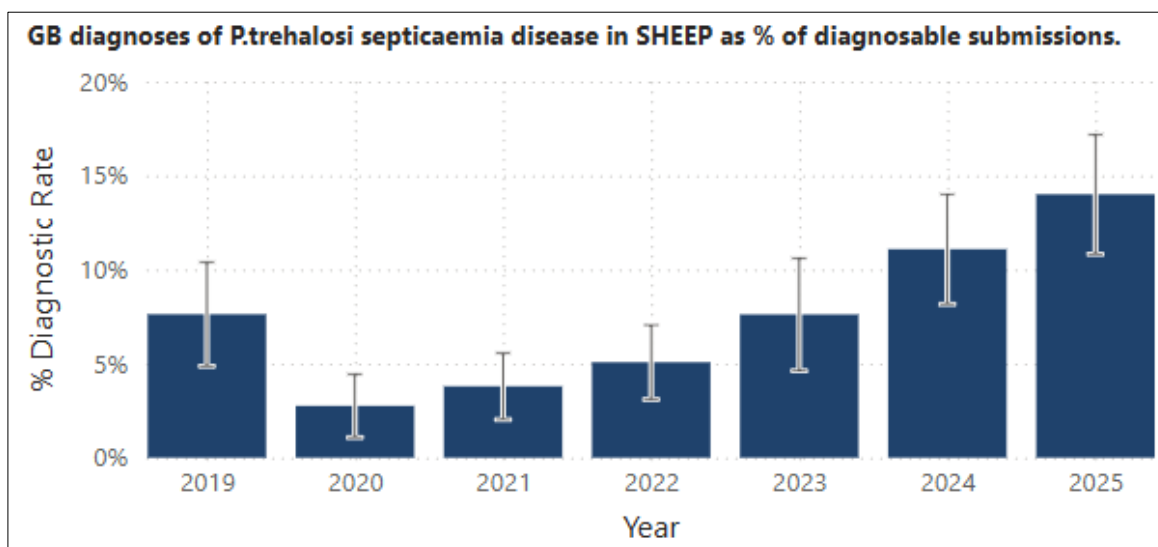


Figure 4: GB diagnoses in Q4 of *Bibersteinia trehalosi* septicaemia in sheep as a percentage of diagnosable submissions, showing a steady increase from 2020. The error bars indicate a 95% confidence interval.

Bibersteinia trehalosi is a sporadic cause of septicemia in sheep, and post weaned lambs are particularly susceptible. The organism resides in the tonsils and nasopharynx of apparently healthy animals but can progress to pneumonia or a systemic infection, following a variety of potential triggers. Various risk factors have been linked to outbreaks of Bibersteiniosis: stress from adverse weather, handling, or transport; or a diet change to richer feed, occurring within the preceding two-week period; or concurrent disease issues such as parasitic gastroenteritis, tick-borne fever, or trace element deficiencies. Throat abrasions following drenching or bolus administration may potentially further increase the risk of bacterial invasion and septicaemia. There are what are considered “bad years” for Bibersteiniosis, possibly due to changeable weather conditions, or due to elevated concurrent disease issues. Although a vaccine is available, the protection provided against *Bibersteinia* is incomplete, meaning vaccination reduces rather than prevents cases and deaths.

The *Bibersteinia trehalosi* septicaemia cases in sheep during 2025 presented with clinical signs such as mucoid nasal discharge, respiratory signs, malaise, or were sudden deaths. Mortality rates ranged from 1.5 to 8% in the affected groups at the time of submission (3-31 deaths), occurring in groups of between 70 and 900 sheep. In 64% of cases, a concurrent disease or combinations of disease issues were identified. In 40% of cases, parasitic gastroenteritis was also diagnosed; and in 18% of cases there was a trace element deficiency, most commonly selenium deficiency, but in some cases a cobalt deficiency was found. In 9% of cases a concurrent tick-borne fever (*Anaplasma*

phagocytophilum) infection was potentially contributing to disease risk through immunosuppression. An additional concurrent bacterial infection was found in 24% of cases, this was most often *Mannheimia* as either a septicaemia or pneumonia, but also there were cases of Listeriosis, *Staphylococcus aureus*, and Yersiniosis.

Although the pathology identified during postmortem examination of *Bibersteinia* septicaemia cases can vary, the following were recorded:

- Dark purple mucous membranes
- Widespread subcutaneous and/or muscular petechial haemorrhages, particularly over the ventral neck and thoracic wall
- Swollen liver, in some cases with multifocal miliary (<1mm diameter) white lesions throughout the liver parenchyma
- Excess yellow abdominal fluid
- Ulceration of the pharynx, larynx and/or oesophagus, discrete punctate, or in some cases linear oesophageal ulcers.
- Dark red or purple mottled and potentially oedematous lungs or lung consolidation; multiple haemorrhages throughout the lungs (petechial or coalescing ecchymotic), ecchymotic haemorrhages over the thoracic parietal pleura and in some cases fibrin in the pleural cavity
- Petechial haemorrhages on the serosal surface of abdominal organs
- Green liquid, haemorrhagic, or brown abomasal and intestinal contents, and diarrhoea
- Typhlitis is found in a small number of cases
- Clear pericardial fluid with some fibrin
- Reddened to dark purple enlarged lymph nodes, generalised lymphadenopathy.

Ulcerative pharyngeal and/or oesophageal lesions are commonly seen in Bibersteiniosis cases and are considered a strong indicator of this infection. Ulcerative lesions in the gastric and intestinal tissues, however, is far less common and may require specific co-factors before this presentation is seen. Two cases were described this quarter:

Bibersteinia trehalosi was isolated from diffuse gastrointestinal lesions in a post weaned lamb, with a concurrent parasitic gastroenteritis, received at APHA Shrewsbury for postmortem examination. Three dead unvaccinated homebred replacement ewe lambs were submitted after five had been found dead within a 24-hour period, in a group of 400. The lambs had been on new ley grazing, and had been dipped three days earlier, with a wormer given two days before submission. All three lambs had a severe watery diarrhoea, with a haemorrhagic abomasitis, marked mucosal thickening in the large intestine, and in one lamb, small intestinal and caecal ulceration (Figures 5 -7). *Salmonella*, *Yersinia* and *Listeria* cultures were all negative. *Bibersteinia* septicaemia was confirmed in the lamb with ulcerative enteritis; the lower gastroenteric lesions representing a more unusual presentation of Bibersteiniosis, most likely representing an opportunistic infection of parasite damaged abomasal and intestinal tissues, resulting in a bacterial gastroenteritis and septicaemia.

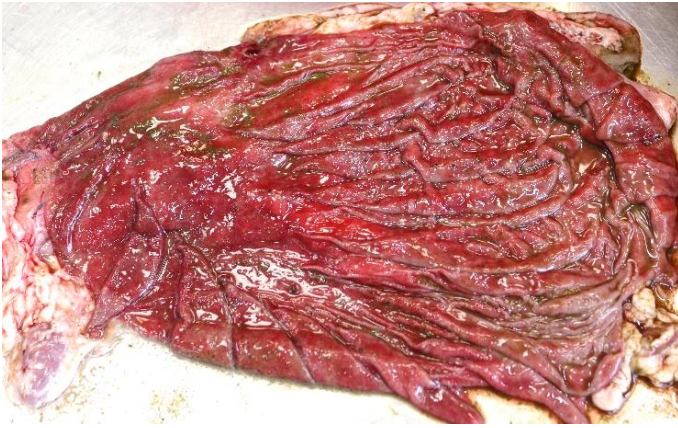

Figure 5: Ulcerative abomasitis in a weaned lamb with PGE and Bibersteiniosis.

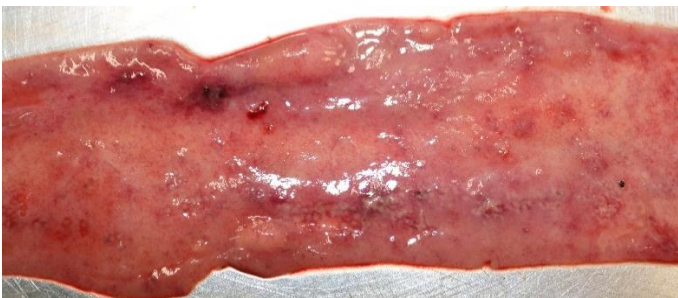

Figure 6: Ulcerative small intestinal lesions in a weaned lamb with Bibersteiniosis.

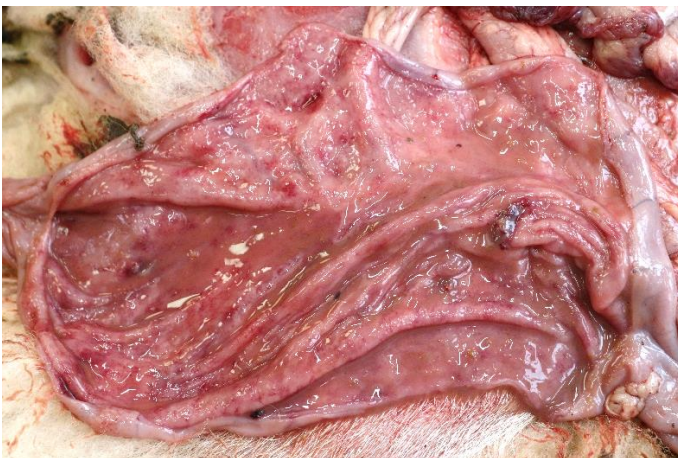

Figure 7: Ulcerative caecal ulcers in a weaned lamb with Bibersteiniosis.

Pine or cobalt deficiency

There was a significant increase in cobalt deficiency for Q4 in 2025, compared to the equivalent quarter in 2023, as shown in figure 8. A total of 61 incidents were diagnosed in Q4 2025, compared to 26 in Q4 2024.

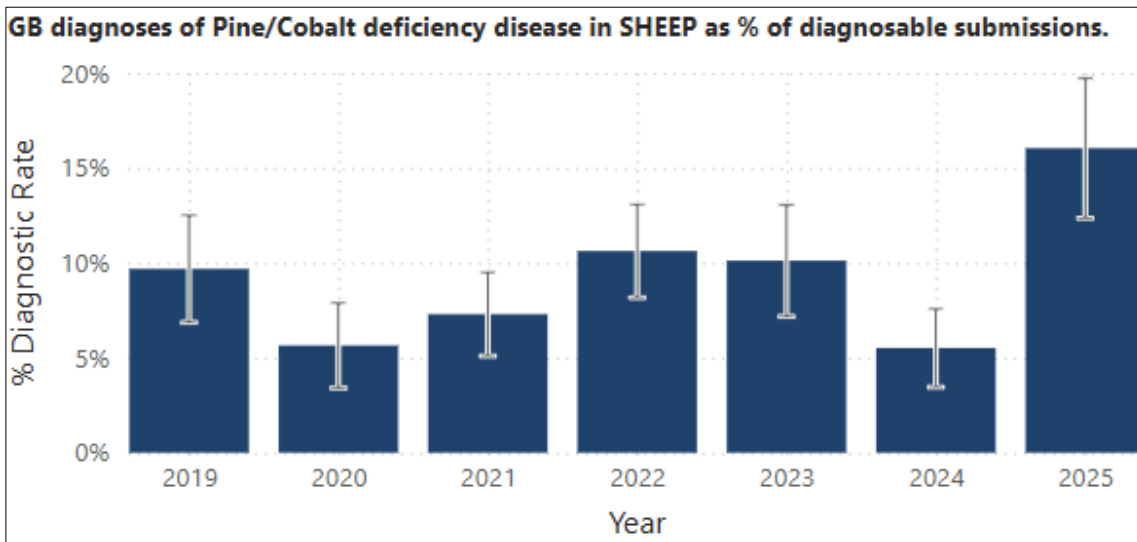


Figure 8: GB diagnoses in Q4 of pine or cobalt deficiency in sheep as a percentage of diagnosable submissions, showing a steady increase from 2020. The error bars indicate a 95% confidence interval.

A 7-month-old lamb was submitted to Carmarthen VIC for euthanasia and PME, to investigate around six out of 70 weaned lambs which had died over a one-week period in November, and an additional 15 animals which were unwell; systemic pasteurellosis had been suspected as a possible cause of mortality. The group had been treated with a combination of moxidectin and triclabendazole three weeks prior to submission and received a vitamin drench. The lambs were not vaccinated.

On clinical examination, the lamb was unable to stand unaided due to generalised weakness and, was pale. PME found the lamb to be emaciated. There was generalised pallor to subcutaneous tissues. The liver was extremely friable, and ketones were detected in urine. The retropharyngeal and pre-scapular lymph nodes were enlarged. The spleen was enlarged. Two circular 1cm diameter areas of dark discolouration with a cream centre were present bilaterally on the lateral aspect of the caudal tongue.

Very low selenium and cobalt levels of 0.396 mg/kg DM (reference range 0.9 – 3.5) and <0.012 mg/kg DM (reference range: > 0.06) and) respectively, were detected in liver tissue. Interpretation in an unwell and emaciated animal is complicated, especially given evidence of concurrent parasitic gastroenteritis, a primary deficiency was nonetheless suspected.

Histopathology of the liver provided supportive evidence for Ovine White Liver Syndrome, which is a consequence of severe cobalt deficiency, and can present as neurological signs. Necrotising bacterial infection of the tongue lesions was demonstrated by histopathology.

Intestinal disease

Yersiniosis in a goat

An 18-month-old Toggenburg goat was euthanised and submitted for postmortem examination after becoming recumbent and moribund. Gross postmortem examination showed evidence of diarrhoea with multifocal, raised, yellow lesions along the jejunal and caecal mucosa, and pale, irregular flat lesions along the ileal mucosa. Faecal parasitology did not identify a worm burden and the coccidial oocyst count was relatively low at 900 opg. Speciation of the oocysts revealed that 78% of them belonged to pathogenic species, mainly *E. arloingi*, which can cause nodular lesions in the mucosa.

Culture of the intestinal content yielded a heavy growth of *Yersinia pseudotuberculosis* and histopathological examination of the tissue showed changes consistent with Yersiniosis. The nodular lesions seen grossly were likely the result of this enteric bacterial infection, although autolysis prevented ruling out coccidiosis as a potential underlying cause for the Yersiniosis.

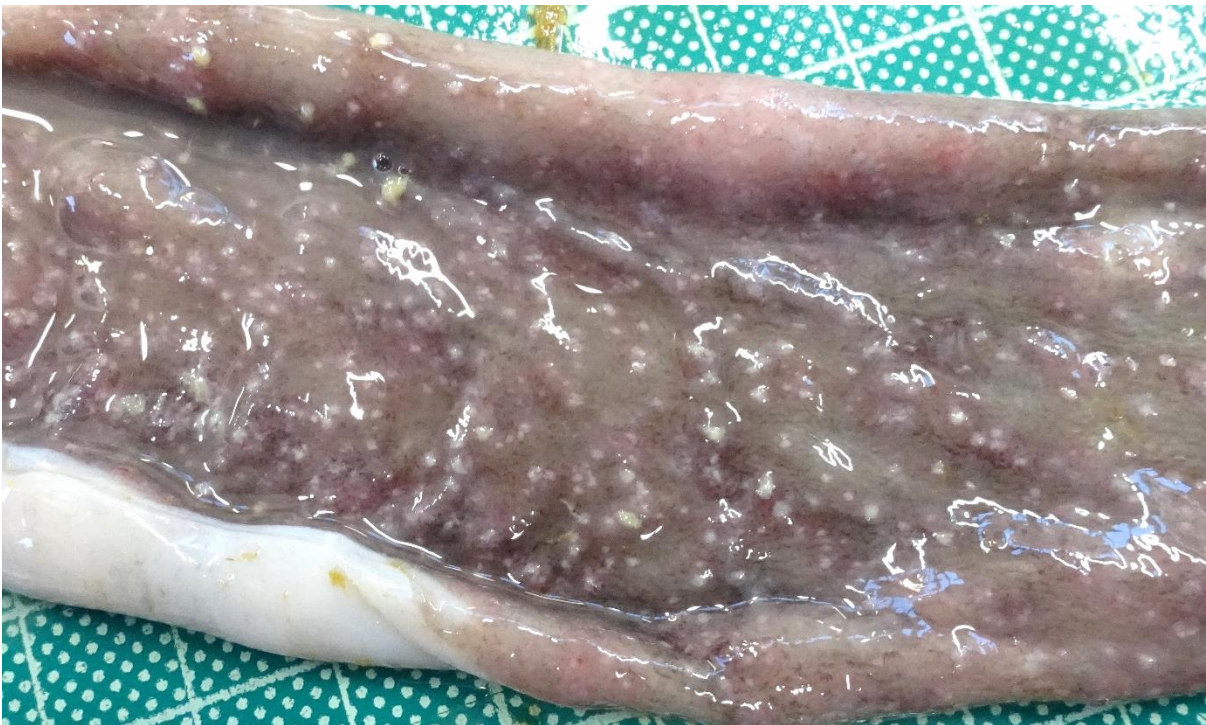


Figure 9: Nodular white intestinal lesions in a goat with Yersiniosis. Histopathological evidence supported bacterial invasion, but coccidiosis could not be ruled out and *E. arloingi* can cause similar lesions.

Respiratory disease

***Histophilus somni* pneumonia and septicaemia in a 7-month-old fattener lamb**

Histophilus somni was isolated in moderate to very heavy growths from the lung and liver of a 7-month-old lamb, one of two lambs submitted to APHA Carmarthen for postmortem examination to investigate the cause of 10 sudden deaths over a 12-day period. Lambs were being purchased in batches from local livestock markets, multi-source mixed and housed, and were being fed on silage and ad-lib concentrates. There had been signs of

pneumonia and coughing in this shed of 900 lambs. Acidosis was confirmed in both lambs (pH of 4 and 4.6), and the lambs also had signs consistent with pneumonia and systemic infection. Both lambs tested positive for *Mycoplasma ovipneumoniae*, and *Mannheimia pneumonia* was confirmed in one of the lambs. *Histophilus somni* septicaemia identified in the other lamb, however, was a particularly unusual finding, potentially occurring because of multi-source mixing, and the challenge of multiple extreme stressors such as a marked dietary change and acidosis, a high stocking density, and concurrent parasitic gastroenteritis.

Circulatory disease

Tick-borne fever cases recorded for APHA have increased from 8 in Q4 2024 to 17 in Q4 2025. Analysing figures over the past five years reveals peaks in May and again September and October, but cases are confirmed throughout the year as shown in figure 10. This is an important consideration, as this condition can contribute to outbreaks of several other endemic diseases, due to its immunosuppressive effect.

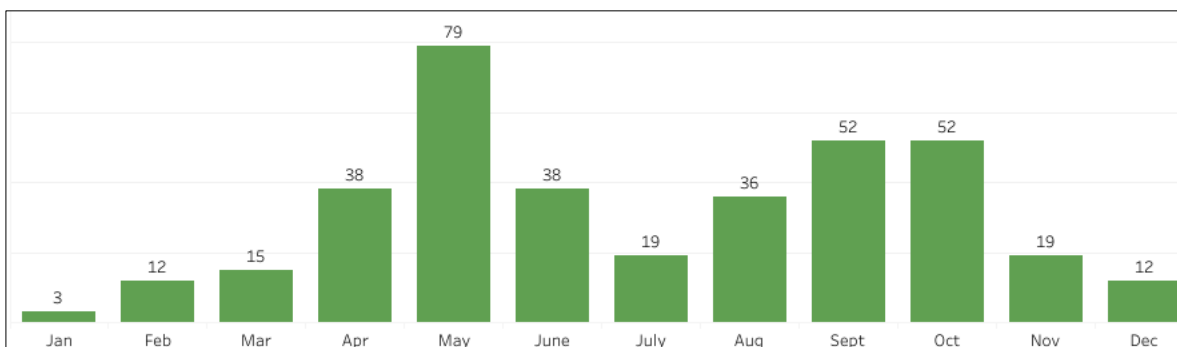


Figure 10: Seasonal distribution of tick-borne fever cases confirmed in GB over the past 5 years

[Tickborne diseases of sheep](#) and [Tick-borne disease story | Tableau Public](#) provide further information and analyses.

Musculo-skeletal

Spinal abscess in a three-week-old lamb

Staphylococcus aureus was diagnosed as the causative agent of a spinal abscess in a three-week-old lamb submitted for postmortem examination with a history of sudden onset hindlimb paralysis. As suspected clinically, a spinal abscess was seen grossly at the level of T9, T10, and T11 (Figure 11) causing localised compression of the spinal cord (Figure 12). In the absence of tail or castration rings, haematogenous spread from ear tagging lesions was thought possible in this case, and the isolation of *Staphylococcus aureus* from the abscess supported a cutaneous source of infection. Tick borne fever PCR testing gave a negative result ruling out tick pyaemia.

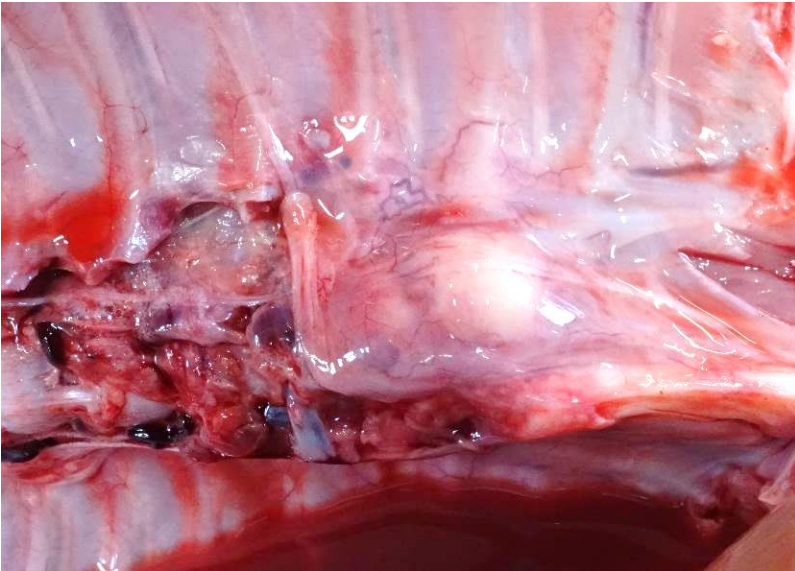

Figure 11: Visible bulge of the spinal column at the level of T9, T10, and T11 in a three-week-old lamb with a spinal abscess

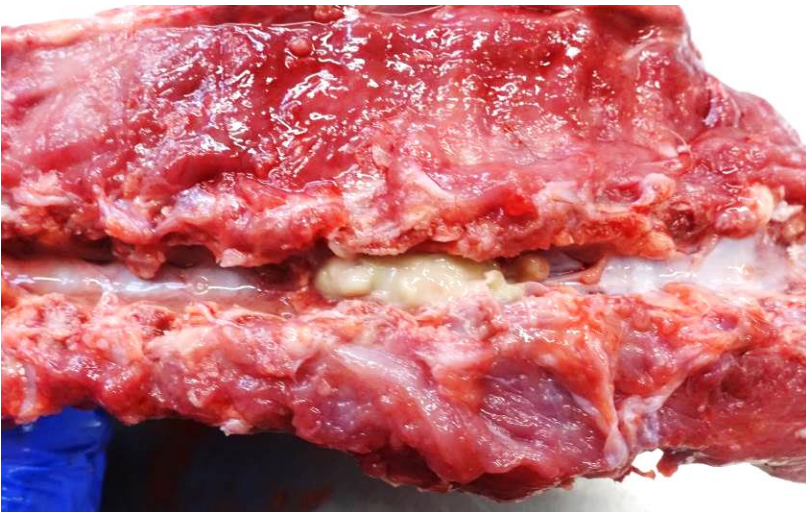

Figure 12: Purulent material within the spinal canal causing localised compression of the spinal cord in a three-week-old lamb with a spinal abscess

Urinary disease

No significant changes to trends. See acorn toxicity cases under Toxicity.

Nervous disease

Ovine Protozoal Meningoencephalitis (OPM)

Starcross VIC diagnosed two cases of ovine protozoal meningoencephalitis (OPM) in spring born lambs, by the histopathological findings of severe meningoencephalitis and the detection of protozoal meronts in one (Figure 13), and by suggestive histopathology and positive *Sarcocystis tenella* PCR in the other. One case had a history of hindlimb paresis before death and the other a flock history of nervous disease and 40 deaths. In the latter case tick borne fever was also detected in the submitted lamb, which might have contributed to the clinical picture, as more severe disease can be seen in sheep co-infected with *Anaplasma phagocytophilum*.

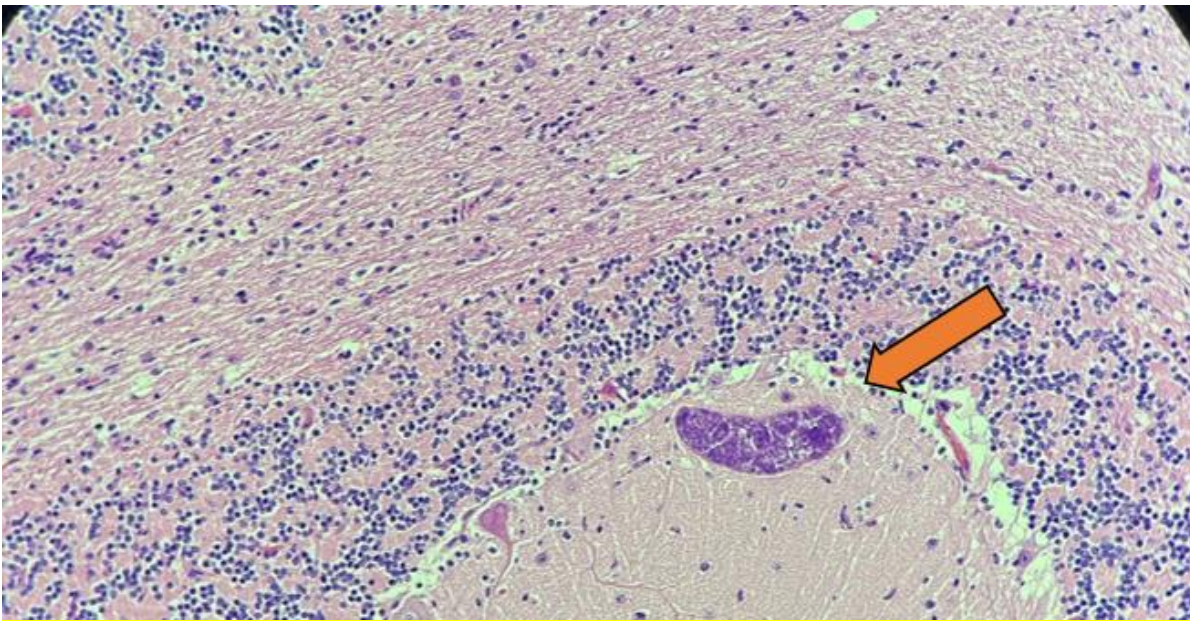


Figure 13: Protozoal meront (orange arrow) in the neuroparenchyma of a lamb with ovine protozoal meningoencephalitis (OPM)

OPM is typically seen in growing lambs with hindlimb paresis, paralysis and recumbency the main clinical presentations. As discussed in the Q1 report, there are several different recognised *Sarcocystis* species and *Sarcocystis tenella* is considered the most likely causative agent (Caldow and others, 2000). The precise aetiology of the condition is unclear, but it is suggested that husbandry factors are likely to affect the degree of exposure to infective stages of the parasite and lead to outbreaks of the condition, particularly the movement from a low level of exposure to a high level of exposure through contaminated pasture or forage. In OPM cases it is likely that affected animals are exposed to high levels of the parasite in contaminated faeces several months earlier in the grazing season, and that the weight of challenge initiates widespread infection extending into the nervous system. There are no specific disease control measures for OPM but, prompt disposal of casualty sheep carcasses and raw sheep offal, to prevent consumption by scavenging carnivores, will reduce opportunities for transmission of infection.

O'Toole, D., Jeffrey, M., Challoner, D., Maybey, R., & Welch, V. (1993). Ovine myeloencephalitis-leukomyelomalacia associated with a Sarcocystis-like protozoan. *Journal of veterinary diagnostic investigation: official publication of the American Association of Veterinary Laboratory Diagnosticians, Inc*, 5(2), 212–225.

Caldow, G. L., Gidlow, J. R., & Schock, A. (2000). Clinical, pathological and epidemiological findings in three outbreaks of ovine protozoan myeloencephalitis. *The Veterinary record*, 146(1), 7–10

Staphylococcus aureus meningitis

Following on from the cases of *Mannheimia haemolytica* meningitis seen in lambs in the last quarter, another less common cause of bacterial meningitis was diagnosed by Carmarthen VIC in Q4.

Progressive weakness and neurological signs were reported in the submitted six-month-old lamb. On postmortem examination a purulent meningitis was identified with purulent material noted over the right side of the ventral brainstem (Figure 14). *Staphylococcus aureus* was cultured in pure growth from the brain. Systemic *Staphylococcus aureus* infections, including meningitis, can be due to tick pyaemia, a secondary staphylococcal infection of lambs concurrently infected with the bacterium *Anaplasma phagocytophilum*, the agent of Tick-Borne Fever. Testing for *Anaplasma* in this case gave a negative result.

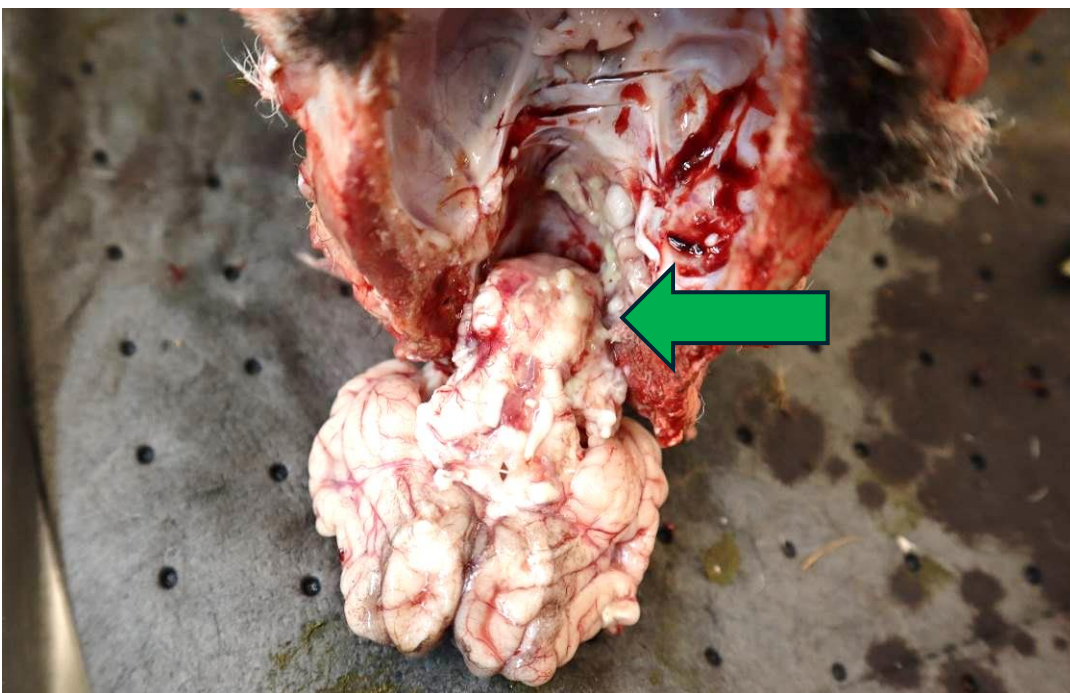


Figure 14: Purulent material (green arrow) over the ventral brainstem in a 6-month-old lamb with *Staphylococcus aureus* meningitis

Reproductive

No significant changes.

Skin

No significant changes.

Salmonellosis

Reports of [salmonella in livestock, dogs, birds and wildlife in Great Britain](#) can be found on GOV.UK.

Salmonella Typhimurium

A yearling ram, purchased one month previously, was submitted for post-mortem examination following a few days of malaise and diarrhoea culminating in death. The ram had been introduced to group of ewes 7-10 days previously, grazing a field on which slurry had been spread three weeks before that. Postmortem examination confirmed enteritis and a fully sensitive (sequence type 19) *Salmonella* Typhimurium was isolated from faeces. Salmonellosis due to *Salmonella* Typhimurium is often deemed an opportunistic infection in immunosuppressed animals. In this case, a concurrent high gastrointestinal worm burden was detected, along with infection with *Anaplasma phagocytophilum*, the causative agent of tick-borne fever. Additional external stressors were also reported, including recent purchase, group and management changes, and the onset of breeding activity.

Chemical food safety

[Chemical Food Safety Reports](#) can be found on GOV.UK.

Toxicity

Oak or acorn poisoning

Multiple cases of acorn toxicity in sheep continued throughout quarter 4 of 2025, including into December. In some incidents, significant losses were experienced. This highlights the ongoing risk posed by brown acorns to ruminants. A summary of the submissions to the APHA Veterinary Investigation Centres is given in Table 3..

Acorns and other parts of the oak tree contain toxins including tannins and phenols which cause renal failure, with the uraemia leading to mucosal lesions. Toxin levels are highest in green acorns and young leaves, which may also be more palatable; however, brown acorns can still cause toxicity if eaten in high enough quantities. Clinical signs can include anorexia, depression, polydipsia and polyuria, haematuria, icterus and constipation followed by diarrhoea which may appear black. In addition to acute deaths, surviving severely affected animals may show continued ill thrift, and euthanasia should be considered on welfare grounds. Access to large numbers of acorns and fallen oak leaves should be prevented if possible.

Table 3: Details of cases of oak or acorn toxicity submitted to APHA Veterinary Investigation Centres between September and December 2025.

VIC	Numbers affected	Clinical signs	Gross pathology	Laboratory testing	Concurrent disease
0	0	0	SEPTEMBER	0	0
Bury St Edmunds	5-10 weaned lambs affected, 6 died over one week	Malaise, lethargy and diarrhoea	Extensive perineal faecal staining and marked dehydration. Extensive ulceration, haemorrhage and necrosis of the oesophageal mucosa (figure 15).	Faecal worm egg count 1200epg Markedly elevated aqueous humour urea concentration 181.5mmol/l Bacteriology unrewarding	Significant parasitic burden
Shrewsbury	1 weaned lamb out of 50	Sudden death	Dry subcutaneous tissues, acidotic rumen pH of 4.9, large quantities of acorns and some plum stones in the rumen. Abomasum and intestines reddened, abomasum oedematous, haemorrhagic intestinal contents, enlarged spleen, haemorrhagic lungs.	N/A	Secondary <i>E.coli</i> bacteraemia with an associated hepatitis
Shrewsbury	1 shearling ram lamb out of 11 pedigree rams	Sudden death	Rumen pH 4.4 and full of pale-yellow fluid, short fibre, whole and broken cereal grains and a large quantity of chewed acorns	N/A	Ruminal acidosis resulting from combined acorn ingestion and a

			and several green oak leaves.		high cereal intake
Starcross	Adult ewe	Dull and quiet	Distinct uraemic smell, pale kidneys (figure 16), superficial necrosis of the upper oesophagus and larynx. Rumen contained large amounts of both whole acorns and acorn fragments.	Significantly elevated aqueous humour urea concentration	None
0	0	0	OCTOBER	0	0
Carmarthen	12 ewes died out of 600 over 2 weeks	Lethargic and acute diarrhoea	Pale and enlarged kidneys, haemorrhagic intestinal content.	Markedly elevated aqueous humour urea concentration	None
Carmarthen	3 ewes died two days after dipping	Weakness and depression, some ewes also had cloudy eyes	Acorns present in rumen, oesophageal ulceration, splenomegaly.	Uraemia Positive <i>Anaplasma phagocytophilum</i> PCR <i>Mycoplasma conjunctivae</i> cultured from an eye swab	Tick-borne fever Ovine infectious keratoconjunctivitis
Shrewsbury	3 shearling ewes died / 80 over 4 days from a 1000 head hill flock, plus other deaths in recent weeks	None recorded	Faecal soiling of the hindquarters, fine haemorrhages on surface of both kidneys (figure 14), white necrotic plaques in the oropharynx and proximal oesophagus, dark red ulcerated abomasal mucosa, rumen contents with a pH of 6.8 with visible fragments of acorns.	High aqueous humour urea concentration of 95.5mmol/l (ref range 0-30 mmol/l) Lung cultures OPA PCR - negative	<i>Staphylococcus aureus</i> isolated from lung
Starcross	10 ewes affected, 5 died	Lethargy, weakness and anorexia	Linear erosions in the tongue and a sour smell to the carcass. Acorns in the rumen and	Extremely high aqueous humour urea concentration	None

			haemorrhagic diarrhoea in the large intestine. Renal cortices covered in petechiae.	Other tests ruled out septicaemia and parasitic gastroenteritis	
0	0	0	NOVEMBER	0	0
Carmarthen	2 out of 10 recently purchased 'broken mouth' ewes wasting; 1 died, 1 euthanased	Wasting	Large number of acorn shells and chewed parts of acorn in the rumen, kidneys enlarged, oedematous and pale, diarrhoea.	High aqueous humour urea concentration of 73.5 mmol/l	Light worm burden
Shrewsbury	3 out of 160 purchased replacement ewes died. Quarantined on fields with access to woodland.	None recorded	Strong smell of ammonia, dry subcutaneous tissues, dark red lungs, bloody liquid intestinal and rectal contents, and pale kidney cortices. Multiple acorn fragments were present in the rumen.	Elevated aqueous humour urea concentration 113.2 mmol/l	None
Starcross	5 out of 220 ewes died deaths of 220	Malaise and recumbency prior to euthanasia	Dark coloured liquid intestinal content, and swollen, soft kidneys.	Urea levels markedly raised	None
0	0	0	DECEMBER	0	0
Carmarthen	55 out of 200 Welsh Hill cross lambs died. Broke into a woodland.	Lambs described as 'dazed', some in poor condition	All 3 lambs had a very strong smell of urea, extensive ulceration of the oesophagus, and large numbers of whole and digested acorns in the rumen. Extensive subcutaneous haemorrhage of the entire carcass of one lamb. Two lambs had large areas of haemorrhagic liquid/blood clots in the retropharyngeal space	Very high aqueous humour urea concentration in one lamb tested 177.2mmol/l <i>Anaplasma phagocytophilum</i> PCR negative	None

			surrounding one kidney. Two lambs had small, pale kidneys, in the other the kidneys were mottled and dark red.		
Carmarthen	30 ewes died. Field not grazed earlier in the autumn due to high numbers of acorns. As the acorns were now brown, it was decided to graze the field.	Malaise, weakness, altered consciousness. Dark black/green mucoid faeces.	Strong uraemic smell, ulceration of the alimentary tract mucosa, pale kidneys and large numbers of acorns in the rumen and reticulum.	N/A	None
Carmarthen	6 ewes died over 1 to 2 months	Black scours for one to two days before death.	Oesophageal mucosa dark purple with faint coalescing darker linear ulcers with grey/yellow sloughing of the mucosa. Mucosa of the caecum was dark purple, and content was a green haemorrhagic liquid. Large intestinal mucosa contained areas of ecchymotic haemorrhages, and the content was a dark green liquid. Many black acorn fragments were present in the rumen.	High aqueous humour urea concentration 112mmol/l	None

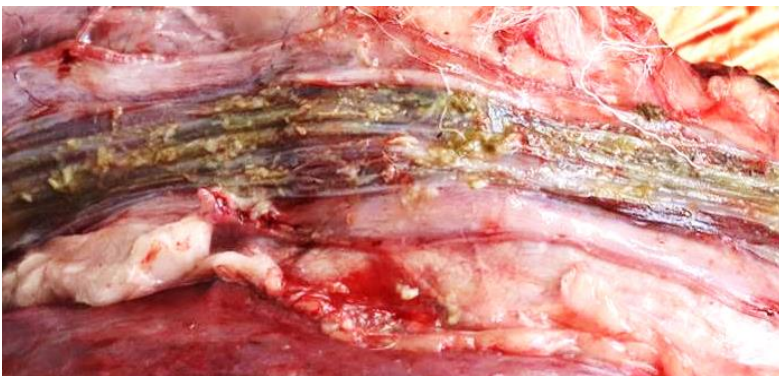

Figure 15: Ulceration of the oesophageal mucosa in a ewe with acorn poisoning.

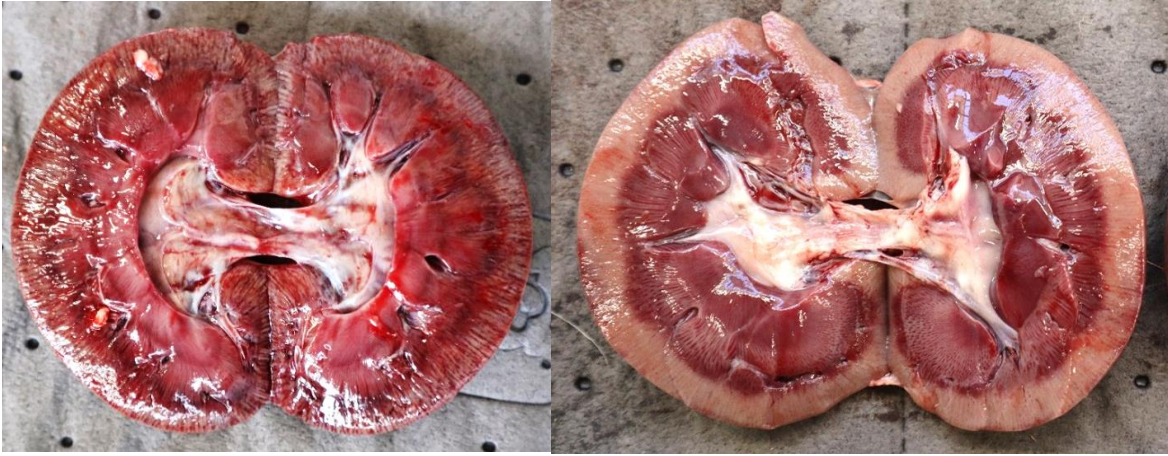

Figure 16: Kidneys of two ewes with acorn poisoning, demonstrating red striations in the cortex in the left image and pale cortices in the image on the right.

Antimicrobial use and resistance

The Veterinary Antibiotic Resistance Sales and Surveillance (UK-VARRS) Report 2024 has recently been published by the Veterinary Medicines Directorate (VMD): [Veterinary Antimicrobial Resistance and Sales Surveillance 2024 - GOV.UK](#)

[In addition, the latest RUMA Targets Task Force report can be found at: Latest RUMA Agriculture Targets Task Force report released – 18 November 2025 – RUMA](#)

The Medicine Hub, a voluntary industry initiative, developed and managed by AHDB, was launched in 2021 and provides a central location for the collection of medicine data, including antibiotic use: [Medicine Hub for dairy, beef and sheep farmers | AHDB](#)

Centre of Expertise for Extensively Managed Livestock (COEEML)

The COEEML was developed by APHA to address potential surveillance gaps for extensively managed animals. Extensive management of livestock potentially makes regular or close inspection for disease detection more challenging. The Centre is based at the APHA Veterinary Investigation Centre in Carmarthen; however, it is a Great Britain-wide resource and forms part of the wider veterinary surveillance system operated by APHA. For more details, see the [Animal disease scanning surveillance](#) pages on GOV.UK.

TSE

Surveillance for transmissible spongiform encephalopathies (TSEs) is conducted in the United Kingdom in animals susceptible to the disease. This includes cattle, sheep, and goats. The main aim is to monitor trends in disease incidence and prevalence, to evaluate the effectiveness of TSE disease controls.

There are two categories of surveillance – passive and active.

Passive surveillance

This is when an animal with clinical signs suspicious of BSE or scrapie is reported to an APHA Office to be investigated. Such cases are slaughtered, and the examination of the brain determines whether the animal was affected by a TSE.

APHA has been recording and analysing data from reported cases in cattle since the start of the BSE epidemic in 1986, and for scrapie in sheep and goats since this disease became notifiable in 1993.

Active surveillance

The UK carries out active surveillance for TSEs.

The UK has:

- tested cattle since July 2001
- tested sheep and goats since January 2002
- conducted a survey in 2007 and 2008 of farmed and wild deer

View the [updated TSE statistics](#) on GOV.UK.

Horizon scanning

International Disease Monitoring (IDM) horizon-scanning activities monitor for major, notifiable, or new and re-emerging animal disease outbreaks worldwide. This is done to provide an early warning and to assess the risks they may pose to the United Kingdom (UK), particularly for those diseases which impact on animal health and welfare, international trade, public health, or wider society. IDM also assess the risk that animal diseases might come into the UK through the trade in animals or animal products (legal or illegal), through movements of wildlife, or through the movement of fomites and vectors such as insects which may carry infectious disease. These outbreak assessments are used to guide decisions how to manage or reduce the risks and are published on the web: [Animal diseases: international and UK monitoring](#).

Links to specific diseases:

[Peste des petits ruminants in Europe - GOV.UK](#)

[Bluetongue virus in Europe.](#)

[Epizootic haemorrhagic disease in Europe](#)

[Sheep and goat pox in Europe - GOV.UK](#)

Foot and Mouth Disease (FMD):

[Foot and Mouth Disease \(FMD\) in Cyprus - GOV.UK](#)

Links to information on differential diagnoses can be found here:

[Differential diagnosis of diseases causing oral lesions in cattle - Holliman - 2005 - In Practice - Wiley Online Library](#)

[Differential diagnosis of oral lesions and FMD in sheep](#)

The **Biothreats Emergence, Analysis and Communications Network (BEACON)** is an open-source informal surveillance program designed to revolutionize global biothreats surveillance and response. Leveraging advanced artificial intelligence (AI), large language models (LLMs) and a network of globally based experts, BEACON rapidly collects, analyses, and disseminates information on emerging infectious diseases affecting humans, animals, and the environment.

Publications of interest

APHA Surveillance Reports on GOV.UK

[Monthly APHA disease surveillance reports](#)

[APHA focus articles published in the Veterinary Record](#)

The 2024 edition of the *Salmonella* in animals and feed in Great Britain (previously called *Salmonella* in Livestock Production in GB) has been published and is now available here:

[Salmonella in animals and feed in Great Britain](#)

SRUC-VS Surveillance Reports

[Scottish Government Veterinary Services Programme](#)

SRUC Veterinary surveillance blogs

[Veterinary surveillance blogs](#)

Other Publications

1. Lewis SE, Cawthraw SA, Wales AD, Rawlins M, Brown D, Ring I, Huby T, Sandu C, Jinks R, Snow LC, Wyllie S, Mackintosh A, Smith RP, Evans S, Martelli F. **Salmonella in the slaughter sheep population in England and Wales**. *Journal of Applied Microbiology*. 2025 Oct 6;136(10):lxaf244. doi: 10.1093/jambio/lxaf244. PMID: 41065640.
2. Ganter, M. (2025). **Anemia in Sheep and Goats**. In: Simões, J. (eds) *Encyclopedia of Livestock Medicine for Large Animal and Poultry Production*. Springer, Cham. https://doi.org/10.1007/978-3-031-52133-1_276-1
3. Prins S, Ellis K, Orr J, McKeegan D. **Investigating the behavioural responses of sheep used for teaching veterinary undergraduates**. *Veterinary Record*. 2025;e5669. <https://doi.org/10.1002/vetr.5669>
4. Benmebarek H, Djefal S, Benhamza L, Bouaziz O, Medjedoub S, Smadi MA, and others. **Epidemiological, pathological and microbiological investigation of neonatal lamb mortality in the region of Constantine, Algeria**. *Veterinary Record Open*. 2025; 12:e70021. <https://doi.org/10.1002/vro2.70021>
5. Mena MO; Moellmann VM; Bassetto CC; Lins JGG; Fernandes MA; Moreira GR; Albuquerque ACA; Fernandes EaN; Louvandini H; Amarante AFT (2025). **Effects of zinc oxide nanoparticle supplementation in young sheep naturally infected with gastrointestinal nematodes**. *Veterinary Parasitology: Regional Studies and Reports*. <https://doi.org/10.1016/j.vprsr.2025.101340>
6. Angell JW, Ahmed N, Jackson LP, Kasiora K, Ballingall K, Duncan JS. **Randomised controlled field trial to assess the safety and efficacy of a killed autologous vaccine against *Streptococcus dysgalactiae* subspecies *dysgalactiae* in a sheep flock**. *Veterinary Record*. 2025;e5667. <https://doi.org/10.1002/vetr.5667>
7. Lewerin, S.S. (2025), **Understanding the factors influencing veterinarians' antimicrobial prescribing practices**. *Veterinary Record*, 197: 455-457. <https://doi.org/10.1002/vetr.70143>



© Crown copyright 2026

Statement regarding use of this material

The material in this report has been compiled by the Animal and Plant Health Agency (APHA) Surveillance Intelligence Unit in collaboration with the APHA Surveillance and Laboratory Services Department. Images are governed by Crown Copyright except where specifically acknowledged to have been provided by others external to APHA. Use of material directly from the report is acceptable provided APHA (or others where specifically indicated) is acknowledged as the owner of the material. This does not include use of the APHA logo which should be excluded or used only after permission has been obtained from APHA Corporate Communications (apha.corporatecommunications@apha.gov.uk).

You may re-use this information (excluding logos) free of charge in any format or medium, under the terms of the Open Government Licence v.3. To view this licence visit www.nationalarchives.gov.uk/doc/open-government-licence/version/3/ or email PSI@nationalarchives.gsi.gov.uk

Data Protection:

For information on how we handle personal data visit www.gov.uk and search Animal and Plant Health Agency Personal Information Charter.

This publication is available at <https://www.gov.uk/government/collections/animal-disease-surveillance-reports>

Any enquiries regarding this publication should be sent to us at

[Rudolf.reichel@apha.gov.uk]

www.gov.uk/apha

APHA is an Executive Agency of the Department for Environment, Food and Rural Affairs and works on behalf of the Scottish Government, Welsh Government and Food Standards Agency to safeguard animal and plant health for the benefit of people, the environment and the economy.