


Great Britain Wildlife Disease Surveillance

Partnership quarterly report

Disease surveillance and emerging threats



Volume 37: Quarter 2 – April to June 2022

Highlights

- **Unusual injuries in urban foxes in Bristol and Bath.....page 18**
- **Salmonella Hessarek in a great spotted woodpecker.....page 26**
- **Combined Wildlife Disease Data 2021 summary.....page 30**

Contents

Introduction and overview	3
Issues and trends	3
Notifiable diseases	4
Great Britain AI Wild Bird Surveillance (AIWBS): Quarter 2 April to June 2022	4
Wildfowl and Wetlands Trust's (WWT) role in Great Britain Avian Influenza Wild Bird Surveillance (AIWBS):- April to June 2022.....	10
Zoonotic Diseases.....	11
APHA Diseases of Wildlife Scheme (DoWS); Salmonellosis in Wildlife	11
Report from Wildlife Zoonoses and Vector Borne Disease Research Group	12
Garden Wildlife Health Summary	12

Mammal reports	15
Wild mammal reports from APHA Diseases of Wildlife Scheme (DoWS).....	15
Wild mammal reports from Scotland	22
Avian Reports.....	22
Wildfowl and Wetlands Trust (WWT) report	22
Wild bird reports from Scotland	24
Wild bird reports IoZ	25
Wild bird reports from APHA DoWS	29
Appendix 1 – Combined Wildlife Disease Data 2021	30

Introduction and overview

The Great Britain Wildlife Health Partnership, comprising the Animal and Plant Health Agency (APHA), Scotland's Rural College (SRUC) Veterinary Services, Institute of Zoology (IoZ), the Centre for Environment, Fisheries and Aquaculture (CEFAS), the Wildfowl and Wetlands Trust (WWT), Natural England (NE), Forestry England (FE) and the Garden Wildlife Health (GWH) project, produces the Great Britain Wildlife Disease Surveillance Partnership Quarterly Reports:

<https://www.gov.uk/government/publications/wildlife-gb-disease-surveillance-and-emerging-threats-reports>

A full explanation of how data is analysed is provided in the annexe available on GOV.UK <https://www.gov.uk/government/publications/information-on-data-analysis>

Issues and trends

The highly pathogenic avian influenza (HPAI) outbreak in Great Britain remains the primary issue in wildlife in Quarter 2 of 2022. The reports of mass mortalities of coastal populations of wild birds along the British coastlines over the past quarter, and continuing into Quarter 3, is of concern. The timing over breeding season likely exacerbated the spread. Further details are included in the report below.

The mean temperature in Great Britain in Quarter 2 was above average. The Met Office report that every month so far in 2022 has had above average mean temperatures. In addition, rainfall had been below average across eastern Great Britain by end of June 2022.

At the June GB Wildlife Disease Surveillance Partnership meeting, the Partnership changed its name to the "GB Wildlife Health Partnership" to better reflect the work of the Partnership as it changes and evolves. The compilation of some of the wildlife disease data collected by three of the partners can be found in this Quarterly Report's appendix and we hope this will be an interesting read, lead to further collaborations and guide future work within the Partnership and beyond.

Notifiable diseases

Great Britain AI Wild Bird Surveillance (AIWBS): Quarter 2 April to June 2022

Total wild bird surveillance

H5N1 continues to be the dominant circulating strain during the second quarter of 2022 with detections in all devolved administrations of the United Kingdom (UK), including Northern Ireland. From a Great British perspective, the current avian influenza (AI) season continues to be the largest that GB has experienced, from both a wild bird and poultry disease perspective.

During the second quarter of 2022 a total of 871 birds were tested under the Wild Bird Avian Influenza Surveillance scheme in Great Britain, with 458 tested positive for highly pathogenic H5 and 413 negative. This takes the total of positive birds from the beginning of the season (October 2021) up to 1346, with submissions from 331 locations in 78 counties and affecting a total of 57 species.

Figure 1: Number of HPAI positive wild birds by week since the start of the current outbreak in October 2021.

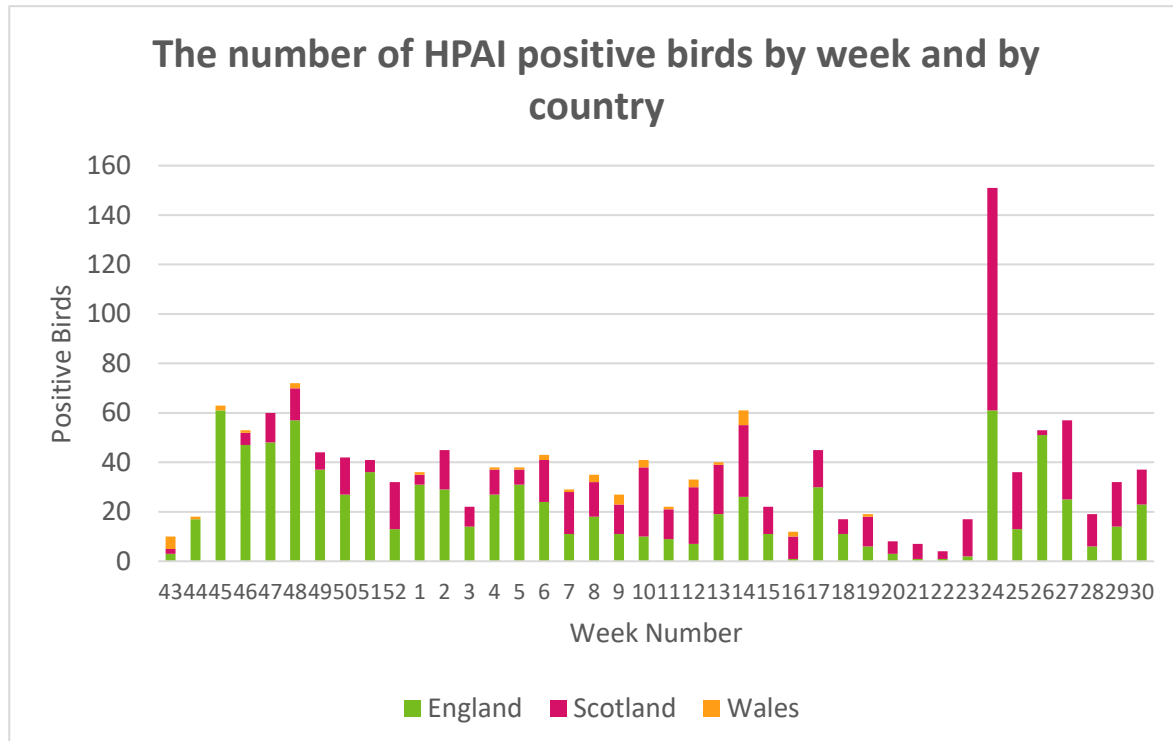


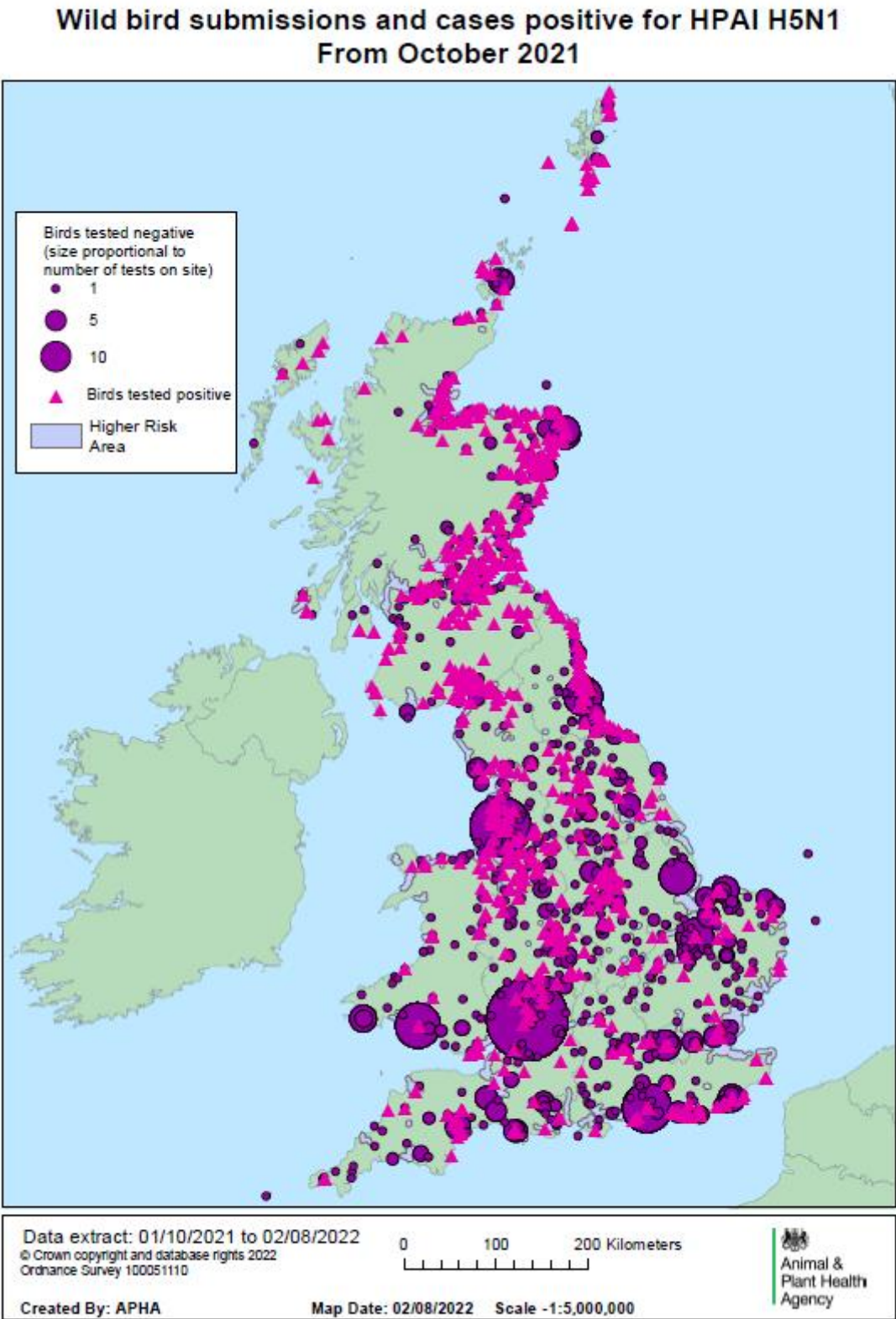
Table 1: Number of wild birds testing positive for HPAIV by species and country in quarter 2.

Region and species	Country	Total number of birds testing positive per species
Arctic Tern	England	1
Barnacle Goose	England	13
Bewick's Swan	England	1
Black headed gull	England	32
Black Swan	England	2
Canada Goose	England	153
Common Buzzard	England	60
Common Eider	England	1
Common Tern	England	5
Coot	England	1
Cormorant	England	1
Curlew	England	2
Gadwall	England	1
Gannet	England	25
Goshawk	England	1
Great-crested Grebe	England	3
Grey Heron	England	3
Greylag goose	England	38
Guillemot	England	4
Hen Harrier	England	3
Herring Gull	England	79
Kestrel	England	6
Kittiwake	England	1
Lapwing	England	1
Little Egret	England	1
Little Gull	England	1
Magpie	England	1
Mallard Duck	England	16
Moorhen	England	5
Mute Swan	England	235
Oystercatcher	England	1
Peregrine Falcon	England	5
Pheasant	England	8
Pied Wagtail	England	6
Pink Footed goose	England	18
Puffin	England	1
Razorbill	England	1

Region and species	Country	Total number of birds testing positive per species
Red Kite	England	2
Roseate Tern	England	1
Sandwich Tern	England	9
Sea Eagle	England	1
Sparrowhawk	England	7
Tawny Owl	England	1
Tufted Duck	England	1
White Fronted Goose	England	1
Whooper Swan	England	31
Widgeon	England	1
Arctic Tern	Scotland	4
Barnacle Goose	Scotland	34
Bird of Prey Unspecified	Scotland	5
Black headed gull	Scotland	2
Blackbird	Scotland	1
Canada Goose	Scotland	3
Common Buzzard	Scotland	63
Common Eider	Scotland	13
Gannet	Scotland	107
Golden Eagle	Scotland	2
Great Black Backed Gull	Scotland	3
Great Skua	Scotland	19
Greylag Goose	Scotland	26
Guillemot	Scotland	28
Herring Gull	Scotland	12
Kestrel	Scotland	1
Kittiwake	Scotland	1
Magpie	Scotland	1
Mallard Duck	Scotland	1
Manx Shearwater	Scotland	1
Mute Swan	Scotland	28
Pink Footed goose	Scotland	80
Razorbill	Scotland	2
Red Kite	Scotland	3
Sandwich Tern	Scotland	1
Sea Eagle	Scotland	3
Sparrowhawk	Scotland	5
Whooper Swan	Scotland	9
Wood Pigeon	Scotland	1

Region and species	Country	Total number of birds testing positive per species
Black headed gull	Wales	1
Canada Goose	Wales	4
Carrion Crow	Wales	2
Common Buzzard	Wales	4
Goshawk	Wales	1
Greylag Goose	Wales	1
Herring Gull	Wales	3
Mute Swan	Wales	15
Peregrine Falcon	Wales	1
Pheasant	Wales	5
Sparrowhawk	Wales	1

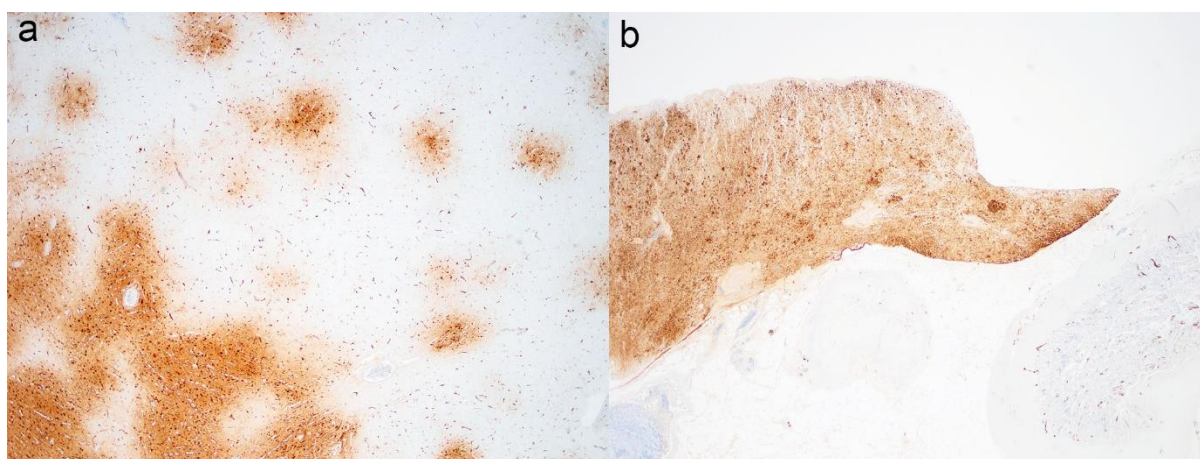
Figure 2: wild bird submissions and cases positive for HPAI H5N1 from October 2021 to 18 July 2022.



PME examinations

Postmortem examinations (PME) were conducted on selected wild birds following confirmation of HPAI detection. This included pied wagtail, white-tailed sea eagle, goshawk, great skua, eider duck, black backed gull, tawny owl, gannet, herring gull, and puffin. Most of the carcasses were autolysed or scavenged, therefore limited gross pathology interpretations could be made. Where carcass preservation was acceptable, gross changes for HPAI were generally absent. Histopathology and viral immunohistochemistry conducted on a small subset of great skua revealed multi-systemic infection such as in the brain, pancreas (Figure 3), heart and spleen, similar to previous outbreaks.

Figure 3: Multisystemic infection of HPAI H5N1 in the great skua (*Stercorarius skua*). Virus antigens detected in the brain (a) and pancreas (b).



Current EU situation

Wild bird along with poultry detections of predominantly HPAI H5N1 are still considered high. The current EU and UK outbreak situations can be found here:

[Avian influenza \(bird flu\) in Europe, Russia and the UK - GOV.UK](#)

APHA, in collaboration with Defra, monitors the international situation and distribution of avian influenza detections:

[Animal diseases: international and UK monitoring - GOV.UK](#)

Current UK Situation

Numbers of reports of wild birds to the Defra Helpline by members of the public have increased considerably end of May / beginning of June due to spread of the disease within seabird populations (particularly in Great Skuas, Herring Gulls, Gannets). The spread was firstly detected in the Scottish Islands and in the North East of Scotland and rapidly developed down South (Along the East coast of Scotland and England) up to the English Southern coast.

At the present time the official risk level of HPAI H5 in wild birds is therefore maintained at MEDIUM across Great Britain. The housing order which came into force on 29th November 2021 remained in force until 2 May 2022. At all times, poultry keepers should maintain robust biosecurity measures, be vigilant for clinical signs of disease and promptly report suspected cases of notifiable avian disease in poultry to APHA:

- In England – call the Defra Rural Services Helpline on **03000 200 301**. The Helpline is open Monday to Friday, 8.30am to 5pm and there is an out of hours facility on the same number for reporting suspicion of disease in animals.
- In Wales, the helpline number is 0300 303 8268.
- In Scotland, contact your local APHA Field Services Office:
[contact APHA](#).

Further information regarding avian influenza in poultry and wild birds is also available:

- [Avian influenza \(bird flu\) guidance](#)
- [Biosecurity information, avian influenza](#)
- [When and how to register your poultry flock, and which species must be registered](#)
- Information about the chargeable testing scheme on the [APHA Vet Gateway: Testing for exclusion of notifiable avian diseases](#)

References

- Gibbens N, Brown IH, Irvine RM. Testing for exclusion of notifiable avian disease. Veterinary Record 2014;**174**:534-535. <http://dx.doi.org/10.1136/vr.g3412>
- [Avian influenza in wild birds - GOV.UK](#)

Marco Falchieri Avian Virology, APHA Weybridge

Fabian Lean, Natalia Furman Veterinary Pathology, APHA Weybridge

Wildfowl and Wetlands Trust's (WWT) role in Great Britain Avian Influenza Wild Bird Surveillance (AIWBS):- April to June 2022

Throughout this second quarter of 2022, WWT continued to carry out passive surveillance of avian influenza across the reserves. Between April and July, 62 dead wild birds were found across six WWT sites located in Gloucestershire, West Sussex, Greater London, Tyne and Wear, Lancashire and Carmarthenshire. Of the birds found, 59 were sampled for avian influenza virus, with three carcasses being too heavily predated or in advanced decomposition to swab. 11 priority target species were sampled during this quarter. These included species of swan, geese, ducks, gulls and rails. In addition, samples were also obtained from three non-priority species: a common crane (*Grus grus*), water rail (*Rallus aquaticus*) and an oystercatcher (*Haematopus ostralegus*).

Highly pathogenic avian influenza (HPAIV H5N1) was confirmed by PCR in 13 dead wild birds, collected at five surveillance sites (Table 2).

All carcasses were swabbed and collected following recommended health and safety guidelines with full personal protective equipment (PPE), including FFP3 masks and goggles or face visors. Positive AI carcasses were disposed of using an approved high capacity incinerator for Category 1 ABP.

Table 2: confirmed avian influenza cases in wild birds at different surveillance sites, detected between April and June 2022

Site location	Total HPAI positive	Species
West Sussex	7	2 Mallard 3 Herring gull 2 Black-headed gull
Greater London	3	3 Moorhen
Carmarthenshire	1	Black-headed gull
Gloucestershire	1	Greylag Goose
Tyne and Wear	1	Black-headed gull
Total	13	

For further details of HPAI surveillance from across Great Britain, please refer to the APHA report for this quarter.

Rosa Lopez, Veterinary Officer (Conservation), Wildfowl & Wetlands Trust (WWT)

Zoonotic Diseases

APHA Diseases of Wildlife Scheme (DoWS); Salmonellosis in Wildlife

There is no routine monitoring of Salmonella in wild birds or wild mammals. Therefore, all isolates are usually from clinical cases, although Salmonella may often not be the primary cause of disease. Occasionally it is isolated from small-scale surveys.

There were no reports of Salmonella species detection in wildlife for Quarter 2 of 2022.

Catherine Man, APHA Diseases of Wildlife Scheme

Report from Wildlife Zoonoses and Vector Borne Disease Research Group

Passive surveillance for lyssaviruses in UK bats

One hundred and thirty-three bats were tested for lyssaviruses under passive surveillance during this quarter. Two bats were positive for lyssavirus. One Serotine from Dorset was positive for EBLV-1, and one Daubentons from Kent was positive for EBLV-2.

Eight exotic zoo bats were tested in this quarter for lyssaviruses. All were negative.

One suspect bat case was submitted. A serotine from Dorset was positive for EBLV-1.

Rabies diagnosis

Three cats and one dog that died in quarantine were tested for lyssaviruses with negative results.

Rabies surveillance in terrestrial wildlife

Vigilance continues for this notifiable disease in UK wildlife but no samples from terrestrial wildlife were submitted for testing this quarter.

West Nile virus surveillance and Usutu virus surveillance in wild birds

Brain and kidney tissue samples from one hundred and ninety-five wild birds were submitted via APHA, SRUC and IoZ and were tested by RT-PCR for WNV with negative results.

Tissues from forty-eight wild birds were also tested by RT-PCR for Usutu virus all with negative results.

West Nile virus surveillance in Equids

One serum sample was received for WNV serology testing as a test to exclude case during this quarter. The sample was negative for WNV antibodies.

Dr Arran Folly, Vector-borne diseases, APHA Weybridge

Garden Wildlife Health Summary

The Garden Wildlife Health project (GWH) based at IoZ has continued to conduct scanning disease surveillance of garden birds, hedgehogs, reptiles, and amphibians. The

disease incident reports (DIRs) received, and PME's conducted by the GWH team during Quarter 2 2022 are summarised in Table 3 and 4, and Figure 4.

Table 3: shows the numbers of Garden Wildlife Health disease incident reports and postmortem examinations for Quarter 2 2022.

Taxon	Number of disease incident reports	Total number of animals observed	Number of postmortem examinations
Amphibians	88 across 75 sites	448 (30 sick and 418 dead)	14 across 7 sites
Birds	892 across 513 sites	1153 (662 sick and 491 dead)	21 across 17 sites
Hedgehogs	141 across 130 sites	171 (34 sick and 137 dead)	9 across 9 sites
Reptiles	10 across 10 sites	12 (0 sick and 12 dead)	0
Total	1131 across 728 sites	1784 (726 sick and 1058 dead)	44 across 33 sites

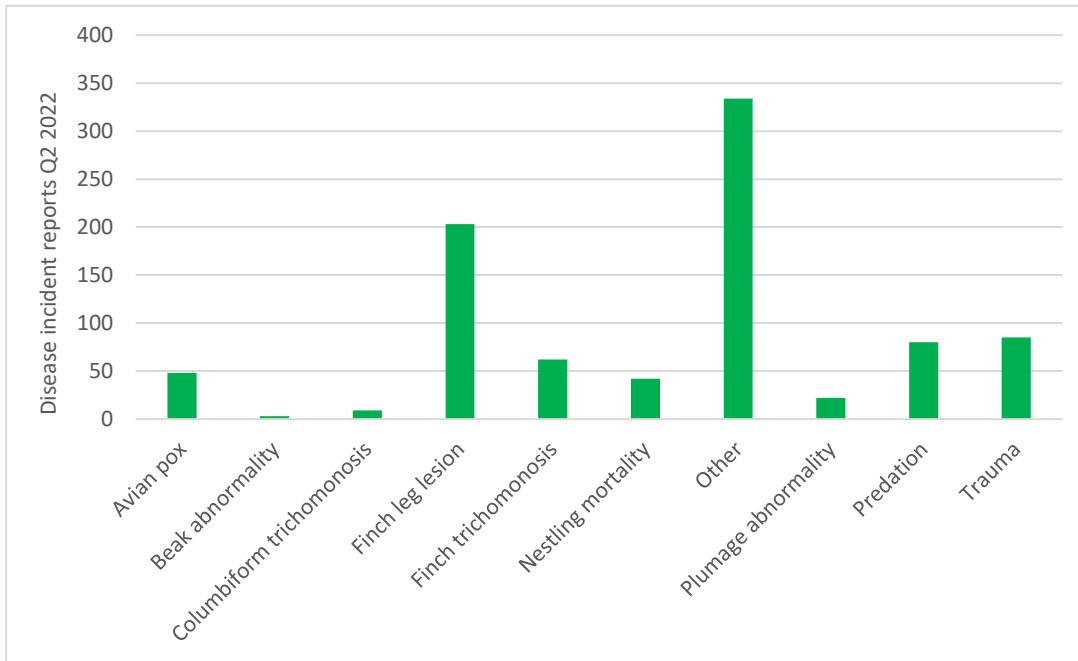
Table 4: compares the numbers of Garden Wildlife Health disease incident reports for Quarter 2 2021 and 2022.

Taxon	Number of disease incident reports in Quarter 2	
	2021	2022
Amphibians	127 (44 sick and 372 dead)	88 (30 sick and 418 dead)
Birds	1281 (1008 sick and 794 dead)	892 (662 sick and 491 dead)
Hedgehogs	186 (25 sick and 168 dead)	141 (34 sick and 137 dead)
Reptiles	13 (0 sick and 13 dead)	10 (0 sick and 12 dead)
Total	1607 (1077 sick and 1347 dead)	1131 (726 sick and 1058 dead)

No unusual trends in GWH DIRs were observed this quarter, and whilst the overall number of DIRs was reduced in Quarter 2 2022 in contrast to Quarter 2 2021, It is comparable to the 1065 DIRs received over the same period in 2019, reflecting pre-COVID-19 pandemic numbers.

Since the higher number of DIRs received last year is considered likely, in part, to be as a result of increased observer effort during the COVID-19 pandemic restrictions, with people spending more time at home and in their gardens, with restrictions being completely removed in February 2022, the reduction of DIRs compared to Quarter 2 2021 is not unexpected.

Figure 4 shows the numbers of Garden Wildlife Health avian disease incident reports allocated suspect diagnoses for Quarter 2 2022, with the category of 'other' mostly comprising reports of birds exhibiting non-specific signs of ill health (e.g. fluffed-up plumage, lethargy). Further information on [avian pox](#), [beak abnormality](#), [finch leg lesions](#), [trichomonosis](#), and [plumage abnormality](#) is available by following the respective links.



Institute of Zoology (IoZ)

Mammal reports

Wild mammal reports from APHA Diseases of Wildlife Scheme (DoWS)

Amyloidosis in a badger (*Meles meles*)

A badger submitted to investigate cause of death was found to have changes suggestive of a hepatopathy and nephropathy, and the histopathological lesions were consistent with systemic amyloidosis. This was confirmed with Congo Red staining. The exact inciting cause of the amyloidosis remains unclear.

Hepatic abscessation in a grey seal (*Halichoerus grypus*)

A grey seal pup was submitted to investigate the cause of seizures. Gross postmortem examination identified peritonitis and hepatic abscessation, with reddening of the lungs. Bacteriology was unrewarding, likely due to the degree of autolysis and putrefaction. Histopathological changes confirmed the gross findings, as well as identifying a mild focal suppurative myocarditis, and pyogranulomatous bronchopneumonia with intralesional nematodes (suspect *Otostrongylus circumlitus*). The latter is a common cause of debilitation in grey seal pups.

It was concluded that the hepatic abscess could have been the result of an ascending navel infection, or a localisation of systemic bacteraemia. The seizures were attributed systemic sequelae of either the pneumonia or hepatic abscess, likely due metabolic disruption (e.g. hepatic encephalopathy, etc.).

Myxomatosis in rabbits (*Oryctolagus cuniculus*)

Myxomatosis in rabbits has been diagnosed in mortality events twice in the Thirsk region.

The most recent was in a submission of a dead rabbit submitted to investigate the cause of death. It had been found dead by a railway embankment with reports of multiple deaths in the area over the preceding month. Some rabbits had appeared to be completely blind, and one other had been seen to have “broad-bean sized” lumps across the skin. Gross findings included submandibular abscessation, thickening of the eyelids with exudate around the eye, and pallor of the liver. *Staphylococcus aureus* was isolated from the abscesses and the histopathological findings indicated that this likely resulted in secondary dissemination of infection, leading to the hepatic necrosis.

There was also evidence of myxomatosis, with observation of the virus on electron microscopy, and the presence of inclusion bodies within the epithelium. These findings account for the death of the rabbit, and in particular the identification of myxomatosis is a significant finding with relation to the mass mortality reported. A clinical update was provided that suggested deaths seemed to have reduced in the area.

The second diagnosis was in a rabbit found dead on the grounds of a university, submitted to investigate the cause of death. The gross findings included multiple cream-coloured lumps approximately 1-3cm in diameter across the skin of the limbs, primarily distal to the humerus or femur, and particularly around the metacarpals. The lumps had a creamy coating, which sloughed off to reveal raised, pink coloured protuberances with a pink-white radiating pattern on the cut surface (see Figure 5). There was similar creamy material adhered to areas of skin across the ears. Histopathological lesions included severe, multifocal, acute to subacute, proliferative, and ulcerative, pustular dermatitis with dermal proliferation with diffuse myxoid changes, oedema, and myxoma cells. Electron microscopy was positive for Orthopoxvirus, and BLAST sequencing results identified the virus as Myxomavirus. This testing was carried out due to the unusual appearance, and to

rule out the possibility of other poxviruses, such as Shope Fibroma virus. Unusual presentations of myxomatosis have been reported from wildlife disease surveillance cases in the past (Simpson et. al, 2017), as well as pet rabbits (Whitehead, 2017), and it is important to remain vigilant for the emergence of new presentations such as these.

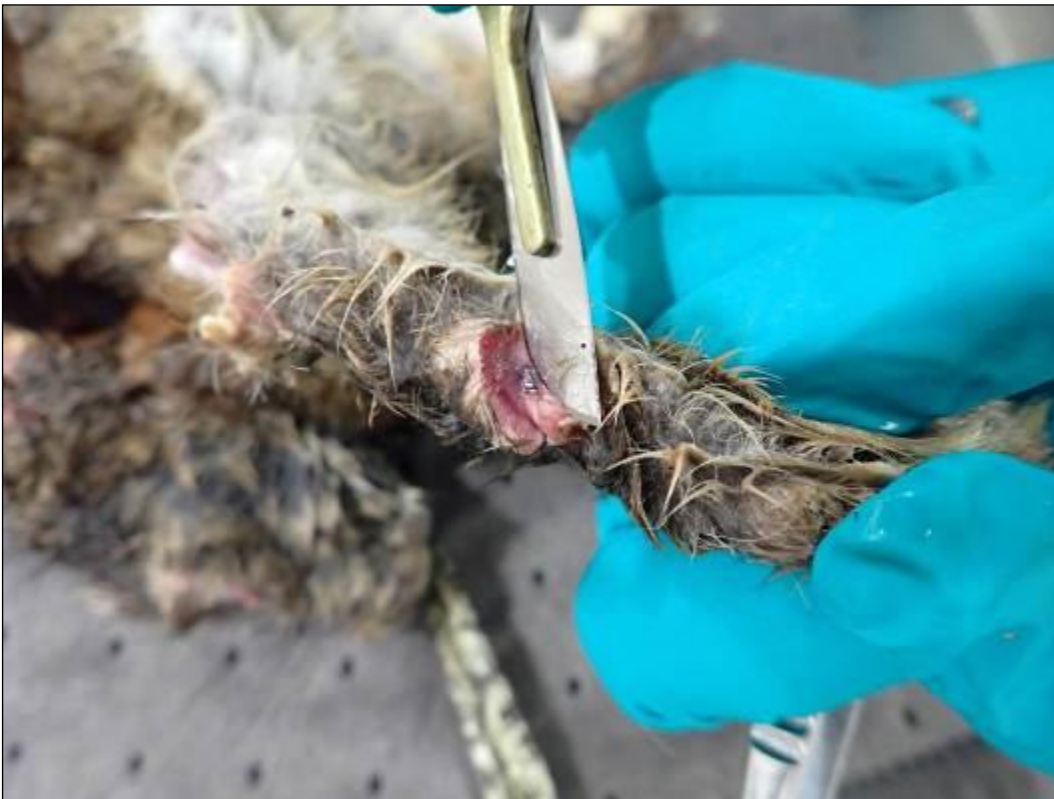

Figure 5 Cross section of a cutaneous myxoma in a case of myxomatosis in a European rabbit.

References

Simpson V, Everest DJ, Dastjerdi A, Davies H and Hargreaves J. Unusual presentation of myxomatosis. The Veterinary Record, 2017: **181**(13), p.350.

<https://doi.org/10.1136/vr.j4450>

Whitehead, M.L., 2017. Unusual presentation of myxomatosis. The Veterinary Record, **181**(14), p.375. <https://doi.org/10.1136/vr.j4557>

Ed Fullick, APHA Thirsk

Unusual injuries in urban foxes (*Vulpes vulpes*) in Bristol and Bath

Severe facial injuries

Camera trap photographs (Figure 6) from Bath showed four foxes with extensive facial lesions. Another one was also trapped, put to sleep on humane grounds and submitted to Wildlife Network for Disease Surveillance (WNDS) for necropsy. This was a juvenile dog fox in very poor bodily condition, weighing 2.08 kg.



Figure 6: red fox photo from a camera trap.

On the left side of the muzzle there was an area of ulceration extending approximately 4cm vertically and 3.5 cm horizontally (Figure 7). The teeth and tongue were exposed and the ulcerated area is bordered by developing granulation tissue. There was also a smaller area of ulceration over the right mandible extending 1.5 cm. x 1.0cm. The rostral 4cm of the left mandible was missing so there were only caudal molar teeth present and teeth were also missing from the maxilla. Muscle necrosis was seen on the left side of the head subjacent to the ulcerated area.

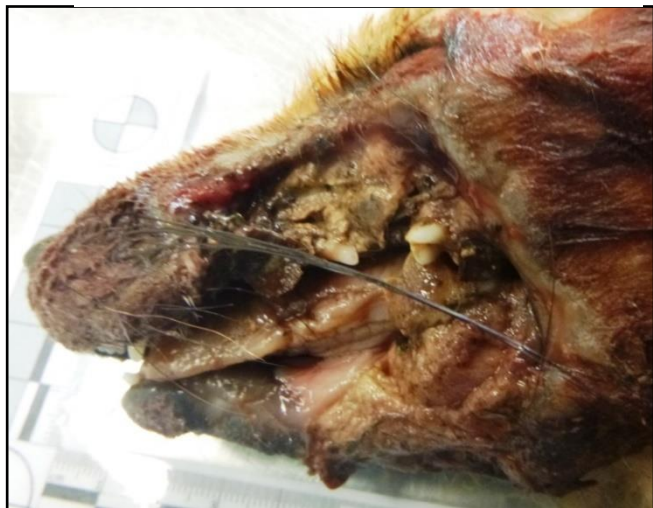

Figure 7: area of ulceration on left side of muzzle.

Bacteriology revealed no evidence of septicaemia and the gross mixed flora with probable *Proteus* spp. was cultured from the contaminated wound. The evidence would suggest non-fatal trauma, probably road traffic accident, to this fox causing extensive facial and jaw damage. This fox obviously lived for a few days before being caught and put to sleep.

A second fox with similar facial lesions was found a few weeks later in Bristol (Figure 8). This again was a juvenile dog fox in poor condition weighing 4.03 kg.

It had an extensive wound on the right side of its face, extending about 6.5cm anterior-caudally and 6 cm from the top of the nose to below the lower jaw. This wound was reasonably fresh although in areas there was some greyish discolouration.

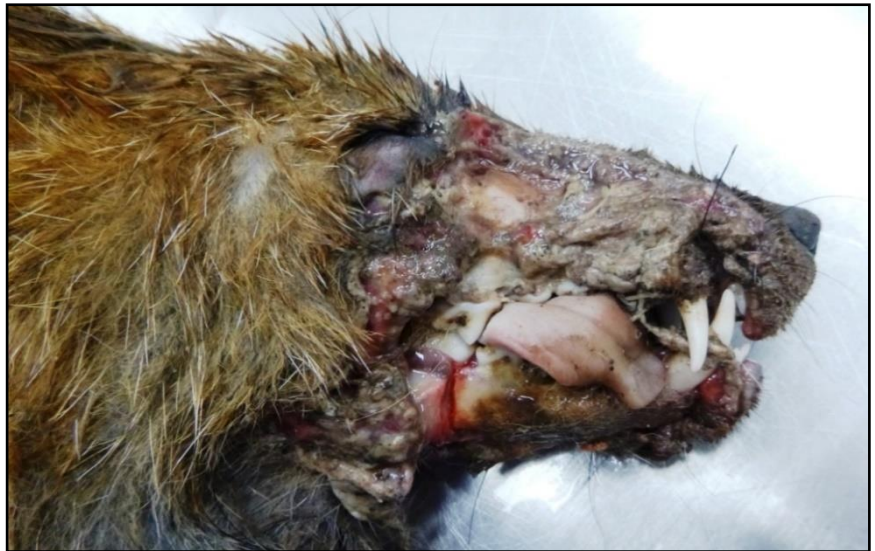

Figure 8: additional fox with facial lesions.

The lower jaw was intact although the first premolars on the right was missing and the second and third were loose. There were mild superficial skin abrasions on the lower limbs. Haemothorax and peritoneum were seen with blood clots over the liver. There were no other significant findings. This fox didn't die instantly but after a short interval. Trauma again probably due to a road traffic accident was the cause of the facial wound, internal haemorrhage and death of this fox.

Road traffic accidents are the most like cause of these injuries. Harris and Smith (1987) report road accidents as the cause of 55.6% - 62.8% mortalities in Bristol foxes with lower fox densities giving the higher mortality figures. I would suggest with the increase traffic since 1987 the mortality rate due to road traffic accidents would probably be higher now. It would be difficult to be sure how these injuries were caused but I assume a glancing blow from a sharp/angular part of a vehicle could do this.

Reference:

Harris S, Smith GC. Demography of two Urban Fox (*Vulpes vulpes*) Populations. Journal of Applied Ecology, 1987;**24** (1) pp 75-86 <https://doi.org/10.2307/2403788>

Snaring with discarded plastic

In April a vixen in Bristol that was seen tangled in plastic netting/fencing was trapped. She was then submitted to Secret World Wildlife Rescue and after treatment and recuperation was released back to where she was found.



Figure 9: vixen with plastic netting tangled around the left axilla.

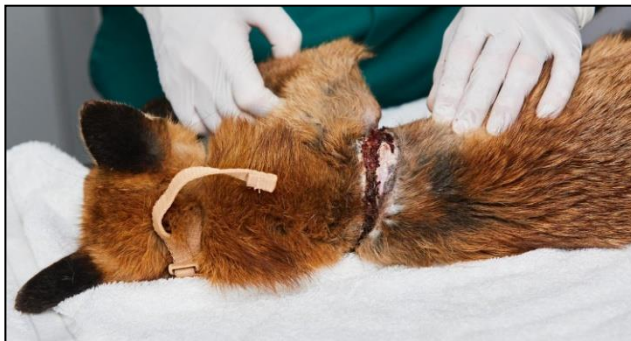

Figure 10: skin lesion visible following removal of the plastic.

Then on 10/11/21 this vixen was found lying dead on a pavement and it was submitted for necropsy. This was an adult vixen in fair condition weighing 6.53kg. A wound was present in the right axilla extending approximately 5cm in length. The wound extended through the skin, subcutaneous connective tissue and only superficially into the underlying muscle layer. There was a rim of hair loss adjacent to the wound and the surrounding fur was stained with dried blood. A line of hair loss ran diagonally from one end of the wound around the neck to join up with the other end of the wound. The abdominal cavity was filled

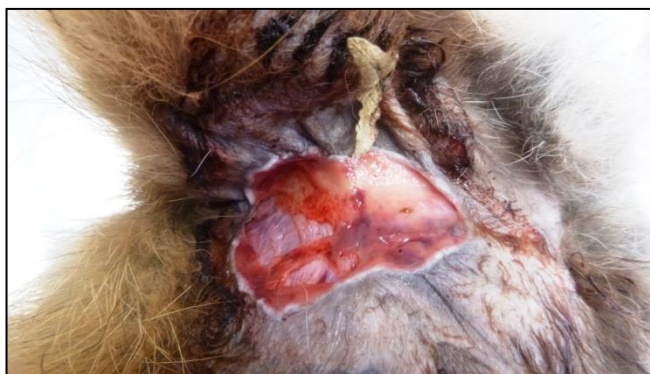

Figure 11: skin wound in axilla at postmortem exam.

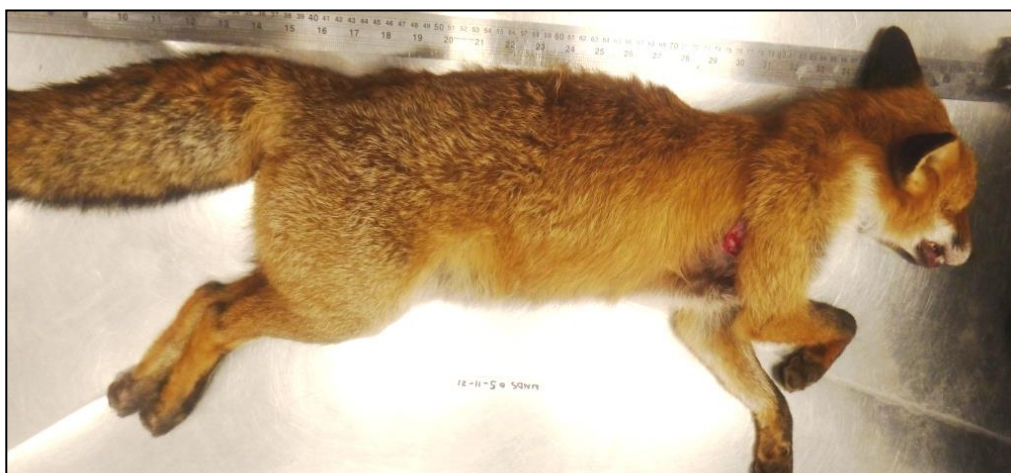

Figure 12: vixen at postmortem with visible wound in the right axilla.

with a large volume of free blood. The liver was pale and macerated and the spleen was split into two main parts.

These findings would indicate that this vixen had been initially entrapped by something that acted like a snare. The carcass wasn't emaciated so she had been able to move about and feed. Whatever was around the neck and leg of this fox obviously had been removed probably a short period before death. Severe acute trauma causing maceration of the liver, tearing of the spleen and haemorrhage into the cerebrospinal fluid resulted in fairly immediate death typical findings of a road traffic accident.

It was later reported that a lot of building work is going on in the area this vixen was found. Significantly a video of a fox was taken in the same area around the 20th July 2021 showed a fox with what looked like a strip of white plastic "snared" around the same leg and over the neck. This might suggest it is the same fox as submitted for necropsy.



Figure 13: a still shot taken from the video.

These are just further cases illustrating the welfare problems caused in animals and birds by negligently discarded mainly plastic waste. Also it highlights the value of citizen science in initially identifying these cases so they can be trapped and treated or put to sleep following triage.

Alex Barlow, Wildlife Network for Disease Surveillance (WNDS), University of Bristol Veterinary School; Zoe Webber, Bristol Fox study, Dan Bryant, Secret World Wildlife Rescue (SWWR)

Wild mammal reports from Scotland

No significant cases to report in Quarter 2 of 2022.

Avian Reports

Wildfowl and Wetlands Trust (WWT) report

Passive surveillance of water birds

Postmortem examinations were performed on 48 wild birds originating from six WWT sites (Arundel, West Sussex; Llanelli, Carmarthenshire; London Wetland centre, Greater London; Slimbridge, Gloucestershire; Martin mere, Lancashire and Welney, Norfolk). A total of 12 target species were examined, which included 12 mallards (*Anas platyrhynchos*), seven greylag geese (*Anser anser*), six whooper swans (*Cygnus cygnus*), five moorhens (*Gallinula chloropus*), five coots (*Fulica atra*), three tufted duck (*Aythya fuligula*), one black-headed gull (*Chroicocephalus ridibundus*), one mute swan (*Cygnus olor*), one canada goose (*Branta Canadensis*), one pintail (*Anas acute*), one cormorant (*Phalacrocorax carbo*) and one lapwing (*Vanellus vanellus*).

Four other species were also examined: a wood pigeon (*Columba palumbus*), a rook (*Corvus frugilegus*), a robin (*Erithacus rubecula*) and a common crane (*Grus grus*).

The primary causes of death for the abovementioned species are summarised below (Table 5).

The most notable postmortem finding was gross pathologic lesions related with trauma (23%). Mixed lesions observed within this group. Three mallards presented lesions compatible with same-species aggression (skin wounds, missing feathers and bruising around the head and along the back), as well as, secondary lesions such as internal haemorrhage, a cracked egg in the oviduct, and minor soft tissue trauma to the right hock. A robin and a tufted duck suffered from fatal head trauma, and another tufted duck also presented with internal haemorrhage from a collision, as did one coot, but incidentally also had internal parasites. Fractures in the limbs with secondary infection was identified in a coot, a greylag and a moorhen. Lastly, within this group, a juvenile common crane was crushed while resting, possibly by a large farm animal. Radiographs revealed spinal damage, atlanto-occipital joint dislocation and possible atlas fracture. Postmortem examination revealed haemorrhage concentrated along the dorsal aspect of the body, pericardial bleed and congested lungs.

Predation was another predominant primary cause (19%). The majority of the predated birds collected presented with intact skeletal structure and skin, as well as, minimal soft

tissue or missing sections, and absence or minimal presence of internal organs. High suspicion of a mixture of gull, bird of prey and, to a lesser extent, mustelid predation was suspected in many of these cases, with carcasses being headless, presenting dorsal puncture wounds and/or degloving lesions.

Lesions compatible with avian mycobacteriosis was found in five birds (5%): three mallards, one coot and one canada goose. Necropsy revealed a characteristic presentation of multifocal granuloma-like lesions throughout the intestinal mesentery and liver, renomegaly and purulent-mucoid free fluid in the coelomic cavity. The canada goose, in addition, presented a severe thickened, fibrotic pericardium and myocardium and pericardial effusion (Figure 14).

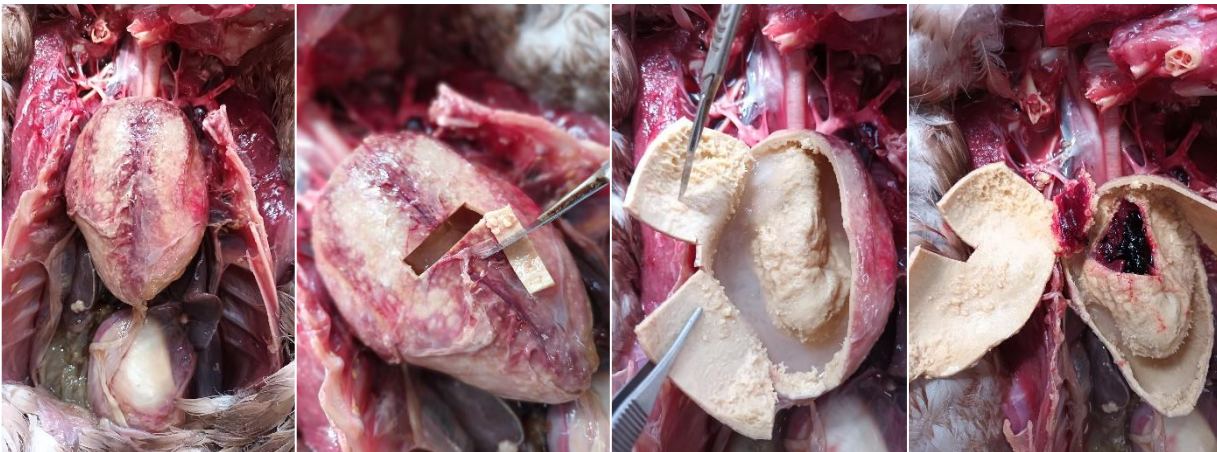


Figure 14: necropsy of a Canada goose, collected in West Sussex, with lesions caused by *Mycobacterium avium*.

Severe necrotising enteritis was detected in five whooper swans (5%). All carcasses presented congested intestinal loops, boluses of thickened intestinal content and splenomegaly. One swan also presented minor pericardial haemorrhage.

One mallard and one greylag had a combination of visceral and articular gout. Swollen left hock with secondary oedema extending down to the tarsometatarsus and interphalangeal joints. White material present within the joints. Visceral gout affecting myocardium, liver, kidneys and inter-costal muscles and pleura (coverage of thin urate deposit layer).

Other causes that were less prevalent during this quarter includes renal disease in a black-headed gull, severe parasitaemia and enteritis in two juvenile greylags and one adult greylag of very poor body condition, as well as, a possible lead intoxication in another adult greylag which presented with oesophagus impaction (dilated proventriculus), pale limbs, white mucous membrane and serosanguinous discharge from the left nare. A lack of food availability and intestinal worms was the most likely cause of death in two moorhens. Aspergillosis was detected in a mallard which had extensive, invasive, and infiltrating nodular lesions affecting more than one area of the respiratory tract (pulmonary tissue, air sacs and trachea) and poor body condition, as well as, secondary air sacculitis.

Another oesophageal and proventricular obstruction was identified in a cormorant; however, in this case it was due to two overly large eels that had not been swallowed properly. Bruising along the oesophageal mucosal lining was also detected in this case. Lastly, one pintail's mortality was associated with toxemia with generalised congestion of coelomic organs, splenomegaly, intestinal petechiae and swollen left hock with increased synovial fluid content on postmortem examination.

Six wild birds (13%) did not receive a diagnosis due to advanced decomposition, lack of obvious gross abnormalities or multifactorial non-fatal lesions present.

Table 5: Confirmed and suspected causes of wild bird mortality (including morbidity meriting euthanasia on welfare grounds) at WWT reserves between April and July 2022.

Primary cause of death/Postmortem findings	Total	Species (and notes)
Trauma	11	3 x mallards, 2 x coot, 2 x tufted ducks, 1 x coot, 1 x common crane (juvenile), 1 x robin, 1 x moorhen
Predation	9	4 x mallards, 2 x moorhens, 1 x rook, 1 x greylag, 1 x tufted duck
Avian mycobacteriosis	5	3 x mallards, 1 x coot, 1 x Canada goose
Necrotic enteritis	5	5 x whooper swans
Visceral gout	2	1 x greylag, 1 x mallard
Other	10	4 x greylag geese (two juvenile with enteritis, lead intoxication, internal parasites,), 2 x moorhen (internal parasites, starvation), 1 x mallard (airsacculitis, aspergillosis), 1 x cormorant (oesophageal obstruction), 1 x black-headed gull (renal failure, starvation), 1 x pintail (toxaemia)
No diagnosis (due to decomposition or lack of or inconclusive gross abnormalities)	6	2 x coots, 1 x lapwing, 1 x mute swan, 1 x whooper swan, 1 x wood pigeon

**Rosa Lopez, Veterinary Officer (Conservation),
Wildfowl & Wetlands Trust (WWT)**

Wild bird report from Scotland

No significant cases to report in Quarter 2 of 2022.

Wild bird report loZ

Plastic ingested in the ventriculus of an adult male red kite (*Milvus milvus*) that was emaciated

In July 2022, a case report was published on a single red kite (*Milvus milvus*), found dead in Hampshire and submitted to the loZ's Disease Risk Analysis and Health Surveillance project (DRAHS) for postmortem examination in 2018. The red kite was in poor body condition with minimal amounts of subcutaneous fat present. The ventral right wing had a rupture of the skin with associated dried blood staining of the skin and feathers, exposing the bone of the distal humerus and proximal radius and ulna (Figure 15A). Internally, minimal amounts of fat were present in the caudal coelom, and the pectoral muscles were dark in colour.

The serosal surface of the ventriculus was pale green, and the mucosa did not show any lesions; it contained a minimal amount of brown mucoid paste and a piece of irregularly folded white-beige plastic with sharp edges (35 × 32 × 1 mm) and brown discoloration in some areas (Figure 15B). Toxicological examination of liver samples detected potentially toxic levels of second-generation anticoagulant rodenticides (SGARs) in this bird (difenacoum 3.0 ng/g, brodifacoum 734.9 ng/g).



Figure 15A: shows a rupture of the skin and exposure of the bone of the distal humerus on the ventral right wing.

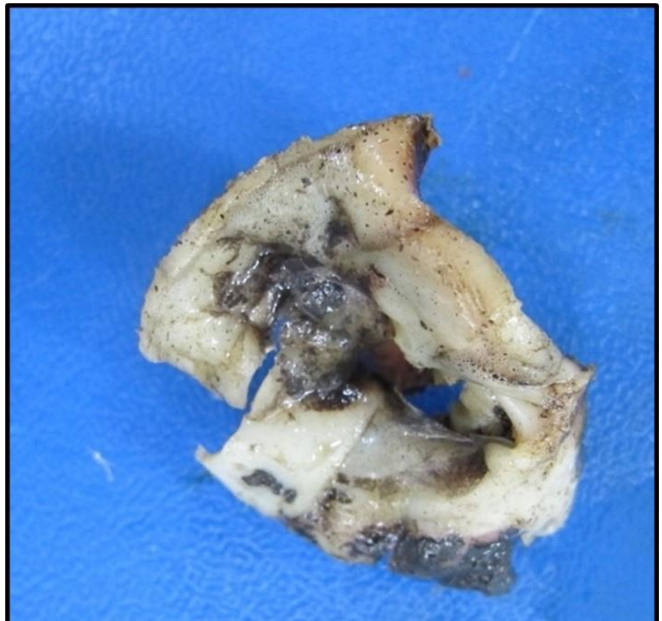


Figure 15B: a piece of irregularly folded plastic (35 × 32 × 1 mm) found in the ventriculus of a red kite with poor body condition.

Three possible contributors to mortality were considered: starvation from the ingestion of plastic preventing normal digestion, collision-related trauma and second-generation

anticoagulant rodenticide poisoning. This is the first report of plastic ingestion in a red kite. The case highlights the importance of carrying out postmortem examinations as part of post-release health surveillance and identifies plastic ingestion as a potential anthropogenic threat and welfare concern facing the red kite population in England.

Reference

Gerard G, Common SM, Jaffe JE, Shadbolt T, Sainsbury AW. Plastic ingestion in an emaciated red kite (*Milvus milvus*) in England. *Vet Record Case Reports*. 2022; e454. <https://doi.org/10.1002/vrc2.454>

Institute of Zoology

Garden bird Salmonellosis – update

In April 2022, a great spotted woodpecker (*Dendrocopos major*) was found dead in Kent and submitted for postmortem examination. The bird was found to be in thin body condition, with signs of dehydration and congested vessels observed on the heart and brain surface. The spleen appeared enlarged and was dark- brown with multifocal beige-coloured lesions throughout the organ. Furthermore, the lungs were mottled dark red to dark brown in colour, with a beige discolouration of the ventral surface.

A *Salmonella* sp. was isolated from the spleen, lungs, liver, and small intestinal contents upon microbiological examination. The isolate was submitted to the UK Health Security Agency for further characterisation, and sequence analysis identified the bacterium as *Salmonella* Hessarek. Histopathological examination and immunohistochemistry conducted at APHA Weybridge confirmed multi-organ necrosis due to disseminated salmonellosis as the cause of death (Figure 16).

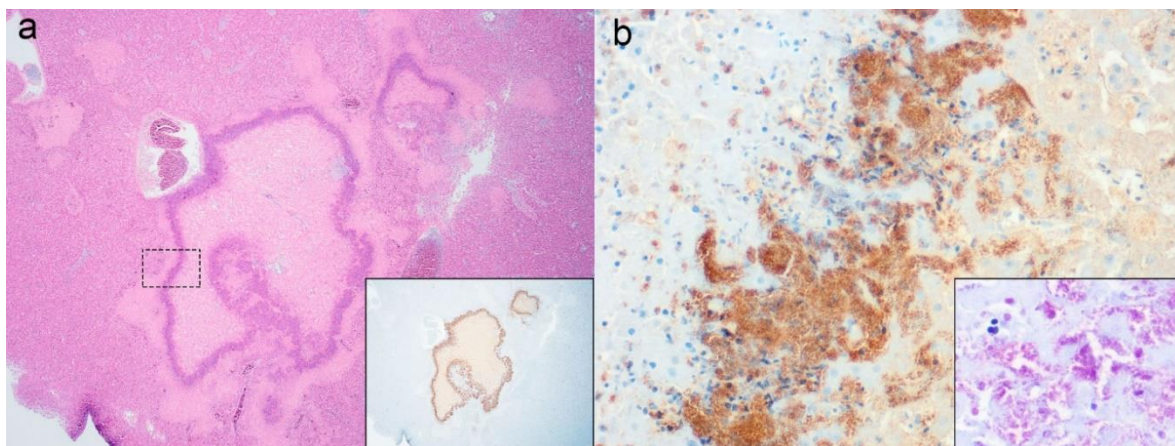


Figure 16: shows histopathological images from the great spotted woodpecker (*Dendrocopos major*), hepatic necrosis is shown at (a) low (2x) and (b) high (40x)

magnification. Serial sections demonstrate immunopositive labelling for Salmonella CSA-1 antigen (inset a, b) and Gram-negative bacilli (inset b).

At IoZ, only two previous cases of Salmonella Hessarek infection in garden birds have been confirmed, both involving a single great spotted woodpecker which were found dead at separate sites in Surrey in 2013 and 2016 (Wilkinson and others, 2019). Whilst S. Hessarek has been known to cause infrequent disease outbreaks in song thrush (*Turdus philomelos*) and starling (*Sturnus vulgaris*) in Europe and the Middle East, to our knowledge there were no previous published reports of isolation from a piciform species (Singer and others, 1977; Velarde and others, 2012).

Great spotted woodpecker is not a species which is frequently submitted to the GWH project, indeed, only ten other birds of this species have been examined postmortem since 2013. Continued surveillance is required to improve understanding of whether this novel S. Hessarek variant may be host-adapted to the great spotted woodpecker in GB.

References

Singer N, Weissman Y, Yom-Tov Y, Marder U. Isolation of Salmonella Hessarek from starlings (*Sturnus vulgaris*). *Avian Diseases* 1977: **21**:1 p.117-119
<https://doi.org/10.2307/1589370>

Velarde R, Porrero MC, Serrano E, Marco I, García M, Téllez S, Domínguez L, Aymí R, Lavín S. Septicemic salmonellosis caused by Salmonella Hessarek in wintering and migrating Song Thrushes (*Turdus philomelos*) in Spain. *Journal of Wildlife Diseases* 2012: **48**:1 p.113-121 <https://doi.org/10.7589/0090-3558-48.1.113>

Wilkinson V, Rodriguez-Ramos Fernandez J, Núñez A, Macgregor SK, John SK, Dallman T, Cunningham AA, de Pinna EM, Lawson B. Novel Salmonella sp. Variant Associated with Mortality in Two Great Spotted Woodpeckers (*Dendrocopos major*). *Journal of Wildlife Diseases* 2019: **55**:4 p.874–878 <https://doi.org/10.7589/2018-08-191>

IoZ and APHA

Usutu virus infection in garden birds - update

Usutu virus is a flavivirus that was first detected in Africa in the late 1950s that has emerged in multiple countries in mainland Europe since the 1990s (Clé and others, 2019). The virus is transmitted between birds, the primary hosts, through bites from infected mosquitoes. Songbirds and owls have been most commonly affected by the virus in mainland Europe: the blackbird (*Turdus merula*) appears highly susceptible and mortality at a scale sufficient to cause local population decline has previously been reported in some countries. A small number of cases of human infection with USUV, usually neurological disease, have so far been reported in mainland Europe, however, current

evidence suggests most USUV infections in humans are asymptomatic (i.e. do not cause disease) and the risk to public health is considered low.

As reported in Quarter 3 & Quarter 4 2020, Usutu virus was detected for the first time in wild birds in the UK in summer 2020 (Folly and others, 2020). Five blackbirds and one house sparrow (*Passer domesticus*) were examined postmortem from a single site in Greater London, and USUV infection was confirmed. Phylogenetic analysis identified Usutu virus African 3.2 lineage, which is known to occur in mainland Europe, and represents the probable origin of this incursion to the UK, thought likely to have occurred as a result of wild bird and/or mosquito movement.

A multidisciplinary team was assembled to further investigate the occurrence of USUV in host and vector populations and to appraise the potential impact of the 2020 outbreak on wild bird populations using national citizen science monitoring datasets (Lawson and others, 2022). USUV was detected in *Culex pipiens* s.l. mosquitoes at the index site following the outbreak. Whilst national syndromic surveillance found no evidence of an increase in neurological signs in blackbirds consistent with USUV infection, there was a regional cluster of disease incident reports of this species around Greater London in 2020. This was matched in time and space with a reduction in the reporting rate and number of blackbirds observed in gardens. Furthermore, the recent Breeding Bird Survey 2021 identified a 39% decline in blackbird in the Greater London region over the period 2019-2021 (Harris and others, 2022). Whilst causality cannot be ascribed, these findings support a hypothesis of disease-mediated population decline.

Continued surveillance and testing of samples collected from postmortem examination of 175 birds in 2021 resulted in only a single further blackbird from Greater London testing positive for USUV infection. Samples from 48 birds from across Great Britain, collected over period April-June 2022 inclusive, have tested rtPCR negative for Usutu virus. Wild bird surveillance will continue as routine for the remainder of the 2022 mosquito active season. Whether USUV will recur and if climatic conditions may support persistence of USUV in the UK in the future remains uncertain.

References

Clé M, Beck C, Salinas S, Lecollinet S, Gutierrez S, Van de Perre P, Baldet T, Foulongne V, Simonin Y. Usutu virus: A new threat? *Epidemiology and Infection* 2019:

147. doi.org/10.1017/S0950268819001213

Folly AJ, Lawson B, Lean FZ, McCracken F, Spiro S, John SK, Heaver JP, Seilern-Moy K, Masters N, Hernández-Triana LM, Phipps LP, Nuñez, A, Fooks, AR, Cunningham, AA, Johnson, N, McElhinney, LM. Detection of Usutu virus infection in wild birds in the United Kingdom. *Eurosurveillance* 2020; **25**:41: 2001732. doi.org/10.2807/1560-7917.ES.2020.25.41.2001732

Harris SJ, Massimino D, Balmer DE, Kelly L, Noble DG, Pearce-Higgins JW, Woodcock P, Wotton S, Gillings S. 2022. The Breeding Bird Survey 2021. BTO Research Report 745. British Trust for Ornithology, Thetford.

Lawson B, Robinson RA, Briscoe AG, Cunningham AA, Fooks AR, Heaver JP, Hernández-Triana LM, John SK, Johnson N, Johnston C, Lean FZ. Combining host and vector data informs emergence and potential impact of an Usutu virus outbreak in UK wild birds. Scientific Reports 2022: **12**:1 p.1-10 doi.org/10.1038/s41598-022-13258-2

IoZ and APHA

Wild bird report from APHA DoWS

Myocarditis of unknown origin in a common buzzard

A myocarditis of unknown origin was detected in a wild common buzzard (*Buteo buteo*) submitted as part of the Avian Influenza in Wild Birds Survey (AIWBS). Postmortem examination revealed a small area of oedema in the coelomic wall by the last rib, and mild liver enlargement. Extensive areas of loss of cardiac myofibres associated with an interstitial reaction, mononuclear cells, occasional granulocytes, and the occasional cluster of pigmented cells were seen on histopathological exam, indicating a severe endocarditis. Despite extensive laboratory testing, a cause for the myocarditis could not be determined.

Consideration should be given to notifiable diseases in cases of myocarditis in raptors as myocarditis can be seen in both avian influenza (AIV) and West Nile Virus (WNV) infections. WNV (and other flaviviruses including Usutu virus) surveillance is routinely performed on dead wild birds submitted to Veterinary Investigation Centres (VICs) from the 1st April until the 31st October, in line with the vector season. Other possible differentials, excluded by laboratory testing, included *Toxoplasma gondii* and bacterial infections, in particular Pasteurellaceae.

Paul Holmes, APHA Shrewsbury

Appendix 1 – Combined Wildlife Disease Data 2021

Appendix 1 incorporates data from APHA Diseases of Wildlife Scheme, SRUC and Garden Wildlife Health (Institute of Zoology) wildlife submissions from 2021. This was achieved using the VIDA (Veterinary Investigation Diagnosis Analysis) coding system; listed diagnoses have set criteria that need to be fulfilled.

This data set only includes routine diagnostic submissions and does not include project work. Only a subset of the wild birds testing positive for avian influenza virus have been included in this summary (those received at the APHA Veterinary Investigation Centres). For the complete avian influenza in wild bird data set please refer to [Avian influenza in wild birds: 2021](#)

“Mixed bird” submissions are submissions where multiple species have been submitted together. Some species have been listed as “unspecified” or unknown. This is usually due to severe autolysis impeding definitive identification or because the carcass is incomplete, making full identification impossible.

Please note that the count is by submission, and not by carcass, in all the tables below. A single submission may often contain multiple carcasses.

Table 2: the number of submissions by category of animal and country

Country	Animal Category	APHA	IOZ	SRUC	Total
England	Amphibian	0	16	0	16
England	Birds	669	38	2	709
England	Mammal	133	23	0	156
England	Reptile	0	5	0	5
Total for England		802	82	2	886
Scotland	Birds	21	3	197	221
Scotland	Mammal	0	0	34	34
Total for Scotland		21	3	231	255
Wales	Birds	27	3	0	30
Wales	Mammal	24	0	0	24
Wales	Reptile	0	3	0	3
Total for Wales		51	6	0	57
Total for all countries		877	91	233	1201

Table 3: the number of submissions by category of animal and quarter reported

Animal Category	Year	Quarter	APHA	IOZ	SRUC	Total
Amphibian	2021	2	0	10	0	10
Amphibian	2021	3	0	4	0	4
Amphibian	2021	4	0	2	0	2
Total number of amphibians	2021		0	16	0	16
Birds	2021	1	163	0	80	243
Birds	2021	2	138	21	28	187
Birds	2021	3	39	13	34	86
Birds	2021	4	377	10	57	444
Total number of birds	2021		717	44	199	960
Mammal	2021	1	33	0	9	42
Mammal	2021	2	27	3	9	39
Mammal	2021	3	45	8	10	63
Mammal	2021	4	55	12	6	73
Total number of mammals	2021		160	23	34	217
Reptile	2021	2	0	4	0	4
Reptile	2021	3	0	4	0	4
Total number of reptiles	2021		0	8	0	8
Total number of submissions	2021		877	91	233	1201

Table 4: the number of submissions by sub-category of animal

Animal Category	Animal Subcategory	APHA	IOZ	SRUC	Total
Amphibian	Frog	0	9	0	9
	Newt	0	6	0	6
	Toad	0	1	0	1
Total number of amphibians		0	16	0	16
Birds	Bird of prey	144	1	95	240
	Game bird	4	0	4	8
	Garden bird	21	40	11	72
	Miscellaneous	0	2	0	2
	Pigeon and dove	16	1	0	17
	Seabird	59	0	29	88
	Waterbird	26	0	4	30
	Waterfowl	440	0	54	494
	Unspecified	7	0	2	9
Total number of birds		717	44	199	960
Mammal	Bat	5	0	0	5
	Canid	14	0	3	17
	Deer	2	0	2	4
	Hedgehog	23	23	1	47
	Rabbit and hare	18	0	5	23
	Mustelid	5	0	22	27
	Rodent	38	0	1	39
	Seal	49	0	0	49
	Wild boar	6	0	0	6
Total number of mammals		160	23	34	217
Reptile	Snake	0	8	0	8
Total number of reptiles		0	8	0	8
Total number of submissions		877	91	233	1201

Figure 2: the number of submissions by species category per month

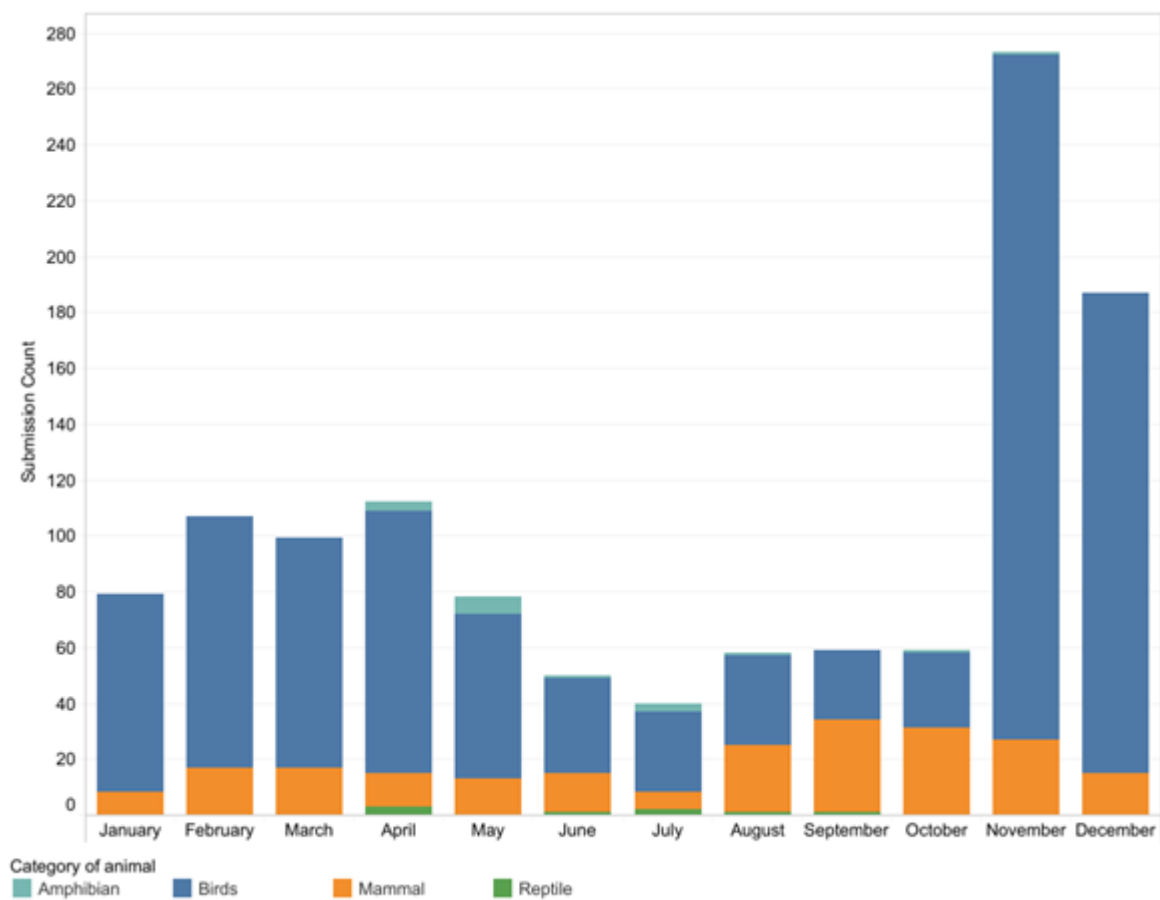


Table 5: the number of mammalian submissions by species

Group	Common Name	Scientific Name	APHA	IOZ	SRUC	Total
Bat	Brandt's bat	Myotis brandtii	1	0	0	1
	Brown long-eared bat	Plecotus auritus	1	0	0	1
	Common pipistrelle bat	Pipistrellus pipistrellus	1	0	0	1
	Serotine bat	Eptesicus serotinus	1	0	0	1
	Whiskered bat	Myotis mystacinus	1	0	0	1
Canid	Red fox	Vulpes vulpes	14	0	3	17
Deer	Roe deer	Capreolus capreolus	2	0	2	4
Hedgehog	European hedgehog	Erinaceus europaeus	23	23	1	47
Rabbit and hare	Brown hare	Lepus europaeus	10	0	4	14
	European rabbit	Oryctolagus cuniculus	8	0	1	9
Mustelid	American mink	Neovison vison	0	0	1	1
	Badger	Meles meles	3	0	9	12
	Eurasian otter	Lutra lutra	1	0	12	13
	Polecat	Mustela putorius	1	0	0	1
Rodent	Beaver	Castor fiber	1	0	1	2
	Red squirrel	Sciurus vulgaris	37	0	0	37
Seal	Common/harbour seal	Phoca vitulina	20	0	0	20
	Grey seal	Halichoerus grypus	29	0	0	29
Wild boar	Wild boar	Sus scrofa	6	0	0	6
Total number of submissions			160	23	34	217

Table 6: the number of bird submissions by species

Animal Subcategory	Group	Common Name	Scientific Name	APHA	IOZ	SRUC	Total
Bird of prey	Buzzard	Common buzzard	Buteo buteo	67	0	56	123
	Eagle	Golden eagle	Aquila chrysaetos	0	0	2	2
		White-tailed eagle	Haliaeetus albicilla	0	0	5	5
	Falcon	Kestrel	Falco tinnunculus	29	0	1	30
		Peregrine falcon	Falco peregrinus	3	0	2	5
		Merlin	Falco columbarius	0	0	1	1
	Hawk	Goshawk	Accipiter gentilis	1	0	3	4
		Sparrowhawk	Accipiter nisus	19	0	9	28
	Kite	Red kite	Milvus milvus	7	0	2	9
	Osprey	Western osprey	Pandion haliaetus	0	0	1	1
	Owl	Barn owl	Tyto alba	9	0	7	16
		Short-eared owl	Asio flammeus	1	0	0	1
		Tawny owl	Strix aluco	8	1	2	11

Animal Subcategory	Group	Common Name	Scientific Name	APHA	IOZ	SRUC	Total
Game bird	Harrier	Hen harrier	Circus cyaneus	0	0	4	4
	Grouse	Capercaillie	Tetrao urogallus	0	0	1	1
		Red (willow) grouse	Lagopus lagopus	0	0	2	2
	Pheasant	Common pheasant (feral)	Phasianus colchicus	4	0	0	4
	Partridge	Red-legged partridge (feral)	Alectoris rufa	0	0	1	1
Garden bird	Corvid						
		Carrion crow	Corvus corone corone	4	0	3	7
		Jay	Garrulus glandarius	0	1	0	1
		Magpie	Pica pica	0	0	2	2
		Raven	Corvus corax	1	0		1
		Corvid mixed		0	0	1	1
		Rook	Corvus frugilegus	2	0	2	4
	Finch						
		Bullfinch	Pyrrhula pyrrhula	0	1	0	1
		Chaffinch	Fringilla coelebs	1	4	0	5
		Goldfinch	Carduelis carduelis	0	5	2	7
		Greenfinch	Chloris chloris	0	6	0	6
		Siskin	Spinus spinus	2	3	1	6
		Lesser redpoll	Acanthis cabaret	0	2	0	2
		Finch mixed		1	0	0	1
	Flycatcher						
		Robin	Erithacus rubecula	3	0	0	3
	Sparrow						
		House sparrow	Passer domesticus	0	1	0	1
	Starling	Common starling	Sturnus vulgaris	5	0	0	5
	Thrush	Blackbird	Turdus merula	1	11	0	12
	Tit						
		Blue tit	Cyanistes caeruleus	0	3	0	3
		Great tit	Parus major	0	1	0	1
	Warbler	Blackcap	Sylvia atricapilla	0	1	0	1
	Bunting						
		Yellowhammer	Emberiza citrinella	1	0	0	1
	Tree-clinging						
		Wren	Troglodytes troglodytes	0	1	0	1
Miscellaneous	Woodpecker						
		Green woodpecker	Picus viridis	0	1	0	1
		Great spotted woodpecker	Dendrocopos major	0	1	0	1
Pigeon and dove	Pigeon and dove						
		Collared dove	Streptopelia decaocto	3	0	0	3
		Woodpigeon	Columba palumbus	2	0	0	2

Animal Subcategory	Group	Common Name	Scientific Name	APHA	IOZ	SRUC	Total
Seabird		Feral pigeon / Rock dove	Columba livia	9	1	0	10
		Pigeon unspecified		2	0	0	2
	Auk	Razorbill	Alca torda	3	0	2	5
		Guillemot	Uria aalge	9	0	17	26
		Auk mixed		0	0	2	2
	Gull	Black-headed gull	Chroicocephalus ridibundus	10	0	0	10
		Common gull	Larus canus	7	0	0	7
		Herring gull	Larus argentatus	14	0	0	14
		Lesser black-backed gull	Larus fuscus	4	0	0	4
		Great black-backed gull	Larus marinus	1	0	0	1
		Little gull	Hydrocoloeus minutus	2	0	0	2
		Mediterranean gull	Ichthyaetus melanocephalus	1	0	0	1
		Gull mixed		1	0	0	1
		Gull unspecified		1	0	2	3
	Gannet, Cormorant and Shag	Cormorant	Phalacrocorax carbo	3	0	1	4
		Northern gannet	Morus bassanus	2	0	1	3
	Skua	Great skua	Stercorarius skua	0	0	4	4
	Tern	Sandwich tern	Sterna sandvicensis	1	0	0	1
Waterbird	Heron	Grey heron	Ardea cinerea	3	0	3	6
	Rail	Moorhen	Gallinula chloropus	4	0	0	4
		Coot	Fulica atra	6	0	1	7
	Wader	Woodcock	Scolopax rusticola	3	0	0	3
		Avocet	Recurvirostra avosetta	1	0	0	1
		Curlew	Numenius arquata	6	0	0	6
		Lapwing	Vanellus vanellus	1	0	0	1
	Grebe	Great crested grebe	Podiceps cristatus	2	0	0	2
Waterfowl	Duck	Mallard	Anas platyrhynchos	41	0	0	41
		Mallard hybrid		1	0	0	1
		Aylesbury duck (feral)	Anas platyrhynchos domesticus	1	0	0	1

Animal Subcategory	Group	Common Name	Scientific Name	APHA	IOZ	SRUC	Total
		Eider	Somateria mollissima	1	0	0	1
		Gadwall	Mareca strepera	1	0	0	1
		Goosander	Mergus merganser	2	0	0	2
		Mandarin Duck	Aix galericulata	2	0	0	2
		Muscovy duck (feral)	Cairina moschata	1	0	0	1
		Shelduck	Tadorna tadorna	4	0	0	4
		Tufted duck	Aythya fuligula	3	0	0	3
		Wigeon	Mareca penelope	3	0	0	3
		Duck unspecified		1	0	0	1
	Goose	Brent goose	Branta bernicla	1	0	0	1
		Canada goose	Branta canadensis	69	0	1	70
		Greylag goose	Anser anser	18	0	3	21
		Pink-footed goose	Anser brachyrhynchus	6	0	9	15
		Barnacle goose	Branta leucopsis	13	0	11	24
		Snow goose	Anser caerulescens	1	0	0	1
		Goose unspecified		3	0	1	4
	Swan	Black swan (feral)	Cygnus atratus	2	0	0	2
		Mute swan	Cygnus olor	246	0	20	266
		Whooper swan	Cygnus cygnus	6	0	6	12
		Bewick's swan	Cygnus columbianus	1	0	0	1
		Swan unspecified		13	0	3	16
Unspecified	Mixed or Unknown Bird	Mixed birds		6	0	0	6
		Bird unspecified		1	0	0	1
		Not stated		0	0	2	2
Grand Total				717	44	199	960

Table 7: number of amphibian and reptile submissions by species

Animal Category	Group	Common Name	Scientific Name	IOZ	Grand Total
Amphibian	Frog	Common frog	Rana temporaria	9	9
	Newt	Great crested newt	Triturus cristatus	3	3
		Palmate newt	Lissotriton helvetica	2	2
		Smooth newt	Lissotriton vulgaris	1	1
	Toad	Common toad	Bufo bufo	1	1
Reptile	Snake	Adder	Vipera berus	3	3
		Aesculapian snake	Zamenis longissimus	1	1
		Grass snake	Natrix natrix	4	4
Grand Total				24	24

Table 7: number of VIDA diagnoses in mammals by species

Group	Common Name	Diagnosis Description	Number of Diagnoses Made
Bat	Brandt's bat	Diagnosis not listed - skin disease	1
	Serotine bat	Diagnosis not listed - skin disease	1
	Whiskered bat	Diagnosis not listed - skin disease	1
Canid	Red fox	Hereditary/Developmental Abnormalities	1
		Streptococcal infection	1
		Trauma: Predation	1
		Trauma: Road Traffic Accident	1
		Diagnosis not listed - circulatory disease	4
		Diagnosis not listed - musculo-skeletal disease	1
Deer	Roe deer	Fasciolosis	1
		Neoplasm	1
		Parasitic gastroenteritis	1
Hedgehog	European hedgehog	Coccidiosis	1
		Malnutrition	2
		Parasitic pneumonia	9
		Salmonellosis	12
		Staphylococcal infection	1
		Streptococcal infection	3
		Trauma: Predation	7
		Trauma: Road Traffic Accident	1
		Trauma/fracture	1
		Visceral parasitism	2
		Diagnosis not listed - skin disease	1
Rabbit and hare	Brown hare	Coccidiosis	2
		Pneumonia	1
		Staphylococcal infection	1

Group	Common Name	Diagnosis Description	Number of Diagnoses Made
		Trauma: Predation	1
		Trauma: Road Traffic Accident	1
		Trauma/fracture	1
		Yersiniosis	2
	Rabbit	Myxomatosis	2
		Rabbit haemorrhagic disease	5
		Septicaemia	2
		Staphylococcal infection	1
		Diagnosis not listed - skin disease	1
Mustelid	American mink	Poisoning dt chemicals	1
	Badger	Meningitis/encephalitis	1
		Salmonellosis	1
		Trauma: Road Traffic Accident	4
		Trauma/fracture	4
		Diagnosis not listed - circulatory disease	1
		Diagnosis not listed - respiratory disease	1
	Eurasian otter	Ectoparasitic disease	1
		Trauma: Road Traffic Accident	2
		Trauma/fracture	3
		Diagnosis not listed - circulatory disease	1
		Diagnosis not listed - digestive disease	1
		Diagnosis not listed - nervous disease	1
		Diagnosis not listed - systemic disease	1
	Polecat	Ectoparasitic disease	1
		Parasitic pneumonia	1
Rodent	Beaver	Trauma/fracture	1
	Red squirrel	Amyloidosis	1
		Coccidiosis	1
		Nephritis	1
		Red squirrel adenovirus enteritis	10
		Squirrel pox	14
		Staphylococcal infection	3
		Trauma: Predation	3
		Trauma: Road Traffic Accident	1
		Trauma/fracture	4
		Visceral parasitism	1
		Diagnosis not listed - digestive disease	1
		Diagnosis not listed - skin disease	1
		Diagnosis not listed - systemic disease	1
		Diagnosis not listed - urinary disease	1
Seal	Common/harbour seal	Colisepticaemia	2
		Ectoparasitic disease	1

Group	Common Name	Diagnosis Description	Number of Diagnoses Made
		Malnutrition	1
		Navel Ill/Joint Ill	1
		Pneumonia	3
	Grey seal	Endocarditis	1
		Malnutrition	1
		Pasteurellosis	1
		Pneumonia	5
		Streptococcal infection	1
		Trauma: Predation	1
		Trueperella pyogenes infection	1
		Diagnosis not listed - digestive disease	1
		Diagnosis not listed - musculo-skeletal disease	3
		Diagnosis not listed - systemic disease	1
Wild boar	Wild boar	Gastric ulceration	2
		Metritis	1
		Parasitic pneumonia	1
		Diagnosis not listed - systemic disease	2

Table 8: number of VIDA diagnoses in birds by species

Animal Subcategory	Group	Common Name	Diagnosis Description	Number of Diagnoses Made
Bird of prey	Buzzard	Common buzzard	Adverse environment	2
			Avian Influenza	10
			Helminthosis	1
			Malnutrition	34
			Poisoning dt chemicals	1
			Trauma: Predation	5
			Trauma: Road Traffic Accident	4
			Trauma/fracture	14
			Tuberculosis	1
			Diagnosis not listed - digestive disease	1
			Diagnosis not listed - systemic disease	5
			Diagnosis not listed - urinary disease	1
	Eagle	Golden eagle	Trauma/fracture	1
		White-tailed eagle	Avian Influenza	1
			Trauma/fracture	3
	Falcon	Kestrel	Adverse environment	1
			Avian Influenza	3
			Malnutrition	6
			Diagnosis not listed - digestive disease	1
		Merlin	Malnutrition	1
		Peregrine	Avian Influenza	1
			Diagnosis not listed - skin disease	1

Animal Subcategory	Group	Common Name	Diagnosis Description	Number of Diagnoses Made
	Harrier	Hen harrier	Malnutrition	3
	Hawk	Goshawk	Avian Influenza	1
		Sparrowhawk	Avian Influenza	1
			Helminthosis	1
			Malnutrition	7
			Oral trichomonosis (avian) including oesophagitis in garden birds	1
			Trauma: Predation	1
			Trauma: Road Traffic Accident	2
			Trauma/fracture	4
			Diagnosis not listed - digestive disease	2
	Kite	Red kite	Avian Influenza	1
			Trauma/fracture	3
	Osprey	Western osprey	Trauma/fracture	1
	Owl	Barn owl	Malnutrition	3
			Poisoning dt chemicals	1
			Trauma: Predation	1
			Trauma/fracture	5
		Short-eared owl	Trauma/fracture	1
		Tawny Owl	Malnutrition	1
			Oral trichomonosis (avian) including oesophagitis in garden birds	1
			Trauma: Road Traffic Accident	1
			Trauma/fracture	1
			Visceral parasitism	1
			Diagnosis not listed	1
			Diagnosis not listed - digestive disease	1
Game bird	Grouse	Capercaillie	Trauma/fracture	1
		Red (willow) grouse	Louping ill	1
			Septicaemia	1
			Trichostrongylosis	1
	Partridge	Red-legged partridge (feral)	Trauma/fracture	1
	Pheasant	Common pheasant (feral)	Avian Influenza	4
Garden bird	Bunting	Yellowhammer	Oral trichomonosis (avian) including oesophagitis in garden birds	1
	Corvid	Carrion crow	Pneumonia	1
			Septicaemia	1
			Trauma/fracture	2
			Visceral parasitism	1
			Diagnosis not listed - systemic disease	1
			Diagnosis not listed - urinary disease	1
		Jay	Colisepticaemia	1
		Magpie	Malnutrition	1
			Trauma: Predation	1

Animal Subcategory	Group	Common Name	Diagnosis Description	Number of Diagnoses Made
		Raven	Trauma: Predation	1
		Rook	Malnutrition	1
			Trauma: Road Traffic Accident	1
			Trauma/fracture	1
			Diagnosis not listed - respiratory disease	1
	Finch	Chaffinch	Ectoparasitic disease	2
			Oral trichomonosis (avian) including oesophagitis in garden birds	3
			Staphylococcal infection	1
			Trauma/fracture	1
		Goldfinch	Oral trichomonosis (avian) including oesophagitis in garden birds	4
			Salmonellosis dt S. Typhimurium	1
			Trauma/fracture	1
		Greenfinch	Oral trichomonosis (avian) including oesophagitis in garden birds	6
			Trauma: Predation	1
			Trauma/fracture	2
		Siskin	Malnutrition	1
			Oral trichomonosis (avian) including oesophagitis in garden birds	3
			Salmonellosis dt S. Typhimurium	2
			Trauma/fracture	1
		Lesser redpoll	Oral trichomonosis (avian) including oesophagitis in garden birds	2
		Finch mixed	Salmonellosis dt S. Typhimurium	1
	Flycatcher	Robin	Ectoparasitic disease	1
			Diagnosis not listed - skin disease	1
	Sparrow	House sparrow	Trauma: Predation	1
	Starling	Common starling	Trauma/fracture	1
			Diagnosis not listed - urinary disease	1
	Thrush	Blackbird	Coccidiosis	1
			Malnutrition	1
			Syngamus species infection (Gapeworm)	3
			Trauma: Predation	4
			Trauma/fracture	2
			Visceral parasitism	4
			Diagnosis not listed - circulatory disease	1
			Diagnosis not listed - digestive disease	1
			Diagnosis not listed - respiratory disease	1
			Diagnosis not listed - systemic disease	1
	Tit	Blue tit	Adverse environment	1
			Trauma: Predation	1

Animal Subcategory	Group	Common Name	Diagnosis Description	Number of Diagnoses Made
			Diagnosis not listed - respiratory disease	1
		Great tit	Avian pox	1
			Trauma: Predation	1
	Tree-clinging	Wren	Trauma: Predation	1
	Warbler	Blackcap	Trauma/fracture	1
			Visceral parasitism	1
Miscellaneous	Woodpecker	Great spotted woodpecker	Trauma/fracture	1
Pigeon and dove	Pigeon and dove	Collared dove	Oral trichomonosis (avian) including oesophagitis in garden birds	1
			Trauma/fracture	1
		Woodpigeon	Trauma/fracture	2
		Feral Pigeon / Rock Dove	Oral trichomonosis (avian) including oesophagitis in garden birds	1
			Paramyxovirus of pigeons (PPMV-1)	1
			Trauma: Predation	1
			Trauma/fracture	1
			Diagnosis not listed - systemic disease	1
Seabird	Auk	Razorbill	Malnutrition	3
		Auk mixed	Malnutrition	2
		Guillemot	Malnutrition	16
	Gannet, Cormorant and Shag	Cormorant	Malnutrition	1
			Visceral gout	1
		Northern gannet	Malnutrition	1
	Gull	Black-headed gull	Avian Influenza	2
			Botulism	2
		Herring gull	Malnutrition	1
			Pneumonia or airsacculitis, mycotic	1
			Trauma: Predation	1
			Trauma/fracture	4
			Yolk sac infection/omphalitis	1
		Lesser black-backed gull	Malnutrition	1
			Trauma/fracture	1
		Common gull	Avian Influenza	2
			Malnutrition	1
			Trauma/fracture	2
		Little gull	Avian Influenza	1
		Mediterranean gull	Trauma: Predation	1
		Gull mixed	Pneumonia or airsacculitis, mycotic	1
		Gull unspecified	Trauma: Predation	1
			Diagnosis not listed - respiratory disease	1
	Skua	Great skua	Diagnosis not listed - respiratory disease	2

Animal Subcategory	Group	Common Name	Diagnosis Description	Number of Diagnoses Made
			Diagnosis not listed - systemic disease	1
	Tern	Sandwich tern	Trauma: Predation	1
Waterbird	Grebe	Great crested grebe	Avian Influenza	2
	Heron	Grey heron	Adverse environment	1
			Malnutrition	1
			Salmonellosis dt S. Typhimurium	1
			Trauma/fracture	2
	Rail	Moorhen	Trauma/fracture	1
		Coot	Trauma: Predation	1
			Trauma/fracture	1
	Wader	Woodcock	Trauma/fracture	2
		Avocet	Botulism	1
		Curlew	Avian Influenza	2
			Impactions of crop/gizzard/duodenum	4
Waterfowl	Duck	Mallard	Avian Influenza	4
			Botulism	2
			Enterococcal infection	1
			Haemoparasitic infection	1
			Peritonitis of wild waterbirds - aetiology unknown	1
			Pneumonia or airsacculitis, mycotic	1
			Septicaemia	1
			Trauma: Predation	4
			Trauma: Road Traffic Accident	1
			Trauma/fracture	5
			Tuberculosis	1
		Aylesbury duck (feral)	Diagnosis not listed - digestive disease	1
		Gadwall	Avian Influenza	1
		Goosander	Trauma/fracture	2
		Mallard hybrid	Trauma/fracture	1
		Mandarin Duck	Trauma/fracture	1
		Shelduck	Avian Influenza	1
			Trauma: Predation	1
		Tufted duck	Botulism	1
			Trauma/fracture	1
			Tuberculosis	1
		Wigeon	Avian Influenza	1
			Tuberculosis	1
		Canada goose	Amyloidosis	1
			Avian Influenza	39
			Botulism	2
			Egg peritonitis/salpingitis complex	3
			Gizzard erosion	1

Animal Subcategory	Group	Common Name	Diagnosis Description	Number of Diagnoses Made
			Haemoparasitic infection	1
			Helminthosis	1
			Malnutrition	1
			Necrotic enteritis dt Clostridium perfringens	1
			Poisoning dt lead	1
			Trauma: Predation	3
			Trauma/fracture	5
			Diagnosis not listed - circulatory disease	2
			Diagnosis not listed - digestive disease	3
			Diagnosis not listed - systemic disease	1
		Greylag goose	Avian Influenza	11
			Trauma/fracture	2
			Diagnosis not listed - systemic disease	2
		Pink-footed goose	Avian Influenza	5
			Pneumonia or airsacculitis, mycotic	1
			Tuberculosis	3
			Diagnosis not listed - systemic disease	4
		Barnacle goose	Avian Influenza	12
			Diagnosis not listed - systemic disease	10
		Goose unspecified	Avian Influenza	2
			Diagnosis not listed - systemic disease	1
	Swan	Black swan (feral)	Avian Influenza	2
		Mute swan	Adverse environment	1
			Amyloidosis	4
			Avian Influenza	102
			Botulism	2
			Coccidiosis	1
			Egg peritonitis/salpingitis complex	2
			Fungal Infections	2
			Haemoparasitic infection	4
			Helminthosis	3
			Intestinal Torsion	1
			Malnutrition	2
			Neoplasm	1
			Nephrosis / nephropathy	1
			Peritonitis of wild waterbirds - aetiology unknown	5
			Pneumonia or airsacculitis, mycotic	2
			Poisoning dt lead	2
			Pseudomonas infection NOS	1
			Salmonellosis dt S. Typhimurium	2
			Trauma: Predation	4
			Trauma: Road Traffic Accident	3

Animal Subcategory	Group	Common Name	Diagnosis Description	Number of Diagnoses Made
			Trauma/fracture	17
			Tuberculosis	1
			Urolithiasis	1
			Diagnosis not listed - circulatory disease	2
			Diagnosis not listed - digestive disease	7
			Diagnosis not listed - reproductive disease (other than foetopathy)	1
			Diagnosis not listed - skin disease	1
			Diagnosis not listed - systemic disease	16
			Diagnosis not listed - urinary disease	1
		Whooper swan	Peritonitis of wild waterbirds - aetiology unknown	1
			Trauma: Road Traffic Accident	1
			Trauma/fracture	3
			Diagnosis not listed - systemic disease	2
		Swan unspecified	Avian Influenza	4
			Trauma/fracture	1
			Diagnosis not listed - systemic disease	1
Unknown	Mixed Bird	Mixed birds	Avian Influenza	1
			Trauma: Predation	1

Table 9: number of VIDA diagnoses in amphibians and reptiles by species

Animal Category	Group	Common Name	Diagnosis Description	Number of Diagnoses Made
Amphibian	Frog	Common frog	Malnutrition NOS	2
			Ranavirus-associated disease of amphibians	3
			Visceral parasitism	3
	Newt	Great crested newt	Trauma: Predation	2
	Toad	Common toad	Diagnosis not listed - digestive disease	1
Reptile	Snake	Adder	Trauma: Predation	2
			Trauma: Road Traffic Accident	1
		Aesculapian snake	Trauma: Predation	1
		Grass snake	Trauma: Road Traffic Accident	2
			Trauma/fracture NOS	1



© Crown copyright 2022

The material in this report has been compiled by the Animal and Plant Health Agency (APHA) Surveillance Intelligence Unit in collaboration with the APHA Surveillance and Laboratory Services Department.

The report is available on GOV.UK at:

<https://www.gov.uk/government/collections/animal-disease-surveillance-reports>.

You may re-use information from the report (excluding logos) free of charge in any format or medium, under the terms of the Open Government Licence v.3. The licence can be reviewed on GOV.UK at:

www.nationalarchives.gov.uk/doc/open-government-licence/version/3/ or by emailing PSI@nationalarchives.gsi.gov.uk.

Images are governed by Crown Copyright except where specifically acknowledged to have been provided by others external to APHA. This does not include the use of the APHA logo which should be excluded, or only used after permission has been obtained from APHA Corporate Communications, who can be contacted by emailing apha.corporatecommunications@apha.gov.uk.

Any enquiries regarding this report should be sent to APHA's Surveillance Intelligence Unit by emailing SIU@apha.gov.uk.

More information about scanning surveillance reports is available on APHA's Vet Gateway at <http://apha.defra.gov.uk/vet-gateway/surveillance/index.htm>.

APHA is an executive agency of the Department for Environment, Food & Rural Affairs, and also works on behalf of the Scottish Government and Welsh Government.