




Animal &
Plant Health
Agency



GB cattle quarterly report

Disease surveillance and emerging threats

Volume 26: Q1 – January-March 2020

Highlights

- Rupture of the cranial mesenteric/coeliac artery in dairy cows – page 5
- Vertebral malformation in a dairy calf – page 7
- Type II Ostertagiosis in housed heifers – page 11

Contents

Introduction and overview	1
New and re-emerging diseases and threats	4
Unusual diagnoses	5
Changes in disease patterns and risk factors	10
Horizon scanning	14
References	15

Editor: Gareth Hateley, APHA Lasswade
Phone: + 44 (0) 208 565 4357
Email: gareth.hateley@apha.gov.uk

Introduction and overview

This quarterly report reviews disease trends and disease threats for the first quarter of 2020, January- March. It contains analyses carried out on disease data gathered from APHA, SRUC Veterinary Services division of Scotland's Rural College (SRUC) and partner postmortem providers and intelligence gathered through the Cattle Expert Group networks. In addition, links to other sources of information including reports from other parts of the APHA and Defra agencies are included. A full explanation of how data is analysed is provided in the annexe available on GOV.UK

<https://www.gov.uk/government/publications/information-on-data-analysis>

Issues and trends

Covid19

On 23rd March 2020 the Prime Minister announced that the UK would be placed in "lockdown" due to the global Covid19 pandemic. This required all non-essential workers to stay at home and social distancing measure that required people to keep a distance of 2 metres from each other. Farmers and veterinarians were identified as key workers but the social distancing rule impacted on the way veterinary services could be delivered and risk assessments were applied to consider what activities could continue safely. Welfare of animals was key and many essential tasks continued, for example assistance during calving. However, routine work considered as non-essential ceased, for example routine non-statutory herd health blood sampling, where social distancing was impossible.

APHA took all reasonable preventative measures in view of the current Covid19 situation and developed contingency plans in place to manage services across the network during the outbreak. APHA continues to provide a diagnostic service for livestock through carcasses submitted for postmortem examination and from samples submitted by post for diagnostic testing and vets were reminded to contact their local site as directed by the postcode finder: <http://apha.defra.gov.uk/postcode/pme.asp>

The contingency plans enabled continued provision of postmortem services across our network of VIC's and partner providers. In the event of a postmortem site (either APHA Veterinary Investigation Centre or one of our partner provider sites) being unable to receive carcase material due to staff being unavailable, APHA will make arrangements to transport carcasses to an alternative site using the free carcase collection service.

Submissions to all laboratories have been reduced as a consequence of restrictions but APHA has continued to receive abortion submissions throughout the spring calving period.

Weather

During the first quarter of 2020 two features stand out. The mean rainfall for the quarter was close to the thirty year average, but with wide variation across the months. January and March were drier than average (Figure 1), but February was one of the wettest months on record, with three storms (Ciara, Dennis and Jorge) leading to high rainfall, winds, travel disruption, and some significant flooding of both arable and grazing land.

APHA published a focus article to raise awareness of potential medium (once flood waters have receded) and longer-term (when land and buildings have come back into use) livestock endemic disease risks associated with flooding events in Great Britain. See <https://veterinaryrecord.bmj.com/content/186/9/275.full?ijkey=5cgMW.N/Z7FOg&keytype=ref&siteid=bmjournals>

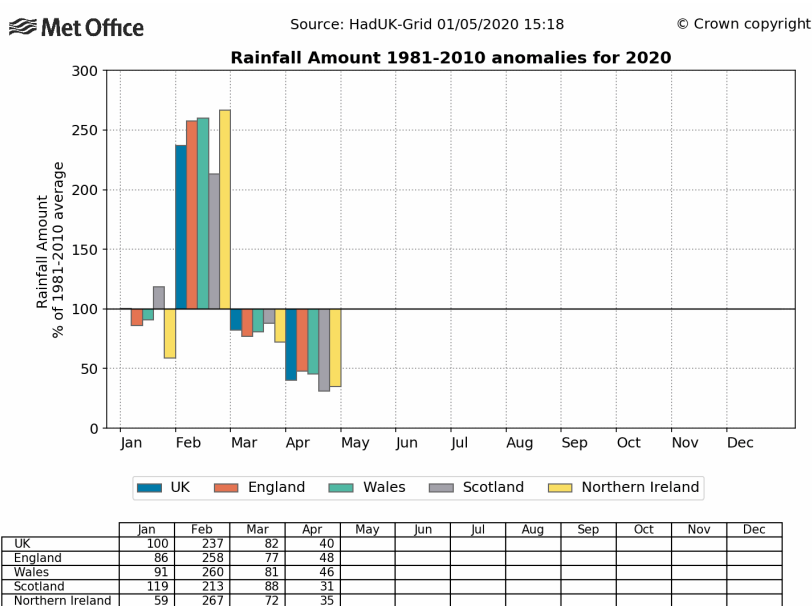
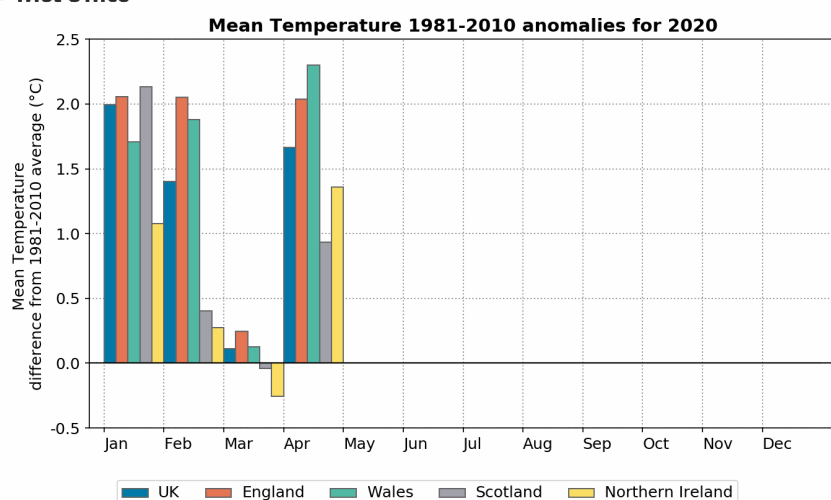


Figure 1: Rainfall by month and region, Q1 2020 compared with the 1981-2010 average (Met Office)



	Jan	Feb	Mar	Apr	May	Jun	Jul	Aug	Sep	Oct	Nov	Dec
UK	2.0	1.4	0.1	1.7								
England	2.1	2.1	0.2	2.0								
Wales	1.7	1.9	0.1	2.3								
Scotland	2.1	0.4	-0.0	0.9								
Northern Ireland	1.1	0.3	-0.3	1.4								

Figure 2: Mean temperature by month and region, Q1 2020 compared with the 1981-2010 average (Met Office)

Such factors, especially the increasing mean temperature, have the potential to influence endemic disease impact- for example, the survival of endoparasite larvae overwintering on pasture.

Dairy

The impact of the Covid 19 pandemic has had a profound effect on the UK dairy supply chain with significant variation experienced on farm depending on the milk contract. Some liquid milk supply contracts have been hit the hardest compared to those supplying cheese contracts with a divergence of over 10p/L between the best and worst contracts in the UK. Liquid milk contracts supplying the catering and restaurant trade have been particularly hard hit as a result of the national lock down. At the time of writing spot milk prices have now recovered to around 16-18p/L from a low of between 5-10p /L at the start of lock down, both well below the cost of production. Some milk buyers have asked farmers to reduce the amount of milk produced or picked up ex-farm and this poses a particular challenge to farmers at this time of year when there is a spring flush of milk, and this has led in some cases to disposal of milk. Potentially for a range of reasons one of the observed findings at the time of writing is that the spring flush of milk was below the 2019-20 level or predictions for the current year. Many of the suggested ways of reducing milk output have consequences for cow health and herd performance and may affect the ability of a herd to return to normal production in the future once supply chain issues ease. For example, reducing feed levels to high yielders can increase the risk of metabolic disease and have a consequential effect on fertility. Feeding more whole milk to calves can increase the risk of infectious disease spread such as Johne's disease or *Mycoplasma*

bovis. Defra recently announced a hardship fund for dairy farmers hardest hit by coronavirus.

Feedback from practitioners and through the British Cattle Veterinary Association suggested that farm vet contact with dairy herds, particularly for routine visits and dealing with sick cows, has been maintained with appropriate social distancing through lockdown and this should not have compromised surveillance. Perhaps of greater concern for surveillance is the financial viability of some dairy farm businesses under the current circumstances and the need to cut costs which might include veterinary spend.

Colin Mason, SRUC

Beef

Prime cattle prices unsurprisingly started the year substantially below 5-year averages, but did hold ground at around 331ppKg deadweight in the early weeks (around 20p behind 5-year average). Carcase weights were generally higher than previous years, thought to be due to better quality and quantity of forage made, and the mild winter weather. January also saw reduced imports (down 12% from Ireland year-on-year) and increased exports (20% higher than Jan 2019), and this will have helped support increased prices continuing through most of the quarter, ending at around 336ppKg deadweight.

Various market reports started looking at the impact of coronavirus at the end of quarter 1. Briefly these included dramatic increase in demand for all cuts during March (panic buying), but particularly mince (as being convenient, familiar and suitable for freezing). Closure of food outlets and fast-food chains had a negative effect on both cull-cow demand (burgers) and demand for top cuts. There are multiple cuts from a carcase that yield a substantially higher value if they avoid going into the mincer (like flat brisket, chuck roll and silverside) and so the main concern was that if these cuts are minced to match demand, that would have a significantly negative effect on carcase value. There was also a significant drop in demand for hides as general manufacturing reduced, with a fear that these would lose all market value and become a disposal cost. Cattle prices fell across the board in the first week of April. Markets remained open through online trading.

A report looking at store animal prices over 2019 found prices reduced by around 20-30% in young animals, but much less so in 2 year olds, where prices were only reduced 2-8%. It is interesting that the store market does not strictly follow the dead-weight price.

Tim Geraghty, SRUC

New and re-emerging diseases and threats

Please refer to the annexe on GOV.UK for more information on the data and analysis.

Unusual diagnoses

Primary neoplasia of the brain of a yearling

Three dairy heifers in a group of 150 were reported to have developed signs of nervous disease which were considered suggestive of listeriosis. The heifers in the herd of 200 adult cows were fed only silage. The first two animals were not investigated, the third failed to respond to antibiotics and was euthanased using barbiturate and submitted for postmortem examination. Prior to being euthanased it had become blind and was considered to be aggressive. Other than the impression of an increased amount of cerebrospinal fluid which was slightly opaque, there was no gross pathology in the brain or other organs. Selective cultures did not isolate *Listeria monocytogenes*. Sectioning the fixed brain revealed a large mass at the level of the thalamus. This was causing marked expansion of the left ventricle and compression of the right ventricle (Figure 3).

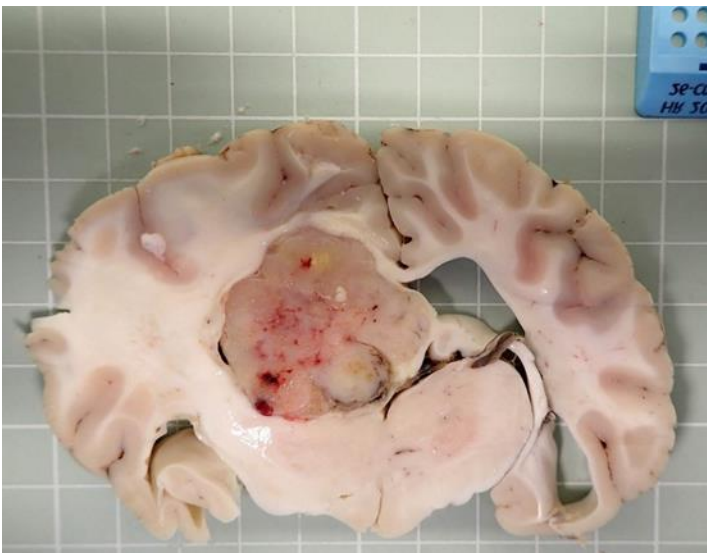


Figure 3: Section showing large nodular neoplastic mass at the level of the thalamus causing compression of the left and expansion of the right ventricles

Histopathology confirmed the mass to be a neoplasm with cellular morphology suggestive of a glioblastoma. Such tumours are rarely described in cattle and would not be likely to have caused the nervous disease in the two previously affected animals.

Rupture of the cranial mesenteric/coeliac artery in dairy cows

Since 2003 deaths caused by rupture of the cranial mesenteric/coeliac artery have been identified by postmortem examinations of dairy cows in the surveillance networks in the UK and Ireland (Crawshaw and others 2009), with a similar increasing trend in North America and the Netherlands. The cows were all Holstein-Friesian breed, in several herds and there was not a high within herd prevalence. The cause for the development of aneurysms leading to rupture is unclear. Given the association with Holstein-Friesians, a hereditary association was suspected. Tests ruled out copper deficiency, which has been associated

with aneurysm formation in some species. Bovine Marfan Syndrome (Potter and Besser 1994) and Ehlers-Danlos Syndrome (Uri and others 2015), which are inherited conditions with defective metabolism of connective tissue, were also considered.

A recent investigation was undertaken into the unexpected deaths of six cows in a dairy herd of 120 cows, the losses occurring over the last 4 years. A seventh cow died and was examined postmortem, which revealed extensive abdominal haemorrhage with large blood clots adhered around the cranial mesenteric/coeliac artery. Detailed investigation confirmed rupture of the vessel and other tears in the intima and media (Figure 4).

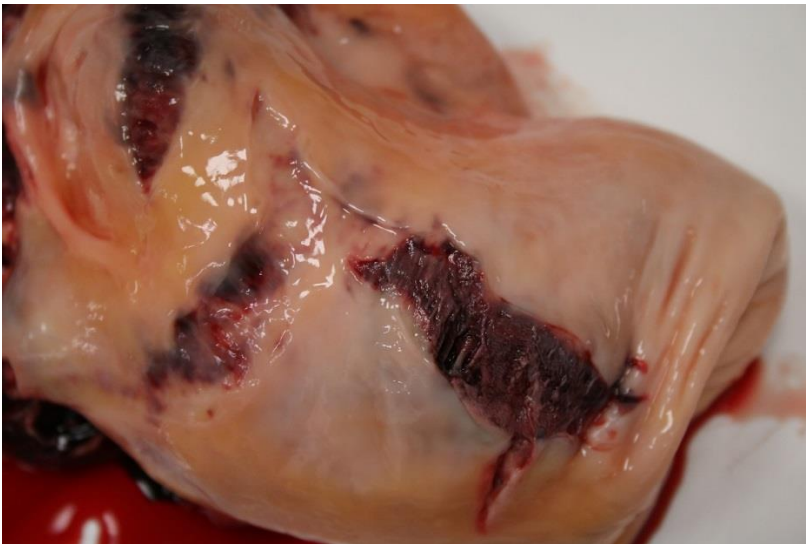


Figure 4: Cranial mesenteric artery opened showing intimal and media tears

Five of the previous deaths on the farm had also been examined postmortem by the practitioners with similar findings. An eighth cow died a few days later, however this animal had severe multifocal hepatic abscessation and thromboembolic lung pathology.

The affected herd comprised solely Holstein cows until about four years ago; since then cross breeding has resulted in half the herd being Holstein/Norwegian Reds, and all the affected animals have been this type.

Further investigation was undertaken with the practitioners.

Several possible risk factors were identified which may have caused the high within-herd prevalence and should be addressed:

- The breed of cows i.e. Holstein/Norwegian Red: unfortunately the records were not sufficiently detailed to be able to determine if specific cow/bull combinations were those which had been affected
- The condition of the cows: the cow examined postmortem with arterial rupture was in fat condition weighing 818kg, while other cows in the herd, notably the crossbreds, had the highest body conditions

- The diet: a nutritionist advised on the farm's diet formulation, but it is suspected that it is suited to Holstein production rather than the Holstein-crossbreds, and is affecting cow condition
- Cow fitness: all the deaths occurred during the housed winter months when cows exercise least.

Vertebral malformation in a dairy calf

It was reported that four calves of 180 calvings to date, in a seasonal calving dairy herd of 1350 cows, were born alive but with skeletal defects. They were unable to stand and had abnormal angulation of the limbs. Bulk milk sample monitoring for Schmallenberg virus and surveillance monitoring for BVD had not demonstrated presence of either infection. The fourth affected calf was submitted for postmortem examination. Each of the four limbs was abnormal. None of the joints of either of the forelimbs could be fully straightened and they had very limited flexion. The left forelimb was abducted at the shoulder/elbow joints. Both hind legs were extended with ankylosis of the hip, stifle and hock joints. The left hind fetlock was ankylosed in hyperextended position, the right hind fetlock was ankylosed in flexion. The neck was markedly twisted to the left and along the long axis of the spine (Figure 5).



Figure 5: Twisting, abnormal angulation and ankylosis of the joints of all four limbs and the neck of a dairy calf

The first five cervical vertebrae were fused together and to the skull which had hyperplastic bone development in the caudal cranium. The vertebral canal in the cranial cervical region was markedly twisted though minimally narrowed, with a normal vertebral canal from the lower cervical spine extending caudally (Figure 6). The brain and spinal cord were grossly unremarkable.



Figure 6: Dorsal cervical vertebral arches and spines removed to show marked deformity of the upper cervical vertebrae

Although this calf had ankylosed limbs, resembling calves born with arthrogryposis caused by Schmallerberg virus infection, in this case the fused skull and cranial cervical vertebrae were considered likely to be the most significant lesion and account for the limb ankylosis. The brain and spinal cord were grossly unremarkable unlike in cases of Schmallerberg virus infection where there is cavitation of the brain and much reduced size of spinal cord. Tests for Schmallerberg virus infection, including histopathology of the brain and spinal cord, ruled out the viral infection. Further examination of the affected cervical vertebrae indicated partial or total absence of the intervertebral discs and the epiphyses were reduced in size. The findings indicated lesions similar to the Complex Vertebral Malformation of Holstein-Friesians. The cause in this case was unclear: teratogens, genetic or possibly trace element deficiencies were possible causes; however, there was no evidence of any of these potential insults affecting the herd. Since this submission, no further affected calves have been reported.

Myocardial abscessation causing heart failure in an adult dairy cow

An adult dairy cow was presented for examination, being the third animal to die in a two week period, in a herd of 160 adult milking cows. The cow had been seen breathing heavily and grunting the evening before it was found dead, and had calved in October. The liver was firmer than normal and an abscess was present between the liver and the omasum. The left side lung lobes were oedematous, though the right side lung was normal. The heart was enlarged, especially the left ventricle, with a large non-encapsulated abscessated area within the ventricular wall (Figure 7).

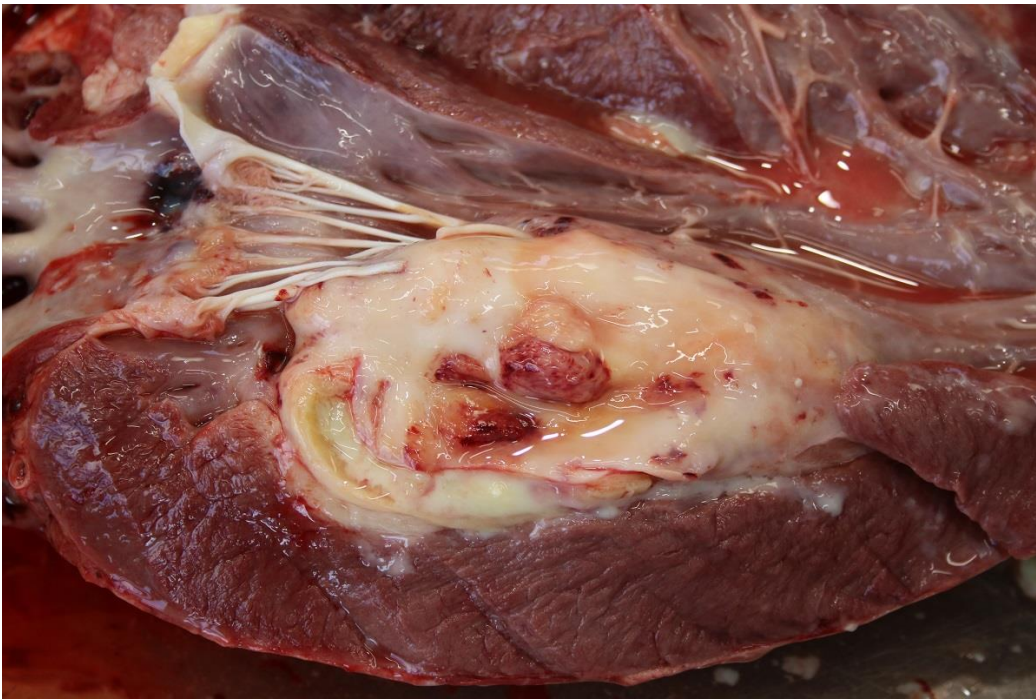

Figure 7: Large non-encapsulated area of abscessation within the left ventricular wall of the heart of a dairy cow

The heart valves were unaffected. Marked haemorrhage was also present at the base of the pulmonary artery and aorta. A lymphoplasmacytic hepatitis was confirmed by histopathology with no specific pathogenic bacteria isolated from the abscessated areas. The conclusion was that the abscesses in the heart and between the omasum and liver were sequelae to previous bacteraemia, or possibly a penetrating foreign body such as a wire, and probably accounted for the grunting heard the day before the animal died. The actual cause of death was presumed to be due to compromised heart function caused by the myocardial lesion.

Fungal abortion

The most common fungus species causing bovine abortion in the UK is *Aspergillus fumigatus*; however, many other fungi are sporadically identified. *Scedosporium apiospermum*, a fungus which is commonly found in the soil, was identified as the cause of abortion of a dairy cow which was due to calve in two months. The submission was from a dairy herd with 200 breeding cows, in which one abortion a month was reported for the previous six months. An aborted calf with a small piece of placenta was received. No gross pathology was identified in the placenta. The calf was very well developed weighing 46 kg. It had multiple rounded coalescing plaques, approximately 4 to 10 mm thick, over the entire skin surface (Figure 8), and there was fibrinous exudate within the thoracic and abdominal cavities. Histopathological examination confirmed a necrosuppurative epidermitis with pustule and crust formation and intralesional fungal hyphae, a necrotising hepatitis, and a mild pneumonia. Fungal abortion was confirmed by PAS staining of skin sections, which allowed the identification of fungal hyphae and conidia with a morphology

consistent with *Scedosporium apiospermum* which was isolated in pure culture from the stomach contents.



Figure 8: Skin lesions on an aborted calf caused by infection by the fungus *Scedosporium apiospermum*

Changes in disease patterns and risk factors

Please refer to the annexe on GOV.UK for more information on the data and analysis.

Enteric system

The Salmonella in Livestock Production in GB 2018 has been published on GOV.UK.

<https://www.gov.uk/government/publications/salmonella-in-livestock-production-in-great-britain>

Severe Summer Scour Syndrome (SSSS)

Two cases of suspected Summer Scour Syndrome from southwest England were investigated in July 2019. These were reported in the Q3 2019 report.

The Cattle Expert Group are continuing the project into the 2020 grazing season and are keen to hear from colleagues in practice who suspect the condition. Please discuss in the first instance with your local surveillance provider.

Type II Ostertagiosis in housed heifers

Two dairy heifers were examined postmortem from an organic dairy herd with 220 adult cows. Four other heifers had died in the preceding three to four weeks, in two housed groups each of around 40 animals aged between 12 and 20 months. The first animal examined was 18-months-old and was in poor condition, weighing only 232 kg. Its abdomen was distended, with a large amount of fairly dry forage in the rumen. The abomasum was dilated and contained concentrate and forage. Although the mucosa was autolysing, marked nodular thickening and inflammation was identifiable and there were also several ulcers (Figure 9). A worm egg count identified only 150 trichostrongyle eggs per gram in soft consistency faeces; however, histopathology confirmed a severe diffuse proliferative abomasitis with intralesional nematodes, consistent with a diagnosis of type II ostertagiosis. The second animal had died a few days later, after the heifers had been treated with an ivermectin. This animal was about 14 months old and was also in poor condition, with only mild abomasal lesions, though it had oral ulceration on the gums, at the edge of the hard pad and at the side of the tongue, and its gastric and mesenteric lymph nodes were very enlarged. BVD was ruled out in both animals.

Parasitic gastroenteritis is more usually diagnosed in the summer and autumn months, in animals at pasture or which have recently been housed. The history in this case, and the pathological findings in the two animals, indicate acquisition of a parasite burden during last year's grazing season. In the case of the older heifer the larvae ingested in the autumn underwent arrested development within the abomasal mucosa, and subsequently re-emerged in large numbers earlier this year to cause the severe abomasitis characteristic of type II ostertagiosis. Affected animals often have profuse diarrhoea, weight loss and die.

The findings indicate the need for an effective grazing and parasite monitoring plan ahead of the forthcoming grazing season, which is especially important for young stock in their first season at grass. It was recommended that the animals be monitored for weight gain, and for worm burdens by faecal examinations for parasite eggs. Screening faeces samples for fluke eggs is also advisable in such investigations. If significant parasitic burdens are identified appropriate treatments can be used in organic farming and the health plan updated. Advice on endoparasitism, grazing management and the effective use of anthelmintics, is available at <https://www.cattleparasites.org.uk/>.

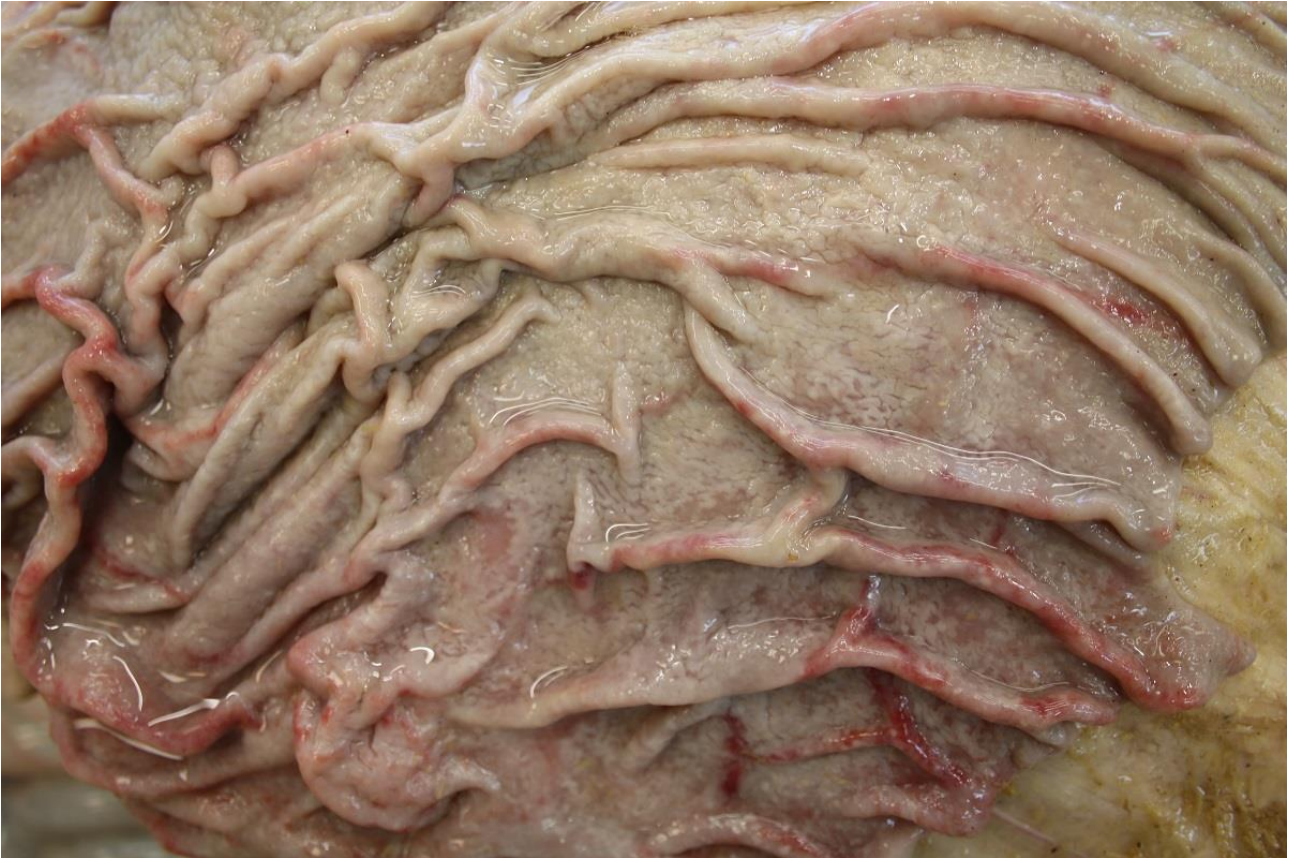

Figure 9: Marked nodular mucosal thickening and inflammation of the abomasum of a dairy heifer with type II ostertagiosis

Rotavirus

There was a notable increase in Q1 2020 compared with recent years of diagnoses of rotavirus expressed as a % of diagnosable submissions (Figure 10). Although not statistically significant this will be monitored in case it is the beginning of an upward trend. Q1 is usually the quarter in which the highest number of diagnoses are made, as the winter housing period comes to a close and infection pressure builds up.

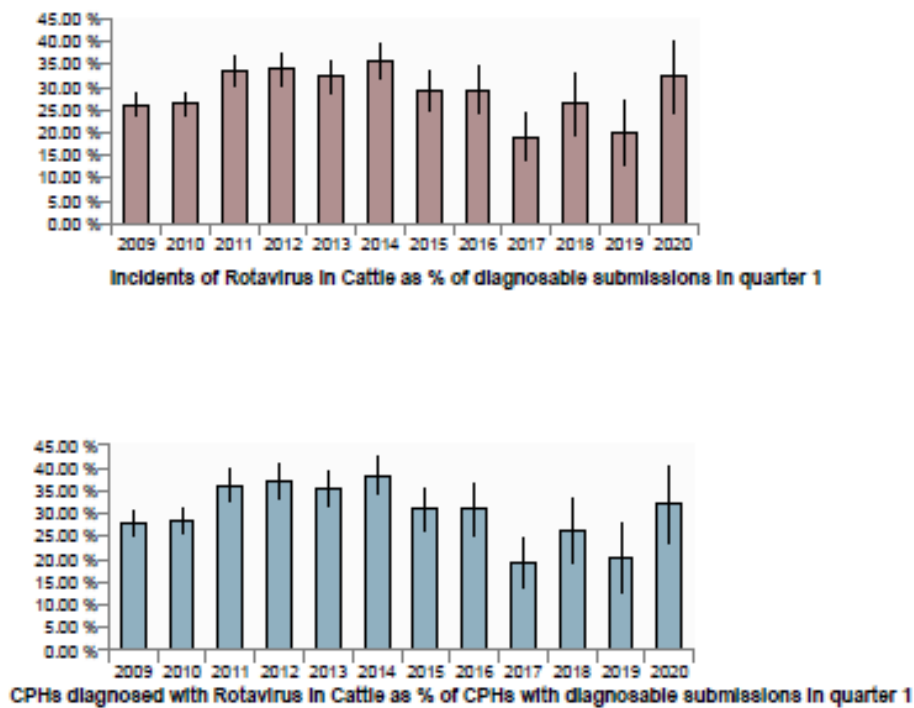


Figure 10: Diagnoses of rotavirus as % of diagnosable submissions, Q1 2009-2020 (incidents above, CPHs below)

Respiratory system

A continuing upward trend has been seen in the number of diagnoses of pneumonia due to *Pasteurella multocida* (Figure 11) and RSV (Figure 12). Both pathogens were generally isolated as part of the bovine respiratory disease complex, although occasionally each was the only pathogen identified. Data analysis has showed that, for *Pasteurella multocida*, the increase was based on more cases detected in pre and post-weaned calves, mainly in herds located in Scotland and the north of England. For RSV, the north of England and Wales have seen a prominent increase in percentage of diagnosable submissions, particularly in pre-weaned dairy calves.

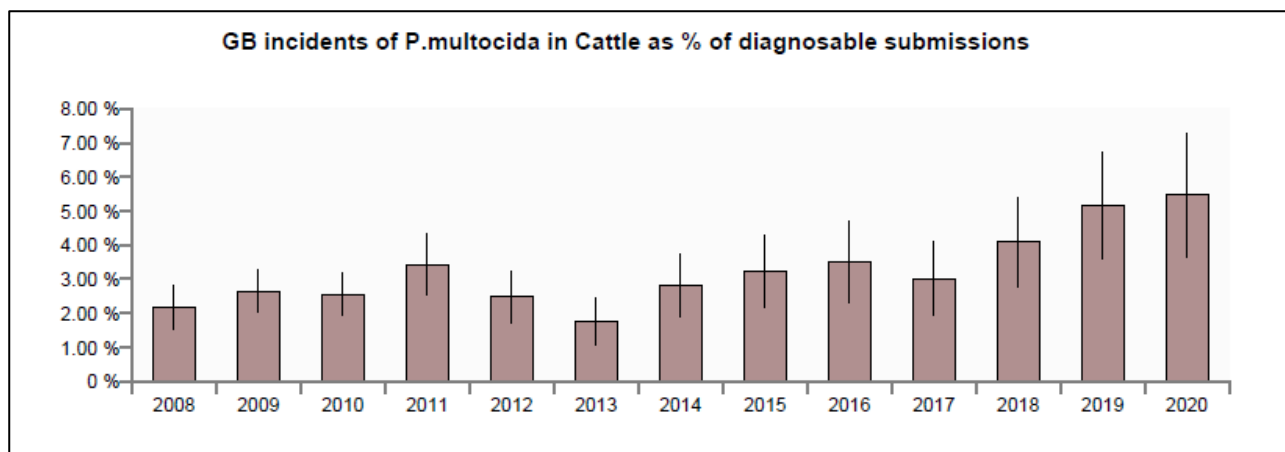


Figure 11: GB incidents of *Pasteurella multocida* in cattle as % diagnosable submissions, Q 1 2008-2020

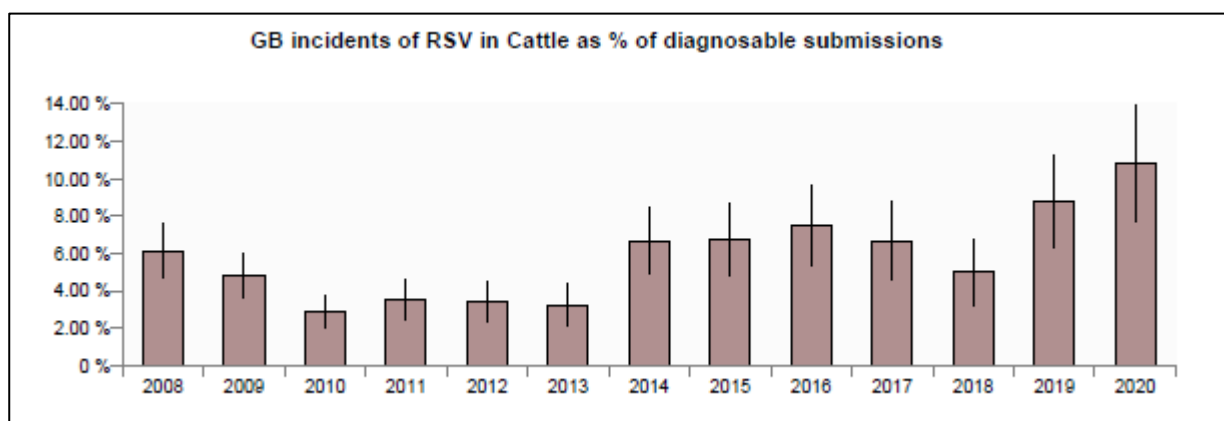


Figure 12: GB incidents of RSV in cattle as % diagnosable submissions, Q 1 2008-2020

Horizon scanning

Bluetongue (BTV) update

The risk of introduction of BTV to the UK remains low.

For more information, see the updated situation assessment, at:

<https://www.gov.uk/government/publications/bluetongue-virus-in-europe>

In April, there were 2 outbreaks of BTV in Greece (BTV-4 in sheep, and BTV-16 in cattle). There were no other reports elsewhere.

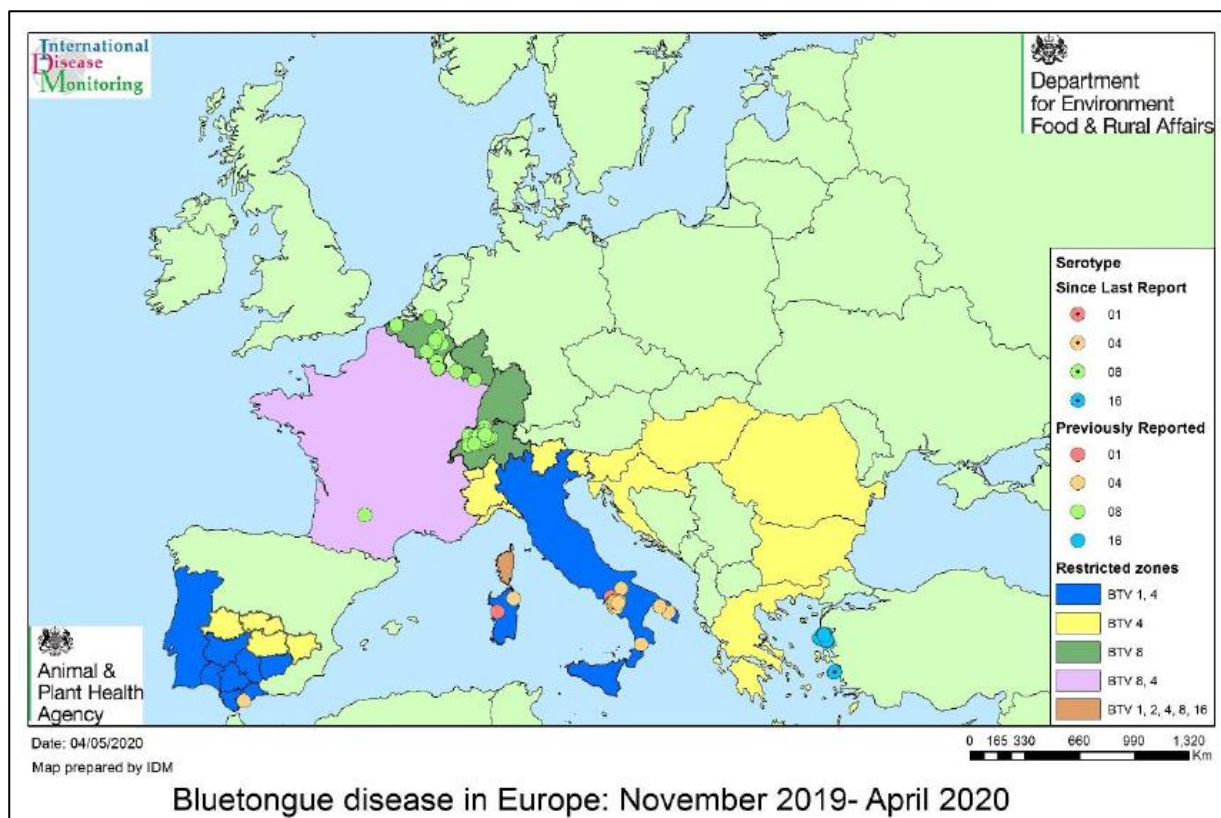


Figure 13: Bluetongue disease in Europe November 2019 – April 2020

Chemical food safety

The latest Chemical Food Safety report can be found at this link:

<https://www.gov.uk/government/publications/chemical-food-safety-reports>

References

Crawshaw T, Wessels M, Howie F, *et al.* Idiopathic arterial aneurysm/rupture causing sudden death in dairy cattle. *Veterinary Record* 2011;**169**: 261

Potter KA, and Besser, TE. Cardiovascular lesions in bovine Marfan syndrome. *Veterinary Pathology* 1994;**31**: 501-509

Uri M, Verin R, Ressel L, *et al.* Ehlers-Danlos syndrome associated with fatal spontaneous vascular rupture in a dog. *Journal of Comparative Pathology* 2015;**152**: 211-216



© Crown copyright 2020

Statement regarding use of this material

The material in this report has been compiled by the Animal and Plant Health Agency (APHA) Surveillance Intelligence Unit in collaboration with the APHA Surveillance and Laboratory Services Department. Images are governed by Crown Copyright except where specifically acknowledged to have been provided by others external to APHA. Use of material directly from the report is acceptable provided APHA (or others where specifically indicated) is acknowledged as the owner of the material. This does not include use of the APHA logo which should be excluded, or used only after permission has been obtained from APHA Corporate Communications (apha.corporatecommunications@apha.gov.uk).

You may re-use this information (excluding logos) free of charge in any format or medium, under the terms of the Open Government Licence v.3. To view this licence visit www.nationalarchives.gov.uk/doc/open-government-licence/version/3/ or email PSI@nationalarchives.gsi.gov.uk

This publication is available at <https://www.gov.uk/government/collections/animal-disease-surveillance-reports>

Any enquiries regarding this publication should be sent to us at SIU@apha.gov.uk

<http://apha.defra.gov.uk/vet-gateway/surveillance/index.htm>

The Animal and Plant Health Agency (APHA) is an executive agency of the Department for Environment, Food & Rural Affairs, and also works on behalf of the Scottish Government and Welsh Government.