

**GUIDELINES FOR NON-OPERATIVE  
DIAGNOSTIC PROCEDURES AND REPORTING  
IN BREAST CANCER SCREENING**

**Non-operative Diagnosis Subgroup of the National  
Coordinating Group for Breast Screening Pathology**

**NHSBSP Publication No 50  
June 2001**

Archived on 22/03/2017

First published by:

NHS Cancer Screening Programmes  
The Manor House  
260 Ecclesall Road South  
Sheffield S11 9PS

Tel: 0114 271 1060

Fax: 0114 271 1089

Email: [nhs.screening@sheffield-ha.nhs.uk](mailto:nhs.screening@sheffield-ha.nhs.uk)

Web site: [www.cancerscreening.nhs.uk](http://www.cancerscreening.nhs.uk)

© NHS Cancer Screening Programmes 2001

The contents of this document may be copied for use by staff working in the public sector but may not be copied for any other purpose without prior permission from the NHS Cancer Screening Programmes.

ISBN 1 871997 44 5

Archived on 22/03/2017

## CONTENTS

	Page No
1. USE OF NON-OPERATIVE DIAGNOSTIC TECHNIQUES	1
1.1 Role of non-operative diagnostic techniques	1
1.2 Choice of sampling technique – FNAC or core biopsy	2
1.3 False positive cytology	4
1.4 Resource implications	4
2. SAMPLING TECHNIQUES AND PROCEDURES	6
2.1 Sampling techniques	6
2.2 Use of image guidance for breast biopsy	6
2.3 Fine needle aspiration cytology (FNAC)	7
2.4 Core biopsy	13
2.5 Large volume sampling techniques	15
2.6 Complications of FNAC and WBN	16
3. FNAC REPORTING GUIDELINES	18
3.1 Using the cytopathology reporting form	18
3.2 Recording basic information	19
3.3 Reporting categories	20
3.4 Calcification in FNAC	23
3.5 General diagnostic patterns	23
4. DIAGNOSTIC PITFALLS IN INTERPRETATION OF BREAST FNAC	24
4.1 Common conditions resulting in a false positive diagnosis	24
4.2 Uncommon lesions causing a false positive diagnosis	28
4.3 Conditions causing a false negative diagnosis	28
4.4 Other unusual lesions	30
4.5 Prognostic information	31
5. CORE BIOPSY REPORTING GUIDELINES	32
5.1 Core biopsy specimen information and handling	32
5.2 Using the core biopsy (WBN) reporting form	32
5.3 Recording basic information	33
5.4 Reporting categories	35
5.5 Calcification in core biopsy	40
5.6 Problems and pitfalls in diagnosis	40
5.7 Rare lesions	43
5.8 Assessment of prognostic information	44
5.9 Oestrogen receptor (ER) assessment	45

	Page No
6. QUALITY ASSURANCE	46
6.1 Definitions	46
6.2 How to calculate quality assurance statistics	46
6.3 Cytology performance figures	48
6.4 How to interpret the results	48
6.5 Education and training	51
APPENDICES	
1: How the national screening system treats cytology data	52
2: Immunohistochemical detection of steroid receptors in breast cancer	54
REFERENCES	57

Archived on 22/03/2017

## WRITING GROUP

**Dr I O Ellis** Reader in Pathology  
University of Nottingham  
Department of Histopathology  
Nottingham City Hospital  
Hucknall Road  
Nottingham NG5 1PB

**Dr S Humphreys** Consultant Pathologist  
Preston Hall Hospital  
Maidstone  
ME20 7NH

**Dr M Michell** Consultant Radiologist  
King's College Hospital  
London SE5 9PS

**Dr S E Pinder** Senior Lecturer  
University of Nottingham  
Department of Histopathology  
Nottingham City Hospital  
Hucknall Road  
Nottingham NG5 1PB

**Dr C A Wells** Consultant Pathologist  
St Bartholomew's Hospital  
West Smithfield  
London EC1A 7BE

**Dr H D Zakhour** Consultant Pathologist  
Department of Histopathology  
Arrowe Park Hospital  
Arrowe Park Road  
Upton  
Wirral CH49 5PE

## PREFACE

In 1989, a working party of the Royal College of Pathologists produced two documents giving guidance on breast cancer screening as it related to histopathology.<sup>1,2</sup> Subsequently, the National Coordinating Committee for Breast Cancer Screening Pathology published guidelines for cytology procedures and reporting in breast cancer screening.<sup>3</sup> These guidelines have essentially been adopted with minor modifications by the European Union (EU) and form the basis of the European guidelines.<sup>4</sup> In addition, the 1989 guidelines have been updated in two revised documents.<sup>5,6</sup>

Non-operative diagnosis has become the norm in breast screening assessment. Until now, fine needle aspiration cytology (FNAC) has been the sampling method of choice, but the more recent introduction of automated core biopsy guns, which facilitate sampling, has led to the implementation of core biopsy in assessment units.

The purpose of this document is to update pathologists on the role and use of FNAC and core biopsy in breast screening assessment. It also details the mechanisms used to assure the quality of cytological and core biopsy diagnosis.

The document constitutes the second edition of guidelines for cytology procedures and reporting in breast cancer screening. It updates and replaces the previous guidelines published as NHSBSP Publication No 22.<sup>3</sup>

## 1. USE OF NON-OPERATIVE DIAGNOSTIC TECHNIQUES

### 1.1 Role of non-operative diagnostic techniques

The role of non-operative diagnosis in malignancy is to attempt to provide a definitive diagnosis that allows rapid referral for treatment, ideally in one operative procedure. Definitive non-operative diagnosis of benign conditions is also useful, leading to discharge from the clinic and return to routine recall. There is a cost to be weighed against the benefits expected from non-operative diagnosis, and a cost-benefit table can be drawn (Table 1).

The highest levels of diagnostic accuracy in the non-operative diagnosis of breast disease are achieved by using a triple approach,<sup>7</sup> which combines the results of imaging and clinical examination with fine needle aspiration cytology (FNAC) and/or core biopsy. When the results of all three modalities agree, the level of diagnostic accuracy exceeds 99%.<sup>8</sup> It is of interest to note that similar levels of accuracy have been obtained in the case of impalpable lesions, in which clinical examination is non-contributory.<sup>9</sup>

Detailed guidance on assessment procedures is provided in the companion NHS Breast Screening Programme (NHSBSP) guidelines *Clinical Guidelines for Breast Cancer Screening Assessment*.<sup>10</sup> All patients should undergo a thorough work-up including imaging and clinical examination prior to FNAC and/or core biopsy. The imaging characteristics of suspicious lesions are demonstrated using special views, including fine focus magnification views for microcalcifications and spot compression views and ultrasound examination for mass lesions. The imaging features of mammographically detected abnormalities are assessed to determine the probability of malignancy. This information, together with the result of clinical examination, must be considered with the results of FNAC or core biopsy at the multidisciplinary meeting

**Table 1** Comparison of non-operative techniques and open surgical biopsy

Benefits	Drawbacks
Diagnosis with simple tests	Error in diagnosis may lead to overtreatment or delay in making the correct diagnosis
Cheap compared with open biopsy	Occasional complications (see section 2.6 )
Avoids open biopsy in some cases and allows treatment of cancers at a planned operation	Requires skilled personnel
Can be performed as an outpatient procedure	Entails additional cost in terms of training and employment of skilled personnel
Avoids frozen section	
Reduces patient uncertainty and therefore anxiety	
Low complication rate compared with other diagnostic tests	

when deciding further management. This combined approach must be adhered to in the UK National Breast Screening Programme. Under no circumstances should a cytological opinion of malignancy in the absence of mammographic and/or clinical evidence of malignancy be taken as authority for therapeutic surgery. It is recognised that false positive core biopsy interpretation occasionally occurs, and all cases should be subject to multidisciplinary review before definitive treatment.

Cytology and core biopsy results from impalpable lesions should not be interpreted in isolation. Inevitably, inadequate and false negative results are significantly higher for impalpable lesions. When the imaging findings are considered to be strongly suspicious of malignancy, and FNAC or core biopsy is inadequate, normal, or benign, then management should be based on the imaging findings. The case should be reviewed at a multidisciplinary meeting and a decision made as to whether to repeat the sampling procedure or to refer the subject for open biopsy or localisation biopsy. If the initial sampling procedure was FNAC then consideration should be given to the use of core biopsy as the repeat procedure. In cases where there is disagreement between modalities with a failure to achieve consensus after multidisciplinary discussion, diagnostic histopathological biopsy is the appropriate procedure. **Frozen section for the diagnosis of screen-detected lesions is inappropriate.**

### 1.2 Choice of sampling technique – FNAC or core biopsy

The benefits and drawbacks of core biopsy compared with FNAC are shown in Table 2.

**Table 2** Benefits and drawbacks of core biopsy compared with FNAC

<b>Benefits</b>	<b>Drawbacks</b>
Able to characterise lesions more completely and can provide a definitive diagnosis in a higher proportion of cases	Biopsy procedure more time-consuming
May differentiate between invasive and in situ carcinoma	Tissue processing takes more time therefore immediate diagnosis is not possible
Better characterisation of lesions associated with microcalcification	Test for test more expensive than FNAC
Assessment of grade and type of carcinoma can be achieved more easily but concordance with final grade and type not absolute	Skin incision necessary
Can more readily be used for hormone receptor analysis	Can be more traumatic
Interpretation can be provided with less specialist pathology training than required with FNAC	Specialist training required



The choice of sampling method in any centre should be determined by:

- the sensitivity and specificity of the technique in the centre
- the diagnostic information required for malignant lesions
- patient comfort
- cost
- the availability of staff skilled and experienced in using the procedures, particularly FNAC sampling and interpretation.

The number of personnel performing FNAC or core biopsy in any centre should be kept to a minimum and their performance audited as a matter of routine.

### 1.2.1 Accuracy of FNAC

The accuracy of FNAC depends on three main factors:

- a sample that is adequate and representative of the lesion
- suitable processing and staining without artefact
- accurate interpretation of the cytological material with a clear report conveyed to the rest of the clinical team.

The procedure can fail at any of the stages of preparation (aspiration, spreading and staining), even before diagnostic interpretation. The confidence and experience of the aspirator are vital for obtaining a satisfactory sample. This part of the procedure, like other parts, should not be delegated to the novice. Although FNAC has been successfully used by many centres, its effectiveness in some has been limited by inadequate and/or equivocal sample rates of 10–30%. Poor cytology specimens are more likely to be obtained from paucicellular lesions such as sclerosed fibroadenomas and microcalcification due to fibrocystic change.

### 1.2.2 Accuracy of core biopsy

The availability of automated core biopsy guns and the publication of results from several centres showing very high sensitivity and specificity have resulted in the more widespread use of image guided core biopsy. A recent review of published series of image guided breast core biopsy shows that the sensitivity and specificity of core biopsy are high when compared with FNAC.<sup>11</sup> No difference in patient discomfort between FNAC and core biopsy has been demonstrated. Information regarding the invasive nature and grade of the tumour can be obtained in most malignant mass lesions. For malignant microcalcification, if an invasive tumour is present, 14G core biopsy will detect the invasive element in approximately 40% of cases.

Recent evidence indicates that for certain types of mammographic abnormality, such as moderate to low level suspicion microcalcification, a larger volume of tissue is required for accurate diagnosis.<sup>12</sup> In the case of such lesions, when the use of conventional FNAC or 14G core biopsy carries a risk of an equivocal result, use of larger volume sampling techniques may increase the accuracy of biopsy. Recently published results of vacuum assisted core biopsy have demonstrated a lower equivocal sample rate and increased accuracy in the detection of small

invasive tumours associated with an area of ductal carcinoma in situ (DCIS). Consideration of the likely underlying histological nature of the lesion from the imaging features should therefore be taken into account when deciding on the sampling method to be used.

### 1.3 False positive cytology

False positive cytology is recognised in the published literature and is an important quality assurance measure. UK practice currently accepts a relatively high false positive rate of up to 1%. In the clinical management of individual patients, the risk of overtreatment can be reduced by strict adherence to the principles of the triple diagnostic approach as emphasised in these guidelines.

All those involved with the diagnosis of breast disease should be aware that some lesions currently classified as benign histologically exhibit malignant cytomorphological features. These conditions generally fall within the category of borderline hyperplastic lesions, especially atypical hyperplasia. This histological diagnostic does not rely only on cytomorphology but takes into account the extent and purity of the changes present. These are not demonstrable in cytological preparations. These lesions are not clinically regarded or managed as established malignancy and therefore, at present, these cases should be regarded biostatistically as false positive cases. For these reasons, all false positive cases should be subject to internal unit review and should not necessarily be considered a problem of cytological misdiagnosis/classification.

### 1.4 Resource implications

In the Forrest Committee Report in 1985, neither FNAC nor core biopsy was costed as an essential technique in breast cancer screening. Indeed, to our knowledge, no detailed economic analysis has yet been performed on FNAC or core biopsy in screening in the UK. Time has demonstrated that a reduction in the number of benign biopsies and a reduction in second operations on cancer-bearing breasts can be achieved in centres which have a high level of expertise. This is borne out by the low benign biopsy figures reported by the Epping unit<sup>13</sup> as well as by the figures for benign to malignant ratios at open biopsy presented in the section on sensitivity and specificity.

Many of the existing data on economics of non-operative diagnosis relate to FNAC rather than core biopsy; studies in the USA have discovered a reduction in costs of approximately 90%.<sup>14</sup> An evaluation of the subject showing a similar value in the UK was conducted by Kocjan.<sup>15</sup> The FNA costs for stereotactic aspirations are higher (estimated approximately double), but marker biopsy costs are also much higher. It is therefore apparent that the cost of the FNACs, even if performed on several more patients than would otherwise have been subjected to open biopsy, is likely to be outweighed by the financial savings, even without taking into consideration the benefits in terms of reduced morbidity.

An estimate of the number of biopsies saved can be gained from a study conducted in Guildford which looked specifically at stereotactic aspiration.<sup>16</sup> The estimated benign to malignant ratio without stereotactic aspiration in 250 cases of impalpable lesions based on the

mammographic appearances alone would have been 1:0.94. The actual benign to malignant ratio achieved with stereotactic aspiration was 1:2.5. In addition, seven extra cancers were discovered in the mammographically low risk group that would otherwise have not been biopsied at the first assessment.

Data on core biopsy use from the US show a cost saving of core biopsy over specimen biopsies of approximately 300% per case in one unit (\$243 vs. \$698)<sup>17</sup> and \$744 for ultrasound biopsy or \$519 for stereotactic biopsy over the cost of surgical biopsy in a second unit.<sup>18</sup> FNAC and core biopsy will be most effective within the framework of an integrated team approach to assessment and its quality must, like other aspects of the screening programme, be monitored.

Archived on 22/03/2017

## 2. SAMPLING TECHNIQUES AND PROCEDURES

### 2.1 Sampling techniques

This chapter considers the following techniques:

- fine needle aspiration cytology (FNAC)
- core biopsy
- large volume core techniques
  - vacuum assisted core biopsy (Mammotome)
  - minimally invasive breast biopsy (MIB)
  - advanced breast biopsy instrumentation (ABBI)
  - Site Select percutaneous breast biopsy (PBB)

All of these procedures are best carried out by experienced clinicians or radiologists who are specialists in breast imaging or by a multidisciplinary team with a specialist radiologist present.

### 2.2 Use of image guidance for breast biopsy

A high proportion of mammographically detected lesions are impalpable and require image guidance for FNAC or core biopsy sampling. In addition, image guidance, particularly ultrasound, can have advantages over freehand procedures when sampling some palpable lesions

#### 2.2.1 *When to use ultrasound guidance*

Most soft tissue lesions in the breast are visible using modern high frequency apparatus with a frequency range of up to 10–13 MHz. Ultrasound guided FNAC or core biopsy is the technique of first choice for sampling impalpable breast lesions as it is easier to perform, more comfortable for the patient and less time-consuming than the x-ray guided techniques. It allows real time demonstration of the needle traversing the lesion.. The radiologist must be certain that the abnormality seen on ultrasound is the same as the abnormality seen on mammography. X-ray guided FNAC and core biopsy should be used where there is any doubt about the ultrasound appearances. Ultrasound is also increasingly being used to guide needle biopsy of palpable masses to ensure accurate sampling. Some clusters of microcalcification, particularly coarser comedo-type calcification, are visible on high frequency ultrasound and may therefore be sampled by ultrasound guidance.

#### 2.2.2 *When to use stereotactic guidance*

X-ray stereotaxis is used for image guided biopsy of most suspicious microcalcifications, areas of parenchymal distortion/stellate lesions or small soft tissue masses that cannot be adequately visualised by ultrasound. Stereotactic localisation can be carried out with the patient in the upright or prone positions. Upright stereotactic units are more widely available and less expensive than dedicated prone stereotactic units. Digital imaging is becoming available for use with conventional upright stereotactic units, and this improves the accuracy of the technique because of the shorter image acquisition time and because of the improved quality of the digital images.

The main problems encountered with the use of the upright stereotactic

units are vaso-vagal episodes and difficulty in accurately targeting lesions that are very posteriorly situated. It is possible with some units to carry out the stereotactic biopsy procedure with the patient lying on her side. Dedicated prone breast biopsy systems use a table on which the patient lies in the prone oblique position and the breast passes through a rounded aperture in the table. The advantages of the prone system are the negligible risk of a vaso-vagal episode, a stable position with minimal patient movement and improved access to lesions situated in the inferior or posterior parts of the breast. The dedicated prone breast biopsy systems are supplied with digital imaging, allowing rapid acquisition of stereotactic images, manipulation of the digital images including magnification, image reversal and contrast adjustment for improved visualisation of the target abnormalities. The disadvantages of the dedicated prone breast biopsy systems are the high capital cost of the equipment and the need for a dedicated room, which cannot be otherwise used for diagnostic mammography.

### 2.3 Fine needle aspiration cytology (FNAC)

#### 2.3.1 Personnel

The success of FNAC is directly related to the skill and experience of the operators. The number of staff involved should be kept to a minimum. A core team of aspirators who perform all breast needling procedures should be established in each centre. Trainees must be closely supervised. An experienced radiographer is essential for x-ray guided procedures. For both x-ray and ultrasound guided FNAC it is recommended that an assistant skilled in specimen preparation, preferably a medical laboratory scientific officer (MLSO) or a pathologist, is present. The procedure time is significantly shortened if an assistant deals with the specimens and smears the slides while the aspirator obtains further samples. If a trained MLSO or pathologist is available to assess the adequacy of the aspirate immediately using a rapid staining technique, recall for repeat cytology can be avoided, therefore reducing delay and distress.

#### 2.3.2 Equipment

Needles (22 or 23 gauge) of appropriate type and length are ideal for FNAC. A 10- or 20-ml syringe is used to apply suction. A short extension tube between the needle and syringe is usually required for image guided procedures. A syringe holder is desirable but not essential although it does make manipulation of the syringe with simultaneous constant suction much easier. Several makes of holder, eg Cameco Ltd, Nyegaard Aspirator, R H syringe holder, are available in appropriate sizes. For superficial lesions or in small breasts, a 23G (blue) needle is sufficient and may produce less bleeding. Needles that have no dead space in the needle hub are best for FNAC (eg B & D Microlance). Finer gauge needles, eg 25G (orange), are used in some units with excellent results.<sup>19</sup> In large breasts or in deeper lesions, a 22G (grey) needle may be necessary because of its extra length. A needle with a trocar may be preferred for deep lesions as it is more rigid and is less likely to become blocked or contaminated during insertion.

#### 2.3.3 Local anaesthetic

Local anaesthetic is not usually necessary for freehand FNAC procedures, and excessive use of anaesthetic can lead to specimen

contamination by fluid, causing fixation problems. If sampling requires multiple skin punctures, local anaesthetic may be used to anaesthetise the skin or ethyl chloride spray can be employed to freeze the skin. This may be particularly helpful for x-ray guided techniques with multiple samples, which take significantly longer to perform. The use of local anaesthetic reduces the risk of pain-induced patient movement within the compression plate during the procedure. To avoid contamination of the aspirate the local anaesthetic should **not** be injected deep to the dermis.

### 2.3.4 *Freehand FNAC*

The procedure for obtaining the specimen is explained to the patient. Skilful introduction of the aspirating needle produces very little discomfort. For very apprehensive patients, skin anaesthesia with local anaesthetic spray or a freezing spray, eg ethyl chloride, can be used.

The lesion is held gently but firmly by the fingers of the locating hand with the overlying skin slightly stretched. The area is cleansed with an alcohol-impregnated swab, but it is important that any excess alcohol is wiped away or allowed to dry. Traces of alcohol introduced with the needle are the main cause of the burning sensation of which patients occasionally complain after aspiration.

With the syringe firmly attached and the plunger fully closed to exclude air from the barrel, the needle is readied for insertion. The patient is warned before the skin is punctured. The needle is introduced into the skin with no air in the syringe barrel. The needle is positioned at the anterior edge of the lump (which can usually be felt with the needle tip) and negative pressure is applied either with the thumb or, more easily, with a syringe holder. Several passes through the lesion, varying the angle of entry into the lesion and rotating the syringe slowly, are made, without withdrawing the needle from the skin, until a small drop of fluid is seen in the hub of the needle. Some aspirators advocate picking up the lesion, rotating the syringe during aspiration and varying the speed of passes to increase the yield. The negative pressure is released and then the needle is withdrawn from the skin. If a large amount of blood is obtained it is best to interrupt the procedure, apply pressure to the area to limit haematoma and either repeat the aspiration in the same session from a different angle or delay for one month.

Breast lesions are often deeper than they appear. If there is doubt about whether the lesion has been sampled, then reaspiration using a longer needle may be necessary. If there is no resistance to the needle from a lump that appears clinically not to be a lipoma, then it is likely the lesion has been missed by the needle. Reaspiration is advised, especially if the spread slide shows oily droplets throughout. Similarly, heavily blood stained aspirates may not be representative of the lesion. If material appears to be stuck in the hub of the needle then, using another needle, it can be sucked out of the hub into the barrel of the new needle and expelled from there or retrieved by washing into transport medium. Another method that uses a needle only and capillary action to draw the



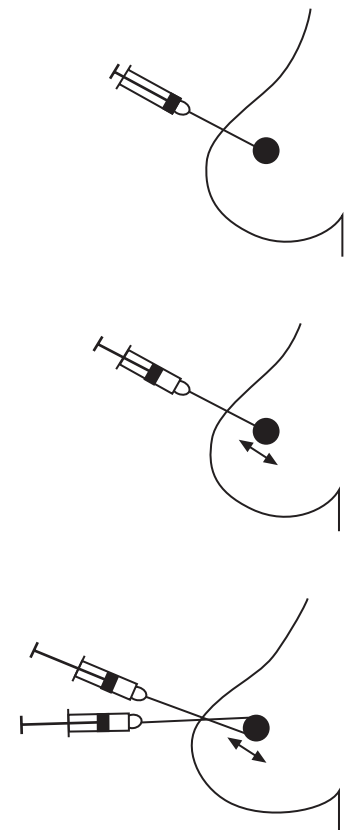
fluid into the hub has been described by Zajdela et al,<sup>20</sup> but as far as is known this is not applicable to stereotactic aspiration of breast.

Some breast lesions give a characteristic 'feel' as the needle traverses the lesion. This can occasionally be a very helpful pointer as to whether or not the lesion has been sampled. These are conveniently described as:

No resistance	Fatty tissue
Soft	Fibroadenoma, mucinous carcinoma, medullary carcinoma
Rubbery	Fibrocystic changes, lobular carcinoma, fibroadenoma
Hard	Fibrous tissue, hyalinised fibroadenoma, post-radiotherapy
Gritty	Carcinoma, microcalcified tissue
Cystic	Cyst in fibrocystic change

The aspiration procedure is shown in Figure 1.

1. Locate the lesion.
2. Clean the skin.
3. Local anaesthetic may be used but may make the lesion difficult to feel. Inject the skin and immediate subcutaneous tissue only. Avoid injecting the lesion.
4. Place syringe and needle into holder if used.
5. Fix the lesion between the index finger and the thumb.
6. Choosing the shortest direction, introduce the needle through the stretched skin and subcutaneous tissue into lesion.
7. Enter lesion with needle point.
8. Aspirate by exerting gentle negative pressure through the syringe and moving the needle tip gently by short back and forth movements within the lesion.
9. Maintain negative pressure and withdraw the needle point just out of the lesion. Reinsert at a slightly different angle and repeat above procedure.
10. Repeat at least twice at different angles without withdrawing needle from skin.
11. Release negative pressure from syringe before withdrawing the needle. Then withdraw the needle from the skin.



**Figure 1** Aspiration procedure for freehand FNAC.

### 2.3.5 *Ultrasound guided FNAC*

The patient is positioned to provide optimal access to the area to be sampled; this may involve, for example, raising and supporting the left side for biopsy of lesions situated in the lateral aspect of the left breast. To sample lesions that are situated in the lateral aspect of the right breast it may be necessary to turn the patient on the couch so that a right-handed operator can easily access such lesions using a lateral approach. An assistant should work from the opposite side of the couch to the radiologist.

The lesion is demonstrated and the surrounding breast tissue is immobilised by applying pressure with the palm of the hand holding the probe. Infiltration of the skin with local anaesthetic may be carried out. The FNAC needle, attached by a short connecting tube to a 10-ml syringe held by the assistant, is introduced into the breast along the line of the long axis of the ultrasound probe and will be easily visualised if it is kept parallel to the surface of the probe. The needle tip is guided into the lesion and an image is taken to record that the needle is correctly positioned. The needle is then moved back and forth within the lesion with simultaneous rotation and with negative pressure being applied by the assistant. Aspiration is continued until material is seen within the hub of the needle. The aspirate is then delivered onto slides, and dry and wet preparations made in accordance with guidance from the pathologist. Two or three separate samples are commonly obtained in order to increase the chances of obtaining a diagnostic cellular sample.

Ultrasound jelly may present a problem in interpretation for pathologists seeing it for the first time and should not be confused with calcium salts or necrosis. It should not be used during the aspiration procedure and, if used previously, should be carefully removed.

### 2.3.6 *Stereotactic FNAC*

For FNAC using a stereotactic device with a conventional upright mammography machine, the patient is seated. A superior approach with the breast positioned for the craniocaudal view is suitable for most lesions, but lateromedial, mediolateral or oblique approaches may be needed for lesions that are inferiorly positioned or are situated laterally in the axillary tail region. After demonstrating the lesion on a straight scout film, paired stereotactic views are obtained with the x-ray tube angled 15° either side of the central straight tube position. The position of the lesion on the stereotactic views is used to determine the position of the needle guide in the *x*- and *y*-axes so that, when a needle of known length is introduced through the guide into the breast, the needle tip will be correctly positioned within the lesion.

The skin is cleaned and superficial infiltration with local anaesthetic may be carried out. The sampling needle (22G or 23G) is inserted through the needle guide and into the breast so that the needle hub is against the guide. Check stereotactic films are taken to ensure correct positioning of the needle in relation to the target lesion. If the position is not correct, the needle is repositioned and further check films are obtained. After checking the position of the needle tip, a point should be extended through the lesion to allow passage of the needle through



the lesion during aspiration. When the needle position is correct, aspiration is carried out by simultaneously rotating and passing the needle repeatedly in and out of the lesion.

Different areas of the lesion are sampled by moving the needle 2–3 mm in the  $x$ - and  $y$ -axes. Up to five aspirates are usually obtained. The centre of the lesion should be selected for the first needle pass (Figure 2A). Subsequent needle passes should aim to sample the periphery of the lesion (Figure 2B, C, D and E). This ‘star’ pattern of sampling is most appropriate for mass and stellate lesions. A less geometric sampling pattern may be more appropriate for lesions such as irregular clusters of microcalcification (Figure 3) although needle core biopsy sampling is now generally preferable in this particular setting.<sup>10</sup>

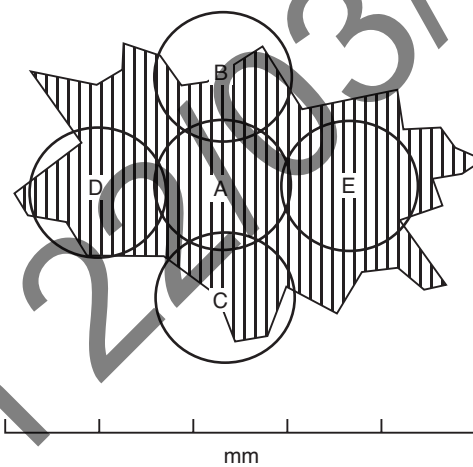


Figure 2 Sampling pattern for stereotactic FNAC.

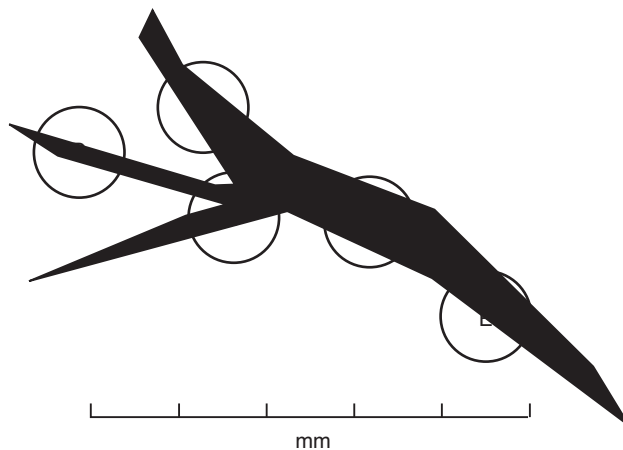


Figure 3 Sampling pattern for irregular lesions.

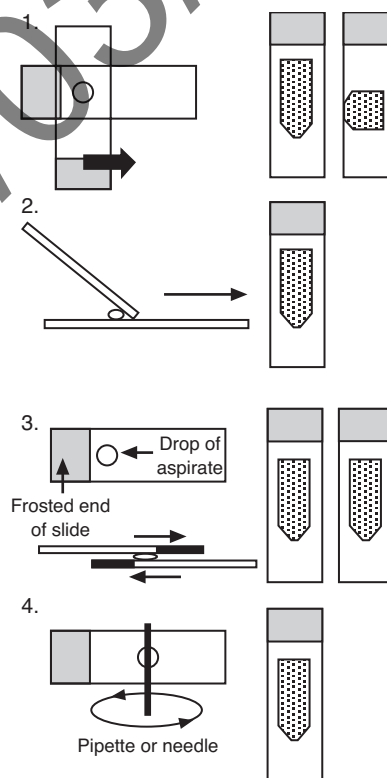
### 2.3.7 Spreading and fixing the slides

A number of methods can be used to spread the slides obtained by placing a drop of aspirated material from the needle on a glass slide. Many of these are variations on a theme, but the essential goal is to get a thin layer of material on the slide to allow rapid drying for air-dried fixation without appreciable squash artefacts due to excess pressure (Figure 4). Techniques for fixing the slides are shown in Figure 5.

All pathologists have received slides that have been ruined by poor spreading technique even though the aspirate has been well taken. It is sometimes difficult to remedy this, but multidisciplinary discussion and making aspirators aware of the problems, especially visually and microscopically, often helps to alleviate the problem. Should such problems persist, alternative preparative techniques such as cytopspin or thin preparations may be considered.

Spreading with a slide.

Three basic methods, all producing similar effects, can be used (1, 2 or 3).



Alternatively, the slide may be spread using a pipette or a needle (4).

Whichever method is used, it is imperative that no excess downward pressure or surface tension effects are allowed to squash or distort the cells as this may render the slides uninterpretable.

**Figure 4** Spreading the slides.

### Wet fixed smears

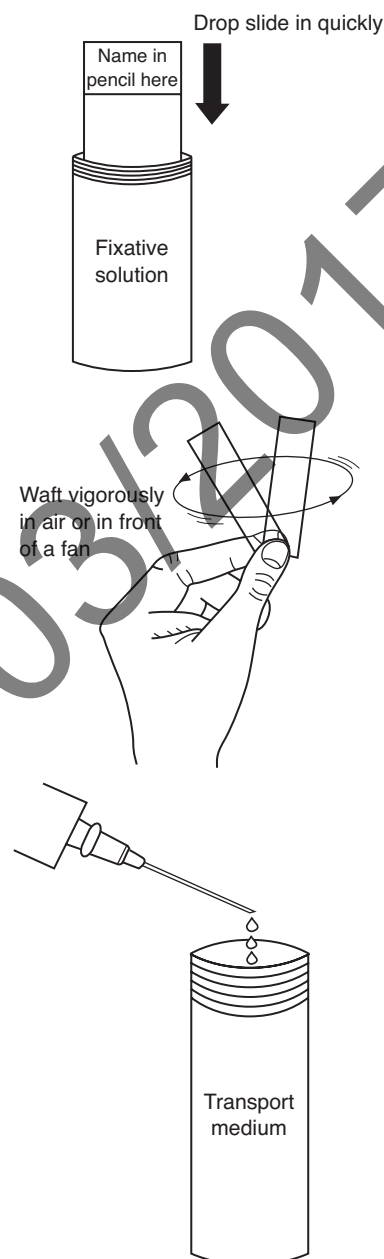
These smears must be fixed **immediately** after spreading and before they have a chance to dry, by dropping into a pot of fixative, or flooding the slide with a drop of fixative if no container is available. Spray fixative can be used.

### Air-dried smears

After spreading the slide should be dried **rapidly** by waving in the air or by using a fan. Alternatively, a hairdryer can be used, but this must be on a cold setting as warm air will 'cook' the cells and lead to artefacts.

### Transport medium

In some units transport medium is used for specimens, which means that optimum preparations can be made in the laboratory after cytocentrifugation. This method is best used where clinicians are not used to making cytological smears and do not follow proper fixation techniques. It can be superior to delayed fixation of wet preparations where air-drying can make interpretation difficult.



**Figure 5** Fixation methods.

## 2.4 Core biopsy

Core biopsy of the breast is a safe and effective method for obtaining a non-operative diagnosis of breast lesions. Core biopsy should be performed with caution in patients who are receiving treatment with anticoagulants. Aspirin is not a contraindication. The consent procedure should follow local rules, but the procedure and common complications should be explained to the patient. An assistant is required to compress the breast between needle passes.

Breast core biopsy should be performed with an automated gun, as these have been shown to obtain larger samples than disposable devices. Superior results are obtained using a long throw gun (23 mm) and 14G needles. Local anaesthetic should be applied to the skin and also to the lesion unless the lesion is difficult to see or feel. The skin entry

site should be placed as far away from the nipple as is practicable and should never be within the areola. A small skin nick that also traverses the superficial fascia should be made with a scalpel blade. This enables easy insertion of the needle. If the breast tissue is very fibrous, insertion of the needle in a radial direction makes manipulation easier. The major complications of breast needle biopsy occur if the pleura is traversed. To avoid this, the needle should be kept approximately parallel to the chest wall when fired. This means that the skin entry site for deep lesions needs to be further away from the lesion than for superficial lesions. For lesions 10 mm or larger, the tip of the needle should abut the lesion before firing. When biopsying lesions less than 10 mm in diameter the needle tip should be just short of the lesion before firing. It is the operator's responsibility to confirm the patient's identification and label the specimen pot before leaving the room.

After the procedure, the biopsy site should be compressed for a minimum of 5 minutes. The patient should be given written information concerning where and when she will receive the result and informed about possible complications of the procedure. The patient should be advised that mild post-procedure pain and bruising are common and told not to exercise her upper limbs for the rest of the day. The patient information sheet should advise the patient to phone the hospital (the number should be on the patient information sheet) if the breast swells appreciably or if she becomes short of breath.

### 2.4.1 *Ultrasound guided core biopsy*

The lesion is demonstrated and surrounding breast tissue immobilised in the same way as for FNAC. Local anaesthetic is infiltrated both superficially and deeply down to the lesion. For posteriorly placed lesions, local anaesthetic can be infiltrated posteriorly in order to displace the lesion anteriorly. A 2- to 3-mm skin incision is made to allow insertion of the core biopsy needle along the direction of the long axis of the ultrasound probe. A14G needle is used with an automated biopsy gun. The needle is advanced until the tip is a few millimetres proximal to the edge of the lesion. The core biopsy gun is then fired and the needle is visualised passing through the lesion. A check image with the needle through the lesion is recorded. The needle is withdrawn and the specimen is delivered into fixative. One or two passes are usually sufficient in most cases to obtain diagnostic material from soft tissue mass lesions. At the end of the procedure firm pressure is applied by the assistant over the site of the biopsy to ensure haemostasis.

### 2.4.2 *Stereotactic core biopsy*

Stereotactic guided core biopsy may be carried out with upright stereotactic apparatus. Targeting of the lesion is carried out in the same way as for FNAC. The procedure is carried out under local anaesthetic. After checking the position of the needle tip, the needle is withdrawn approximately 5 mm so that the needle tip is just proximal to the lesion before firing. The biopsy port will then traverse the lesion on firing, ensuring adequate tissue sampling. It is important to ensure that there is sufficient tissue deep to the needle tip following firing so that the needle tip does not hit the surface of the cassette holder. Apparatus is also available that allows a lateral approach to lesions with the breast compressed in the craniocaudal position. This allows improved access to

lesions which are in the inferior part of the breast and eliminates the risk of the needle tip hitting the surface of the x-ray cassette holder.

### 2.4.3 *Prone stereotactic core biopsy*

The breast is passed through a rounded aperture in the table. For lesions which are very posteriorly positioned or which lie in the region of the axillary tail, access can be improved by passing the ipsilateral arm and shoulder girdle through the aperture. Stereotactic views are obtained by rotating the tube 15° either side of the central position. Digital images are displayed on a computer screen for targeting and the biopsy needle holder position is adjusted automatically. Check films are taken during the procedure to ensure accurate positioning and that the needle has traversed the lesion. Five or more core samples are usually obtained, using a 14G needle.

When sampling areas of microcalcification with either conventional upright stereotactic equipment or with prone stereotactic systems, radiography of the core samples is carried out to ensure that tissue containing microcalcification has been obtained.

## 2.5 **Large volume sampling techniques**

### 2.5.1 *Vacuum assisted core biopsy*

The Mammotome and MIB vacuum assisted core biopsy systems use either an 8G, 11G or 14G needle probe. Most published results describe their use with prone stereotactic apparatus, but recent developments enable them to be used for ultrasound guided breast biopsy.

The biopsy probe incorporates a vacuum channel, which applies negative pressure to the biopsy port and thereby sucks the adjacent breast tissue into the port for sampling. The biopsy probe is introduced into the breast and positioned using image guidance. Deep local anaesthetic containing adrenaline is used. The vacuum is activated and sucks breast tissue into the biopsy port; a rotating cutting cylinder then passes down within the probe and separates the biopsy material from the surrounding tissue. The biopsy specimen is then delivered by withdrawing the cutting cylinder while applying negative pressure and while the main probe remains within the breast. Multiple specimens are obtained by rotating the biopsy probe within the breast so that the biopsy port is applied to different areas of breast tissue.

The potential advantages of this system are the ability to obtain a larger volume of tissue for histological examination and the rapid evacuation of any haematoma which collects at the site of biopsy. This ensures that the specimens obtained are of good quality and are not compromised by the presence of haematoma.

In cases where the whole or a high proportion of the mammographic lesion has been removed, a small metal marker clip is introduced through the biopsy probe and deployed at the biopsy site.

### 2.5.2 *The ABBI and Site Select PBB biopsy devices*

Both of these devices involve insertion, using prone stereotactic imaging guidance, of a large bore cutting cylinder which cuts a core of tissue containing the mammographic abnormality. The diameter of the ABBI sampling device is up to 20 mm, that of the PBB device 15 mm. The PBB device differs from the ABBI system in having a cutting blade at the leading edge of the biopsy probe, allowing it to be placed against the proximal edge of the lesion before sampling. These techniques are more invasive than standard core biopsy or vacuum assisted core biopsy and require a 20-mm skin incision for insertion of the biopsy device, and for these reasons their use is limited.

## 2.6 **Complications of FNAC and core biopsy**

FNAC and core biopsy are remarkably complication free; however, certain rare problems should be considered.

### 2.6.1 *Pain*

Pain is common on fine needle aspiration but is transitory and is not usually severe. Aspiration from painful areas of benign breast change is sometimes associated with some pain when the needle comes into contact with the painful area. Carcinomas, particularly those with abundant fibroelastotic stroma, are often also painful, and this can be a guide to the aspirator that the needle has hit the lesion.

### 2.6.2 *Haematoma*

All imaging investigations should be complete before sampling is performed as haematoma formation, if it occurs, can cause confusion on subsequent mammography or ultrasound. Haematomas may cause problems, especially if a larger vessel is punctured. In some cases, the procedure may have to be abandoned and reaspiration delayed until a later clinic visit because the lesion may no longer be localisable if a large haematoma has formed. Haematoma formation may not be painful for the patient at the time but often becomes so later, and a recommendation for light analgesia, eg paracetamol, may be appropriate.

### 2.6.3 *Pneumothorax*

This is a rare complication<sup>21</sup> found mainly in women with small breasts, in medial lesions or when sampling axillary nodes. It is not a problem with image guidance such as stereotactic or perforated plate and should not occur with an experienced ultrasound operator as the position of the needle can be seen. It is therefore most likely to occur with palpable lesions. It is more likely to occur with an experienced aspirator as novices tend to be rather circumspect and, if anything, do not probe to sufficient depth. Large pneumothoraces should be obvious, but the problem may go undetected if the pneumothorax is small. Clues such as sharp pain, coughing or a hiss of air on withdrawing the needle without evidence of air in the syringe may occur.

### 2.6.4 *Fainting*

This complication has occasionally occurred during sampling. It is of special significance during upright stereotactic or perforated plate examinations where the patient has to be released from the machine and laid flat. The procedure usually has to be abandoned.

### 2.6.5 *Removal of lesion by core biopsy*

Small lesions, including foci of microcalcification, may, particularly if extensively sampled, be removed by core biopsy. This risk increases when a large number of core samples are taken or larger bore sampling

techniques such as Mammotome or ABBI are used. This problem has been reported more frequently from the USA, where there is more aggressive use of core biopsy than is presently undertaken in the UK.<sup>22</sup> It is recommended that clips or ink be inserted at the site of biopsy by the radiologist at the time to ensure that the site can be identified for subsequent localisation biopsy and pathological assessment.

On occasions, a small invasive focus in a predominant ductal carcinoma in situ (DCIS) lesion may be sampled and removed by core with no further foci of invasion remaining in the excision specimen, despite thorough examination. In such circumstances, the core biopsy sample can be used to provide information on tumour differentiation and type.

### 2.6.6 *Seeding of tumour*

Seeding of malignant cells has become increasingly recognised as a result of the increased use of core biopsy.<sup>23</sup> This process is also, uncommonly, seen after FNAC.<sup>24</sup> Rarely, this may cause histopathological diagnostic difficulties in the subsequent excision. Islands of cells (sometimes showing degenerative features) are seen outside the main lesion, often within a fibroblastic and histiocyte tissue response indicating the previous sampling site. Seeding is rarely recognised more than a few millimetres from the source of the cells, and the correct identification is usually straightforward. Cell groups may be seeded from papillary lesions or DCIS mimicking invasive carcinoma. The associated signs of trauma from non-operative sampling should be sought. The clinical significance of this phenomenon is not yet clear.



### 3. FNAC REPORTING GUIDELINES

This chapter is designed to assist classification and reporting of FNAC samples. The terminology and diagnostic entities referred to are described in more detail in *Pathology Reporting in Breast Cancer Screening* (2nd edition) (NHSBSP Publication No 3).<sup>5</sup>

#### 3.1 Using the cytopathology reporting form

The cytopathology core biopsy reporting forms used may be the separate reporting form (Figure 6) or the form generated specifically by the national breast screening computer system (Figure 7), which comes with the patient details automatically filled in by the computer. Both forms request essentially the same information, although the computer generated form has spaces for radiographic information such as kV, mAs, side and type of localisation (palpable, ultrasound, stereotactic or other x-ray guided procedure). The way in which the national breast screening system treats this information is shown in Appendix 1. Information on the nature of the mammographic abnormality and clinical characteristics should be provided by the breast screening radiologist requesting the pathology examination. It may not be possible to enter some details, such as name of aspirator and type of procedure, if the pathologist completing the form did not perform the aspirate or was not provided with this information on a request form.

Reporting forms

BREAST SCREENING CYTOPATHOLOGY

Surname \_\_\_\_\_ Forenames \_\_\_\_\_ Date of birth \_\_\_\_\_

Screening no. \_\_\_\_\_ Hospital no. \_\_\_\_\_ Centre \_\_\_\_\_ Report no. \_\_\_\_\_

Side  Right  Left

Specimen type  FNA (solid lesion)  FNA (cyst)  Nipple discharge  Nipple or skin scrapings

Localisation technique  Palpation  X-ray guided  Ultrasound guided  Stereotaxis

Opinion  1 Unsatisfactory  2 Benign  3 Atypia probably benign  4 Suspicious of malignancy  5 Malignant

Comment \_\_\_\_\_

Case for review ?

PATHOLOGIST \_\_\_\_\_ NAME OF ASPIRATOR \_\_\_\_\_ DATE \_\_\_\_\_

Figure 6 Example of a cytopathology reporting form.



BSS: FOLLOW-UP FNA FORM		Sx number:	Name:
Surname:		NHS number:	
Forenames:		Date of diagnosis:	
Title:			
Date of birth:			
<hr/>			
<b>FNA</b>	Date performed:	Location:	Aspirator:
Side:	<div style="border: 1px solid black; padding: 5px;">                 Comment (max. 65 characters)             </div>		
LOCALISATION TYPE:			
kV:			
Total mAs:			
Total exposures:			
Total films:	Cyst aspiration without cytology:		
<hr/>			
<b>FNA CYTOLOGY</b>		Pathologist:	
Date reported:		<div style="border: 1px solid black; padding: 5px;">                 Comment (max. 132 characters)             </div>	
Specimen number:			
Specimen type:			
AS FNA (solid)	AC FNA (cyst)		
ND Nipple discharge			
NS Nipple or skin scraping			
Cytological opinion:			
C1 Unsatisfactory	C3 Atypia, probably benign	C5 Malignant	
C2 Benign	C4 Suspicious of malignancy		

Figure 7 Example of a computer generated FNAC reporting form.

### 3.2 Recording basic information

#### *Centre/location*

Give the name of the assessment centre, clinic, department, etc where the specimen was obtained.

#### *Side*

Indicate right or left. For specimens from both sides use a separate form for each side.

#### *Specimen type*

Please choose one of the following terms:

FNA (solid lesion)	Fine needle aspiration of a solid lesion
FNA (cyst)	Fine needle aspiration of a cyst subjected to cytological examination
Nipple discharge	Cytological preparation of a nipple discharge
Nipple or skin scrapings	Cytological preparation of scrapings from the nipple or skin

*Localisation technique*

Please choose one of the following terms:

Palpation	FNA guided by palpation
Ultrasound guided	FNA guided by ultrasound
X-ray guided	FNA guided by x-ray examination (perforated or fenestrated plate)
Stereotactic	FNA guided by stereotaxis

*Pathologist*

The name of the pathologist giving the cytological opinion, who must be registered at the screening office, should be entered.

*Aspirator*

Enter the name of the person performing the fine needle aspiration.

*Date*

Enter the date of reporting the slides.

*Case for review*

This is a field to indicate that a specimen has been sent for a further opinion or that the case is a particularly interesting example.

*Recording the cytology opinion*

See section 3.3 below.

*Comment field*

This free text field is included for extra information to be recorded.

### 3.3 Reporting categories

In ideal circumstances, one should aim for a definitive diagnosis of malignancy or benignity. The proportion of cases in which this is possible will increase with experience of both the pathologist and aspirator. However, there are always cases in which an inadequate sample or cell morphology make such a clear distinction impossible.

*C1 (inadequate)*

The designation of an aspirate as 'inadequate' is to some extent a subjective matter and may depend on the experience of the aspirator and/or the interpreter. It is generally based on the presence of sufficient numbers of epithelial cells to provide a sample adequate for confident assessment. There are a number of reasons for labelling a smear as inadequate. These fall into three main groups:

1. hypocellularity
2. error in aspiration, spreading or staining
3. excessive blood.

In some cases diagnostic information may be present and may be conveyed in the accompanying text description, for example adipose tissue fragments could support a clinical diagnosis of lipoma. Aspirates from some lesions, such as cysts, abscesses, fat necrosis and nipple

discharge specimens, may not contain epithelial cells but should clearly not be classified as inadequate.

Preparative artefacts include:

- crush, when too much pressure is used during smearing
- drying, when the dry smears are allowed to dry too slowly (dry smears should be dried quickly; wafting in the air can speed up drying) or when the wet fixed smears have been allowed to dry out before fixation
- thickness of smear, when an overlay of blood, protein rich fluid or cells is obscuring the picture, making assessment impossible.

It is often helpful to make a comment as to the cause of inadequate specimens in the comment box on the reporting form.

### *C2 (benign)*

This category indicates an adequate sample showing no evidence of significant atypia or malignancy and, if representative, a negative report. Alternatively, an aspirate may be poorly to moderately cellular and consist mainly of regular duct epithelial cells. These are generally arranged as monolayers and the cells have the characteristic benign cytological features. The background is usually composed of dispersed individual and paired naked nuclei. If cystic structures are a component of the aspirated breast, then a mixture of foamy macrophages and regular apocrine cells may be part of the picture. Fragments of fibrofatty and/or fatty tissue are common findings.

A positive diagnosis of specific conditions, for example fibroadenoma, fat necrosis, granulomatous mastitis, breast abscess or lymph node, may be suggested if sufficient specific features are present to establish the diagnosis with confidence and may be helpful in multidisciplinary correlation.

### *C3 (atypia probably benign)*

The aspirate here can have all the characteristics of a benign aspirate as described above. However, in addition, certain features not commonly seen in benign aspirates may be present.<sup>25</sup> These could be any, or a combination, of the following:

1. nuclear pleomorphism
2. some loss of cellular cohesiveness
3. nuclear and cytoplasmic changes resulting from, for example, hormonal (pregnancy, pill, hormone replacement therapy) or treatment influences (see Chapter 4)
4. increased cellularity accompanying the above features.

### *C4 (suspicious of malignancy)*

This category should be used for those aspirates with highly atypical features, such that the pathologist is almost certain that they come from a malignant lesion although a confident diagnosis cannot be made. There may be for three main reasons for this:

## Non-operative diagnostic procedures and reporting

1. The specimen is scanty, poorly preserved or poorly prepared, but some cells with features of malignancy are present.
2. The sample may show some malignant features in the absence of overtly malignant cells. The degree of abnormality should be more severe than in the previous category.
3. The sample has an overall benign pattern with large numbers of naked nuclei and/or cohesive sheets of cells but with occasional cells showing distinct malignant features.

Definitive therapeutic surgery should **not** be undertaken as a result of a C3 or C4 diagnosis.

### *C5 (malignant)*

This category indicates an adequate sample containing cells characteristic of carcinoma, or other malignancy. The interpreter should feel at ease in making such a diagnosis. Malignancy should not be diagnosed on the basis of a single criterion. Combination of the features listed in Table 3 will be necessary to achieve this diagnosis.

**Table 3** General diagnostic criteria for the recognition of benign and malignant conditions

Criterion	Benign	Malignant
Cellularity	Usually poor or moderate	Usually high
Cell to cell cohesion	Good with large defined clusters of cells	Poor with cell separation resulting in dissociated cells with cytoplasm or small groups of intact cells
Cell arrangement	Even, usually in flat sheets (monolayers)	Irregular with overlapping and three-dimensional arrangement
Cell types	Mixtures of epithelial, myoepithelial and other cells with fragments of stroma	Usually uniform cell population
Bipolar (elliptical) bare nuclei	Present, often in high numbers	Not conspicuous
Background	Generally clean except in inflammatory conditions	Occasionally with necrotic debris and sometimes inflammatory cells including macrophages
<b>Nuclear characteristics</b>		
Size (in relation to red blood cell (RBC) diameter)	Small	Variable, often large, depending on tumour type
Pleomorphism	Rare	Common
Nuclear membranes (Pap stain)	Smooth	Irregular with indentations
Nucleoli (Pap stain)	Indistinct or small and single	Variable but may be prominent, large and multiple
Chromatin (Pap stain)	Smooth or fine	Clumped and may be irregular
Additional features	Apocrine metaplasia, foamy macrophages	Mucin, intracytoplasmic lumina

### 3.4 Calcification in FNAC

It is very useful for the radiologist if the pathologist reports the presence of calcification within specimens taken from stereotactic or perforated plate guided FNAC when the abnormality is one of mammographic microcalcification. If calcification is present in these circumstances, the radiologist or multidisciplinary team can be more certain that the lesion has been sampled accurately and that the likelihood of a false negative due to an aspiration miss is lower. Calcification alone does not discriminate between benign and malignant conditions.

### 3.5 General diagnostic patterns

The essential role of cytological diagnosis is to distinguish benign from malignant processes. The common general criteria used are illustrated in Table 3. It is important to bear in mind that the morphological and histological patterns seen in both benign and malignant breast disease are quite varied, and this is reflected in the cytological appearances. For this reason, it is useful to have a working understanding of breast histology before approaching breast fine needle aspiration cytology. This knowledge can improve recognition of rare lesions and reduce numbers of false positive and negative diagnoses.

Archived on 22/03/2017

## 4. DIAGNOSTIC PITFALLS IN INTERPRETATION OF BREAST FNAC

### 4.1 Common conditions resulting in a false positive diagnosis

#### 4.1.1 Fibroadenoma

Often, smears from fibroadenoma may give very worrisome appearances with marked pleomorphism and some dissociation. Fortunately, this usually happens in actively growing lesions in teenage women rather than in women in the screening age range. The clue to the diagnosis is the presence of 'stripped' bipolar nuclei. Smears containing these in significant numbers should not be diagnosed as malignant unless there are clear features of a benign epithelial lesion (with benign epithelial clumps) and also malignant clumps and dissociated malignant cells recognisable as a distinctly separate cell population. These smears, obtained from samples in which the needle has passed through both a benign and a malignant lesion, may be very difficult to interpret, but the two distinct populations of epithelial cells should aid their recognition. Smears from some malignant tumours contain bare nuclei. These bare or stripped nuclei are not bipolar and have obvious malignant features identical to coexisting intact tumour cells. Often, in fibroadenomas two cell types can be recognised in the cell clumps, even in the rather pleomorphic examples.

#### 4.1.2 Apocrine cells

Apocrine cells in smears may appear rather pleomorphic and may dissociate. Degenerate apocrine cells in cyst fluids may also have a rather worrisome appearance. Recognition of the dusty blue cytoplasm, with or without cytoplasmic granules with Giemsa stains or pink cytoplasm on Papanicolaou or haematoxylin and eosin stains coupled with a prominent central nucleolus is the key to identifying cells as apocrine. Awareness of the marked pleomorphism that may occur in degenerate apocrine cells and careful assessment of the cellularity and chromatin pattern should allow the distinction from the rare apocrine carcinoma. If there is doubt about the nature of apocrine cells it is better to err on the side of caution and give a suspicious or atypical report.

One particularly difficult lesion is atypical apocrine change in sclerosing adenosis,<sup>26</sup> especially if this is associated, as it often is, with a complex sclerosing lesion or radial scar giving a mammographically worrying appearance. In this case, the highly pleomorphic apocrine cells may not always appear obviously apocrine in smears. Features that may be helpful are the abundant cytoplasm with granules and the absence of necrosis. Spindling of cells in the centre of the clumps (myoepithelial cells from the sclerosing adenosis) surrounded by or intermingled with the atypical apocrine cells may be seen.

### 4.1.3 Spreading artefacts

Excessive pressure during spreading of slides may produce dissociation of cells from benign clumps. If the cells within these clumps are also somewhat pleomorphic as a result of degenerative or atypical changes, then the dissociation may cause the cells to resemble dissociated malignant cells. The clue to this is often the finding of nuclear lysis and trails of chromatin due to the overspreading artefact. Fibroadenomata are the most likely lesions to produce these problems when overspread.

### 4.1.4 Papilloma

Aspiration of papillomas usually produces cellular aspirates with 'staghorn' or 'antler horn' clusters of cells similar on low power appearance to those seen in fibroadenomas, although they may appear three-dimensional.<sup>19</sup> In some cases, connective tissue cores may be seen within these clusters. These may be diagnostic of papillomas but are not a common feature. Fibroadenomas do not contain large numbers of foam cells. Bare nuclei are seen in papillomas, but there are generally not as many as in fibroadenomas. Apocrine metaplasia may also be present. Although it is important clinically to distinguish papillomas from intracystic papillary carcinoma, this may not be possible on cytological grounds. Some features of malignancy, such as nuclear pleomorphism, increased nuclear to cytoplasm ratio and cellular crowding or overlapping, may occur with some benign forms of papilloma. No single feature can differentiate the two conditions.

### 4.1.5 Atypical lobular hyperplasia and lobular carcinoma in situ

It is not possible to distinguish atypical lobular hyperplasia (ALH), lobular carcinoma in situ (LCIS) and even invasive lobular carcinoma reliably on fine needle aspiration smears alone. The difference between lobular carcinoma in situ and atypical lobular hyperplasia is one of extent of lobule involvement seen in histological sections and is not based on the cytological appearances of the cell. The cells are similar or identical in morphology. The cytological features of ALH have been well described.<sup>27</sup> Cytologically dissociated small epithelial cells with rounded or squared-off nuclei are seen. These are present singly or in small groups with nuclear moulding. The cells may contain intracytoplasmic lumina (private acini) seen best on mucin staining, when they appear like a 'bull's-eye' with an Alcian blue stained microvillous membrane and a periodic acid-Schiff (PAS) stained mucin droplet in the centre. Atypical lobular hyperplasia and LCIS are usually seen as a chance finding in association with another lesion, which can result in complex appearances in fine needle aspiration smears.

### 4.1.6 Atypical ductal hyperplasia

Atypical ductal hyperplasia is another lesion for which the diagnosis mainly depends on the architectural features and extent of the lesion seen on histology. It is defined as an intraluminal lesion in which some but not all of the features of ductal carcinoma in situ are present. As it can be difficult to distinguish atypical ductal hyperplasia from ductal carcinoma in situ on histological grounds, it is not surprising that it may be difficult or impossible cytologically.

Most cases of ductal carcinoma in situ detected by breast screening are of the 'comedo' or large cell type, and these do not present a problem as, if they are aspirated, the characteristic features of malignant cells are present along with necrosis and dissociation. The difficulty comes



in the distinction of small cell ductal carcinoma in situ of cribriform or micropapillary type from atypical ductal hyperplasia. Cribriform or micropapillary ductal carcinoma in situ does not produce necrosis or large numbers of dissociated cells and is mainly recognised by its architectural pattern within the cell clusters. Atypical ductal hyperplasia is similar but, unlike the monotony of the cell clusters in cribriform ductal carcinoma in situ, the clusters of atypical ductal hyperplasia still show a biphasic pattern, at least in part. They differ from the cell groups found in benign breast lesions in that they have a three-dimensional appearance and usually show some cytological atypia, which may be severe in some cases.

Bibbo et al<sup>28</sup> developed a scoring system for the diagnosis of significant atypical hyperplasia in smears based on four criteria:

- myoepithelial cells
- cellular arrangement (monolayer, overlapping, cluster)
- cellular composition of groups (heterogeneous, variable, homogeneous)
- chromatin pattern (regular fine, regular coarse, irregular coarse).

Abendroth et al<sup>29</sup> felt that architectural features were most helpful in distinguishing atypical ductal hyperplasia from ductal carcinoma in situ. They cited the presence of flat sheets of atypical epithelium, myoepithelial cells and distinct cell borders as distinguishing features. Large numbers of single atypical epithelial cells, dissociation and an inflammatory background were said to be features of carcinoma in situ. Sneige and Staerke<sup>30</sup> did however try to make the distinction between ADH and low grade ductal carcinoma in situ with limited success. Although commendable observations, the practical application of these recommendations is difficult, and in the majority of cases in which an atypical low grade small cell epithelial proliferation is seen, basic principles of FNA cytology diagnosis should be applied to allow classification as C5, C4 or C3 depending on the characteristics present. It is also necessary to remember that atypical ductal hyperplasia may coexist with fibrocystic change, papilloma or radial scar and therefore the radiological appearances are generally dependent on the associated lesion.

#### 4.1.7 Columnar cell change within lobules ('blunt duct adenosis')

This may produce dissociation, and some authors have noted that the cells may resemble lobular carcinoma cells. Some of the cells are columnar in nature, resembling bronchial epithelial cells (see also section 4.1.5).

#### 4.1.8 Lactational change

Focal lactational changes can occur even among women in the screening age group. They are uncommon but can produce occasional dissociated cells within an otherwise benign-appearing smear. The dissociated cells may possess nucleoli and have larger nuclei than the surrounding benign cells. They do, however, have a moderate quantity of pale blue cytoplasm on Giemsa staining with lipid droplets in the cytoplasm. Caution in interpreting occasional dissociated cells in an otherwise benign pattern should be exercised even in women in the screening age



range, and the question ‘Could these be lactational/secretory cells?’ should be specifically asked in these cases. In women outside the screening age range, a history of pregnancy/lactation should always be sought and clinicians should always tell the pathologist of lactation or pregnancy.

### 4.1.9 Radiotherapy changes

These can lead to a false positive cytological diagnosis, especially when the history of previous irradiation is not provided. The aspirate, however, is usually not very cellular, and the interpretation of poorly cellular smears, especially with a history of irradiation, should be undertaken with caution, as described in section 4.1.3. Irradiation can cause marked nuclear pleomorphism and dissociation. Mammography may also not be helpful or even false positive in this situation, which may lead to an inaccurate clinical impression.

### 4.1.10 Organising haematoma

This has been described as a pitfall by Oertel and Galblum.<sup>31</sup> Again, the smears are not very cellular and haemosiderin can be interpreted as melanin, leading to an erroneous diagnosis of metastatic melanoma. Problems can be encountered in aspirates following a previous aspiration shortly before. This is due to activated macrophages and fibroblasts involved in the repair process. Reaspiration should not be performed until 2–3 weeks after a previous aspirate in order to let this reaction settle.

### 4.1.11 Intramammary lymph nodes

These should not cause a problem if the pathologist recognises the cells as lymphoid. Awareness that these can occur and can be aspirated should be enough to avoid an error. Lymphomas may be more difficult to distinguish from carcinoma, but the lack of clumps should suggest the possibility. Careful assessment including immunocytochemistry should distinguish the occasional carcinoma that shows almost complete dissociation with a rather plasmacytoid appearance. Examples of bone marrow in aspirates of lesions stated to be in the breast are rarely seen; the origin of these is assumed to be rib or myelolipoma.

### 4.1.12 Degenerate cells in cyst fluids

Degeneration of cells within cysts or nipple discharge specimens can give pleomorphic appearances, especially when these are larger apocrine cells. Cautious interpretation of cells within degenerate cysts is advised.

### 4.1.13 Ultrasound gel

The amorphous appearance of the gel in the background of the smear may suggest necrosis, and if the preparation is rather cellular, with some cellular pleomorphism, this may lead the unwary to a false positive diagnosis. The problem may be compounded if the gel produces cell lysis.

**4.2 Uncommon lesions causing a false positive diagnosis**

**4.2.1 Inflammatory lesions – granulomatous mastitis and fat necrosis**

Epithelioid macrophages in granulomatous mastitis and fat necrosis can mimic carcinoma cells. They are associated with other inflammatory cells in the smear, and numerous macrophages may be seen. The smear is also very cellular. In the presence of inflammation and a cellular smear, the finding of multinucleate macrophages should alert the observer to the possibility of granulomatous mastitis. The rare cribriform carcinomas with multinucleate giant cells do not usually contain other inflammatory cells and are therefore distinguishable from granulomatous mastitis by their dimorphic picture of small malignant cells in clumps and singly and more basophilic 'osteoclast-like' giant cells with larger nuclei and prominent nucleoli. Mononuclear forms of the multinucleate cells may also be present.

**4.2.2 Granular cell tumour**

This can present a worrisome appearance in smears. There is marked dissociation of rather pink cells which, although they have small nuclei generally, may contain occasional larger nuclei, giving a pleomorphic appearance. The cells, however, do not look epithelial, and benign epithelial clumps are seen between the dissociated cells of the tumour. The cells have eosinophilic granular cytoplasm on Papanicolaou or haematoxylin and eosin staining and a rather mottled pale mauve cytoplasm on Giemsa stains, looking rather similar to apocrine cells.

**4.2.3 Adenomyoepithelial lesions**

These difficult and as yet incompletely understood lesions can show malignant cytological features because of dissociation of rather pleomorphic cells that are in fact myoepithelial. However, obvious benign clumps and bipolar bare nuclei are present.

**4.2.4 Collagenous spherulosis**

This lesion produces rounded globules staining a granular purple colour on Giemsa stains with surrounding spindle cells.<sup>32,33</sup> There is a resemblance to adenoid cystic carcinoma, with which the lesion can be confused. The globules can also be seen in papilloma and ductal adenoma. Biopsy in these rare conditions is advised.

**4.2.5 Microglandular adenosis**

This is reported as being a potential problem in diagnosis.<sup>34</sup>

**4.3 Conditions causing a false negative diagnosis**

The most common cause of false negative cytological diagnosis is an aspiration miss. There are, however, types of carcinoma<sup>35</sup> which, by their nature, may produce a false negative diagnosis. The most common of these are as follows.

**4.3.1 Tubular carcinoma**

Tubular carcinoma cells often have much in common with benign breast epithelial cells, including uniformity, nuclear size and, often, the absence of immediately obvious nuclear abnormalities.<sup>36</sup> Knowledge of the mammographic findings, a lack of bare nuclei, individual cells with cytoplasm and occasional tubular profiles are pointers to the diagnosis. Paradoxically, the nuclei are often more regular and orderly than benign

ductal epithelium and there is a single cell population in the clumps. Often it is not possible to give an unequivocal diagnosis, but care should always be taken in interpreting smears from stellate opacities to avoid false negative results from this type of tumour. It should be noted that tubules can occasionally be obtained from benign lesions, including radial scars, tubular adenomas and fibroadenomas.

### 4.3.2 Lobular carcinoma

Aspirates from this type of carcinoma are often difficult to interpret. The cellularity of these specimens is usually less than that seen in 'ductal' carcinoma.<sup>27,35</sup> A number of patterns can be observed, ranging in cytological appearance from benign-looking uniform cells to atypical cells not dissimilar to those seen in invasive 'ductal' carcinoma. The presence of small three-dimensional collections of cells with only slightly enlarged nuclei is helpful. A large number of cells with intracytoplasmic lumina (private acini) in association with the above features is an indication of lobular carcinoma, although not specific. Nuclear irregularities and small protrusions from the nucleus ('noses') may also be seen.

### 4.3.3 Apocrine carcinoma

This rare type of carcinoma produces cellular smears. Difficulty in interpretation is related to the subtle appearance of the neoplastic apocrine cells and their resemblance to benign apocrine cells with degenerative changes. Clustering of cells and papillary formations are seen in benign as well as malignant lesions and are of little help. The key features of a malignant aspirate are the uniform cell population with nuclear atypia, which one should not confuse with degenerative changes. Necrosis is also a helpful feature. Until one is aware of the marked atypical changes associated with apocrine cells in fibrocystic change the diagnosis of apocrine carcinoma should always be approached with caution.

### 4.3.4 Ductal carcinoma in situ

It should be noted that ductal carcinoma in situ and invasive 'ductal' carcinoma cannot be distinguished accurately by cytology alone. Some features have been identified which may help to distinguish in some cases but these are not uniformly present.<sup>19</sup> While some of the cases of ductal carcinoma in situ are overtly malignant, the small cell type may present a diagnostic dilemma. The cellularity of these samples is moderate; they are never as cellular as frank carcinomas. One should be guided by the increased nuclear/cytoplasmic ratio in the presence of normal size cells. The abnormal nuclear chromatin pattern is a clue to the real nature of the lesion. The presence of some necrotic debris in the background should alert the interpreter to the possible malignant nature of the lesion. A clue in some cases can be obtained from the architectural pattern within the rather rigid and monomorphic clumps. In some cases a report of intraductal proliferation (atypical or suspicious) may be all that can be given, and in such cases biopsy may be the only way to resolve the problem.

### 4.3.5 Carcinoma with extensive fibroelastosis

These tumours may give sparsely cellular smears, which can lead to difficulties in diagnosis. Often it is not possible to be definitive, and the need for caution in the interpretation of poorly cellular smears is again emphasised.

### 4.4 Other unusual lesions

#### 4.4.1 *Silicone, soya oil or paraffin granuloma*

This may occasionally be problematic because of cell dissociation, but the appearances are made easier with the recognition of multinucleate cells and oil or silicone droplets in the cytoplasm of the macrophages. Clinical data are helpful here, and clinicians should understand the need to supply the pathologist with proper clinical information on all breast lumps sampled by FNAC.

#### 4.4.2 *Benign stromal lesions*

These lesions are occasionally aspirated when they produce an irregular mass on mammography or palpation. One of the more usual lesions to be mistaken for carcinoma radiologically is fibromatosis. Nodular fasciitis may, however, also be sampled. On aspiration there are small numbers of stromal cells which are dissociated from each other. The cells are spindle shaped and have regular nuclear characteristics.

#### 4.4.3 *Phyllodes tumours*

The benign variants of phyllodes tumour may not be recognised as such on fine needle aspiration and may give a picture similar to fibroadenoma. Clues to the diagnosis include the presence of intact stromal cells, occasionally with nuclear abnormalities, and the finding of pieces of cellular mucoid connective tissue in the aspirate. Fibroadenomas can also show both these features however, and the recognition of benign phyllodes tumours often depends on clinical and monographic features. Occasionally phyllodes tumours can also produce false positive diagnosis of malignancy. Malignant phyllodes tumours show a pattern of benign-appearing epithelial clumps with spindle cells showing obvious malignant nuclear features.

#### 4.4.4 *Metastatic tumours*

Metastatic tumours in the breast should always be considered in FNAC samples in which a peculiar pattern unusual for breast tumours is seen.<sup>37</sup> Melanoma and oat cell carcinoma are the most common. In melanoma, pigment and large intranuclear cytoplasmic inclusions may be visible. Ovarian metastases are often papillary with psammoma bodies (an uncommon feature of breast tumours), large clear cells full of glycogen may suggest a renal metastasis, squamous carcinoma cells may be from a primary breast lesion but may also be from a metastatic lesion, etc. The triple approach may often resolve this problem.

#### 4.4.5 *Lymphoma*

The recognition of the lymphoid nature of an apparent primary breast tumour depends on the recognition of the spectrum of lymphoid cell types and the absence of clumps of cells. Immunocytochemistry may be necessary in some cases.

#### 4.4.6 *Malignant stromal tumours*

The commonest sarcoma to be aspirated from the breast is the angiosarcoma. This can show variable cytological features but is often accompanied by a large amount of blood. Clumps of cells may occasionally be seen but the pattern is often that of malignant-appearing spindle or ovoid cells. Malignant fibrous histiocytoma also gives a picture of dissociated malignant spindle cells. The major diagnostic dilemma is between spindle cell carcinoma and sarcoma and, when this is a problem, immunocytochemistry for epithelial markers may be necessary.

### 4.5 Prognostic information

Currently, breast FNAC samples are used virtually only for diagnostic purposes. In some centres, however, research studies have indicated that additional evaluation may be possible on this type of sample.

1. Oestrogen and progesterone receptor immunocytochemical assays can be performed on direct smears or cytocentrifuge preparations.<sup>38</sup> It must be borne in mind that this is a labile soluble antigen and preparative methods are critical. Direct smears can be adequately fixed for this test by immersion in formalin while still wet. Drying of the smear can abolish staining and give a false negative result.
2. Grading systems using microscopic or image cytometric methods can be applied to cytological samples.<sup>39,40,41</sup> These studies have indicated that morphological characteristics of tumour cells can be used to provide information that is related to histological grade or to overall prognosis.
3. While the histological type of tumours may be reflected in the cytological appearances, one must bear in mind that the stringent criteria used to define many histological types are based on purity of tumour and architectural features. For these reasons, although sometimes a type can be suggested, consistent typing of breast tumours is not, as yet, possible.
4. Calculation of the standard deviation of nuclear area has been evaluated as a method of increasing sensitivity of diagnosis<sup>42</sup> but is not generally used at present. It is thought by some workers to have prognostic significance.

Information on prognosis or receptors is used in some centres to determine optimum primary therapy where choices between surgery, primary chemotherapy and primary hormone therapy are being made. At present, these types of investigation should be regarded as developmental, and their efficacy in routine clinical practice is still to be determined.



## 5. CORE BIOPSY REPORTING GUIDELINES

This section of this document is designed to assist in classification of needle core biopsy samples. The diagnostic terminology and entities referred to are described in more detail in NHSBSP Publication No 3.<sup>5</sup> Note that the term 'wide bore needle (WBN) biopsy' is used on the reporting forms rather than the term 'core biopsy'.

### 5.1 Core biopsy specimen information and handling

Proper interpretation of core biopsies requires knowledge of details of both clinical and mammographic findings, and this information should be provided on the request form. The completed request form should include clinical details specifying the radiographic sign and the site of biopsies.

1. Biopsies performed from microcalcifications should be x-rayed to determine the presence of calcium. Whenever possible, a radiological comment regarding the presence of representative microcalcification of the mammographic lesion in the sample should be provided along with the specimen x-ray. Examination of further levels should be performed if the calcification is not immediately apparent on histological examination.
2. Optimal fixation is paramount. Biopsies should be placed in fixative solution immediately and sent promptly to the laboratory. Ideally, biopsies should be fixed routinely for a minimum of 6 h, although specimens may be fixed rapidly with the aid of heat or microwave techniques.
3. After processing, haematoxylin and eosin stained sections from one level are usually sufficient for core biopsies from mass lesions, but core biopsies taken for the investigation of microcalcification should have a minimum of three levels examined. In practice, most laboratories choose to examine all core biopsies from screen detected lesions on at least three levels initially. In problematic cases, further levels and immunohistochemical studies may be helpful.

### 5.2 Using the core biopsy (WBN) reporting form

The core biopsy (WBN) reporting forms used may be the separate reporting form (Figure 8) or the form generated specifically by the National Breast Screening System (Figure 9), which comes with the patient details already filled in by the computer. These both request essentially the same information, although the computer generated form has spaces for radiographic information such as kV, mAs, side and type of localisation (palpable, ultrasound, stereotactic or other x-ray guided procedure) in the upper portion. The way in which the National Breast Screening System treats this information is shown in Appendix 1. Information on the nature of the mammographic abnormality and clinical characteristics should be provided by the breast screening radiologist requesting the pathology examination.

## Non-operative diagnostic procedures and reporting

**BREAST SCREENING WIDE BORE NEEDLE BIOPSY FORM**

Surname \_\_\_\_\_ Forenames \_\_\_\_\_ Date of birth \_\_\_\_\_  
 NHS no. \_\_\_\_\_ Screening no. \_\_\_\_\_ Hospital no. \_\_\_\_\_  
 Centre \_\_\_\_\_ Report no. \_\_\_\_\_  
 Side  Right  Left Number of cores \_\_\_\_\_  
 Calcification present on specimen x-ray?  Yes  No  Radiograph not seen  
 Histological calcification  Absent  Benign  Malignant  Both  
 Localisation technique  Palpation  X-ray guided  Ultrasound guided  Stereotactic

Opinion  B1. Unsatisfactory/Normal tissue only  
 B2. Benign  
 B3. Lesion of uncertain malignant potential  
 B4. Suspicion of malignancy  
 B5. Malignant

a.  In-situ  
 b.  Invasive  
 c.  Not assessable

PATHOLOGIST \_\_\_\_\_ Operator taking biopsy \_\_\_\_\_  
 Date \_\_\_\_\_  
 Comment \_\_\_\_\_

**Figure 8** Example of a WBN reporting form.

### 5.3 Recording basic information

#### *Centre/location*

Give the name of the assessment centre, clinic, department, etc where the specimen was obtained.

#### *Side*

Indicate right or left. For specimens from both sides use a separate form for each side.

#### *Number of cores*

If known, indicate the number of core biopsy samples taken.

#### *Calcification present on specimen x-ray?*

Indicate whether there are calcification type opacities visible on the specimen radiograph if available.

#### *Histological calcification*

Indicate whether calcification has been identified in the sample and, if present, whether it is associated with benign or malignant disease.

## Non-operative diagnostic procedures and reporting

BSS: FOLLOW-UP WBN FORM	Sx number:	Name:
Surname:		NHS number:
Forenames:		
Title:		
Date of birth:		Date of diagnosis:
<b>WBN HISTOLOGY</b>		
Date performed:	Location:	Operator:
Hospital code:		Hospital number:
Side:	Comment (max. 65 characters)	
LOCALISATION TYPE:		
kV:		
Total mAs:		
Total exposures:		
Total films:		
	Calcification present on specimen x-ray?:	
Date reported:	Comment (max. 132 characters)	
Pathologist:		
Report number:		
Histological calcif.:		
Number of cores:		
Histological opinion:		
B1 Unsatisfactory/Normal tissue only	B4 Suspicious of malignancy	
B2 Benign	B5 Malignant	
B3 Benign but of uncertain malignant potential		
Malignancy type:		
a In-situ	b Invasive	c Not assessable

**Figure 9** Example of a computer generated WBN reporting form.

### *Localisation technique*

Please choose one of the following terms:

Palpation	Core biopsy guided by palpation
Ultrasound guided	Core biopsy guided by ultrasound
Stereotactic	Core biopsy guided by stereotaxis

### *Pathologist*

The name of the pathologist giving the cytological opinion, who must be registered at the screening office.

### *Operator taking the biopsy*

Enter the name of the person performing the core biopsy.

### *Date*

Enter the date of reporting the slides.

### *Recording the core biopsy opinion*

See section 5.4 on reporting categories.

### *Comment field*

This free text field is included for extra information to be recorded.



### 5.4 Reporting categories

It is important to remember that histological examination of core biopsy samples is performed to fulfil the assessment process role by giving a pathology category classification (B1–5). It is not designed to give a definitive diagnosis, although this is possible in the majority of cases. Thus, while most core biopsy samples can be readily categorised as normal, benign, or malignant, it must be recognised that a small proportion (probably less than 10%) of samples cannot. The following reporting guidelines have been devised in recognition of this and should be used for all screen detected lesions (microcalcification, architectural deformities and mass lesions). It is recommended that this approach should also be adopted for symptomatic practice. It is also important to remember that, although there are five reporting categories, similar to those used in fine needle aspiration cytology (FNAC), these are not equivalent.

These categories are designed to take account purely of the histological nature of the specimen and not the clinical or imaging characteristics. Similarly, it is not feasible for pathology interpretation to judge independently whether a sample is adequate from the mammographic lesion. This judgement requires multidisciplinary discussion. For these reasons there is no inadequate biopsy category for core biopsy specimens.

In some situations, particularly epithelial proliferation and papillary lesions, the choice of diagnostic category should be based on the features present in the sample, and additional guidance is given in Table 4 and Figure 10.

#### *B1 (normal tissue)*

This indicates a core of normal tissue whether or not breast parenchymal structures are present; thus this category is equally appropriate for a core including normal breast ducts and lobules or mature adipose tissue or stroma only. A B1 report should include a description of the components present, and comment should be made regarding the presence of breast epithelial structures.

Normal histology may indicate that the lesion has not been sampled. This is, however, not necessarily so. In the case of certain benign lesions, such as hamartomas and lipomas, apparently normal histological features would be expected on core biopsy. Minor architectural distortions seen mammographically may also result in minimal changes such as a slight increase in stromal fibrosis on biopsy.

Cores with B1 diagnoses may contain microcalcification, for example within involutinal lobules. It is important in these cases that discussion between pathology and radiology colleagues is undertaken to confirm the appropriateness of the microcalcification in the histological specimen. Small foci of calcification within involuted lobules are common and frequently too small to be visible mammographically. Thus, a report that merely records the presence of this calcification without additional comment on its nature, size and site may be misleading and lead to false reassurance. It is evident that microcalcification, either singly or in clusters, less than 100  $\mu$ m in diameter is not visible radiologically.<sup>43</sup>

## Non-operative diagnostic procedures and reporting

**Table 4** Epithelial proliferative lesions

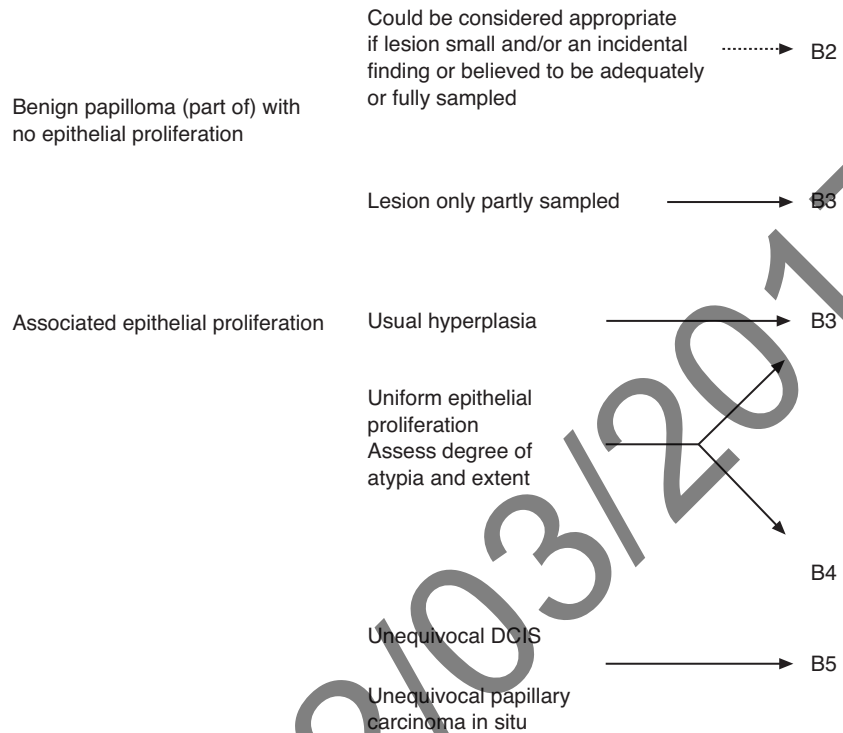
I	Usual hyperplasia		B2
II	Microfocal epithelial atypia in lobules	Minimal degree of atypia	B2
		Moderate degree of atypia	B3
		High grade atypia	B4
III	Lobular neoplasia	Typical	B3
		Indistinguishable from low grade DCIS (rare)	B5
IV	Low and intermediate grade atypical epithelial proliferation		
	1. One or a small number of spaces involved	Sufficiently worrisome not to ignore, but lacking in extent or degree of duct/lobule involvement to classify as suspicious of DCIS. Similar features in a surgical excision would be classified as ADH	B3
	2. Greater extent/multiple spaces	Features of low grade DCIS in architecture and epithelial character but insufficient for confident diagnosis of DCIS	B4
	3. Multiple spaces	Complete involvement of at least two spaces with definite features of DCIS	B5
V	High grade atypical epithelial proliferation	Part of one space	B4
		One or more complete spaces involved. Caution is advised when a single profile only is present. Additional features such as necrosis may be useful	B5

Exceptionally, some specimens may be classified as uninterpretable, for example because of excessive crush artefact or composition of blood clot only. Such samples should also be classified as B1.

### *B2 (benign lesion)*

A core is classified as B2 when it contains a benign abnormality. This category is appropriate for a range of benign lesions, including fibroadenomas, fibrocystic changes, sclerosing adenosis and duct ectasia, and extends to include other non-parenchymal lesions such as abscesses and fat necrosis.

In some cases, it may be difficult to determine whether a specific lesion is present, for example if minor fibrocystic changes are seen. The multidisciplinary approach is once again vital in these cases to determine whether the histopathological features are in keeping with the radiological and clinical findings. It may be appropriate and prudent to classify the lesion as B1, rather than B2, if only very minor changes are present; such histopathological features would clearly be insufficient



It is anticipated that the majority of papillary lesions will be designated B3.

**Figure 10** Papillary lesions.

to explain a well-defined mass lesion and classification as B2 would be inappropriate.

*B3 (lesion of uncertain malignant potential)*

This category mainly consists of lesions which may provide benign histology on core biopsy but are known to show heterogeneity or to have an increased risk (albeit low) of associated malignancy.

*Atypical epithelial proliferations (atypical ductal hyperplasia, ADH)*

Included under a B3 classification are atypical epithelial hyperplastic lesions in which a uniform population of cells arranged in an appropriate manner involves one space or partially involves two or more spaces. These appearances should be sufficiently structured to raise the possibility of low grade DCIS but insufficient in the tissue available to fulfil the diagnostic criteria.<sup>5</sup> There is a range of severity from those which are insufficient for a definite diagnosis of DCIS but highly suspicious to those which only show a minor degree of atypia, normally architectural, which requires further assessment, and judgement of appropriate categorisation B3 or B4 is required.

The definition of atypical ductal hyperplasia is derived from surgical resection specimens and relies on a combination of histological, morphological and size extent criteria. For this reason, accurate diagnosis of ADH is not possible on core biopsy. It has, however, been shown that core biopsy samples which include atypical epithelial proliferative foci of insufficient extent for classification as DCIS may,

on subsequent surgical resection, form part of an established in situ neoplastic lesion with or without associated invasion. This view is based on several studies that describe the subsequent surgical diagnoses in cases described as ADH in non-operative core biopsy. In over 50% of cores, surgical excision biopsy has shown either in situ or invasive carcinoma.<sup>44</sup> This is not surprising as ADH is basically defined as an epithelial proliferation showing the features of low grade DCIS, but in fewer than two spaces or less than 3 mm in diameter. The limited tissue sampling that can be undertaken by core biopsy guns (often by stereotactic methods for foci of microcalcification) may thus provide insufficient material for definitive diagnosis of low grade DCIS if only a few spaces are obtained. In these cases a diagnosis of atypical intraductal epithelial proliferation and a classification of B3 of uncertain malignant potential or B4 suspicious of malignancy should be made dependent on the severity and extent of the lesion (see Table 4).

### *Lobular neoplasia*

A small cell regular epithelial proliferation within lobules that is considered by the pathologist to represent lobular neoplasia (ALH/LCIS) should be classified as B3. In common with ADH, the criteria used to distinguish between atypical lobular hyperplasia (ALH) and lobular carcinoma in situ (LCIS) are derived from surgically resected tissue. Accurate distinction may not be possible in a limited core biopsy sample. This process does not have the same management implications as a diagnosis of DCIS or invasive malignancy and does not per se require therapeutic excision. Lobular neoplasia is, however, most frequently a coincidental finding in a core biopsy from a screen detected lesion, and multidisciplinary discussion is essential, as the abnormality identified radiologically may not be represented. These cases must be managed cautiously.

On occasion it may be impossible to classify a small cell epithelial proliferation in lobules and/or ducts as either lobular neoplasia or low grade DCIS, and in these circumstances a numerically higher category (B4 or B5) is prudent and should be considered.

### *Phyllodes tumour*

Fibroadenomatoid lesions with cellular stroma, stromal overgrowth and possibly some mitotic activity suggesting a phyllodes tumour should also be designated B3. Thus, the presence of a cellular stroma within a fibroepithelial lesion should prompt a search for other features that may aid in discrimination from a fibroadenoma. In practice, however, this distinction is often impossible, and careful appraisal of the entire clinical picture will usually allow appropriate management to be undertaken.

### *Papillary lesions*

Papillary lesions may also show significant intralesional heterogeneity, and the limited sampling achieved with core biopsy may miss areas of in situ cancer. Thus, the majority of these lesions should also be designated B3 of uncertain malignant potential. On rare occasions when a small lesion has been very widely sampled and submitted for

pathological examination, a benign B2 classification may be considered. Conversely, when a sample of a papillary lesion in a core biopsy shows atypia, for example strongly suspicious of papillary carcinoma in situ, a B4 designation may occasionally be more appropriate (see Figure 10).

### *Radial scar/complex sclerosing lesion*

Biopsies which show features of a radial scar/complex sclerosing lesion such as areas of hyalinisation, elastosis or tubular entrapment with epithelial proliferation should be categorised as B3. Although still a matter of debate, many authorities believe that a proportion of these lesions are associated with malignancy. Thus, unless the sclerosing lesion is very widely sampled, the process should be designated B3 as the presence of an associated area of DCIS or invasive carcinoma cannot be excluded.

### *B4 (suspicious)*

Technical problems such as crushed or poorly fixed cores that contain probable carcinoma but cannot provide the definitive diagnosis are best included as B4. Similarly, apparently neoplastic cells contained within blood clot or adherent to the outer aspect of the sample should be classified as B4 suspicious. Very small foci of invasive carcinoma in which there is insufficient material to allow immunocytochemical studies may also reasonably be assigned to this category.

A complete single duct space bearing an unequivocal high grade atypical epithelial proliferative process can be classified as B5 malignant. However, care must be taken if one or only part of a duct space is seen to contain a highly atypical epithelial process (particularly if no necrosis is present); this may be regarded as suspicious rather than definitively malignant. In particular, great care should be taken if the epithelial cells show any features of an apocrine phenotype, which may represent an atypical apocrine proliferation rather than DCIS.

Another lesion that can be allocated to this category is a non-high grade intraductal proliferation with a significant degree of atypia probably representing intermediate or low grade DCIS; in this case, relatively few duct spaces are involved. A pragmatic approach is usually required by reporting an atypical intraductal proliferation and qualifying this according to the degree of suspicion, ie 'at least ADH, probably low grade DCIS', and on the basis of extent or severity of atypia allocating the case either to the B3 or to B4 category (see also B3 above and Figure 10).

The management of cases classified as B4 will usually be either diagnostic excision biopsy of the area or repeat core biopsy sampling to obtain definitive diagnosis. **Definitive therapeutic surgery should not be undertaken as a result of a B3 or B4 core biopsy diagnosis.**

### *B5 (malignant)*

This category is appropriate for cases of unequivocal malignancy on core biopsy. Further categorisation into in situ and invasive malignancy

should be undertaken whenever possible. Other forms of malignancy such as malignant lymphoma should also be classified as B5.

### *Ductal carcinoma in situ*

One of the benefits of core biopsy is that it can allow distinction between in situ and invasive carcinoma. It should, however, be borne in mind that, as a result of sampling error, the exclusive presence of DCIS in the core does not exclude the possibility of an invasive focus being present. In approximately 20% of cases sampled by standard methods coexisting invasive carcinoma will be identified in the subsequent surgical excision specimen.<sup>45</sup>

The nuclear grade, architecture and the presence of necrosis of the DCIS can be indicated on the core biopsy report. In particular, the presence of associated calcification should be recorded.

### *Lobular neoplasia*

Lobular neoplasia is included in the B3 category, as it does not have the same management implications as a diagnosis of DCIS or invasive malignancy. In exceptional circumstances, lobular neoplasia may be impossible to distinguish from small cell solid DCIS and may be classified as B5 (see also B3 above).

### *Invasive carcinoma*

An advantage of core biopsy over FNAC is the ability to diagnose invasion positively. Invasive mammary carcinoma can be unequivocally identified in core biopsy with a positive predictive value of 98%.<sup>45</sup> As noted above, however, the negative predictive value for invasion is only 80% when only DCIS is identified.

## **5.5 Calcification in core biopsy**

All cores taken for microcalcification should undergo immediate specimen x-ray, enabling the operator to repeat the biopsy if no calcification is seen. While being x-rayed, cores may be moistened with saline to prevent desiccation, but this should be blotted prior to film exposure or resolution may be adversely affected. Cores in which microcalcification is detected may be marked with a vital dye or, preferably, sent to the laboratory in a separate specimen pot, allowing 'targeted' examination to deeper levels should calcification not be detected in the initial series of sections. It is important to remember that calcium oxalate crystals are often indistinct on routine haematoxylin and eosin sections but are easily seen on polarisation. See also section 5.4 on reporting and multidisciplinary discussion of calcification in B1 (normal tissue).

## **5.6 Problems and pitfalls in diagnosis**

Diagnostic pitfalls and problems in diagnosis in core biopsy include many of the lesions that cause difficulties in FNAC diagnosis (see page 24). Other lesions, however, may present particular diagnostic problems in core samples (see Table 5).

### *5.6.1 Minor degrees of epithelial atypia*

Mild atypia of epithelium within lobular units is one of the commonest problems encountered in core biopsy samples. Care must be taken not to overdiagnose such minimal degrees of atypia, which may represent



usual epithelial hyperplasia, apocrine change or reactive changes (for example adjacent to a previous sampling procedure). Conversely, more severe degrees of atypia must be sought, as these may reflect cancerisation of lobules by high grade DCIS. The degree of atypia should be helpful in distinguishing the process, and the nuclear chromatin and presence of mitoses (although rarely seen) may aid in the diagnosis.

Similarly, usual epithelial hyperplasia (UEH) and other forms of benign hyperplasia such as that of gynaecomastoid type are commonly seen in cores from benign fibroadenomas. Such cores often show apparent discohesion due to the trauma of the core biopsy sampling process, and 'telescoping' of epithelium is seen within the duct spaces; thus, UEH may resemble a hyperplastic process. As with UEH in surgical excision specimens, the lack of uniformity and distribution/streaming of the epithelial cells with bland nuclear features and paucity of mitoses is of assistance in reaching a diagnosis. Atypical ductal hyperplasia should not be diagnosed in these cases unless uniformity of nuclear size and shape and regular, evenly placed nuclei are seen. Usual epithelial hyperplasia of gynaecomastoid type with a micropapillary architecture should not be mistaken for micropapillary ADH/DCIS.

### 5.6.2 *Apocrine atypia and apocrine DCIS*

Apocrine atypia, particularly in association with a sclerosing lesion such as sclerosing adenosis (so-called 'apocrine adenosis'), may be especially difficult to identify correctly in non-operative diagnostic samples. In core biopsy, large nuclei, often with prominent nucleoli, may be mistaken for DCIS if pleomorphism is also present. The typical granular eosinophilic cytoplasmic appearance of apocrine cells should be sought. Pure apocrine DCIS is relatively rare, and when an apocrine proliferation is seen within ducts in a core biopsy, additional features of malignancy such as significant atypia, intraluminal necrosis and the presence of mitoses as well as multiple duct involvement should be sought for confirmatory evidence. Multiple duct involvement indicating a more extensive lesion may provide further supportive evidence. Mild or moderate degrees of apocrine proliferation with atypical features in a duct space should be assessed with caution, and it may be prudent not to record a definite diagnosis but to classify such a process as B3 (uncertain malignant potential). Conversely, papillary apocrine change should not be mistakenly classified as other than benign.

### 5.6.3 *Lactational change*

Focal lactational change may be seen in women who are neither lactating nor pregnant and, indeed, are nulliparous and/or post-menopausal. The involved acini are usually lined by plump vacuolated cells with a 'hobnail' architecture but may, less frequently, appear atypical with irregular, large or pyknotic nuclei. The epithelial cells may appear degenerative, and rarely the benign nature of the process may be mistaken for cancerisation of lobules by DCIS. The recognition of the vacuolation of the cytoplasm and the typical hobnail architecture will enable the correct diagnosis to be established.



### 5.6.4 *Sclerosing lesions/ tubular carcinoma*

There is a risk of overdiagnosis of invasive carcinoma when confronted by sclerosing adenosis in a core biopsy, particularly as the normal lobular arrangement may be less apparent than on an excision biopsy specimen. Immunohistochemical staining with collagen IV, laminin and/or smooth muscle actin to demonstrate the presence of a basement membrane and a dual epithelial/myoepithelial layer respectively can be extremely useful in this situation.

The stromal appearances may be helpful in achieving a correct diagnosis; sclerosing lesions do not induce the fibroblastic/desmoplastic reaction generally seen in an invasive carcinoma. Radial scars/complex sclerosing lesions have an eosinophilic fibrotic and elastotic central focus with entrapped tubules. These elements have, however, a surrounding myoepithelial layer. In difficult cases, immunohistochemistry for smooth muscle actin may be invaluable; the absence of the myoepithelial component in tubular carcinomas can be confirmed.

### 5.6.5 *Stromal proliferations and spindle cell lesions*

Stromal proliferations may cause difficulties in diagnosis in core biopsy samples. Occasionally, a second biopsy sample taken from a patient may show fibroblastic proliferation; this may represent the target lesion but could also reflect tissue reaction and repair at the previous biopsy site. If the lesion represents the core site, an associated histiocyte reaction or indeed fat necrosis may be present and haemosiderin-laden macrophages can be seen. Sometimes a fibroblastic stroma may be identified in a sample from a patient who has not undergone previous FNAC or core biopsy and which may represent a spindle cell proliferation such as a fibromatosis or part of a spindle cell tumour such as a nerve sheath tumour or myofibroblastoma. A stromal proliferation may also be seen in phyllodes tumours and evidence for an epithelial component should be sought, for example by performing additional levels. Metaplastic carcinomas or rarely primary sarcomas (see section 5.7) may also mimic stromal proliferations, and a high index of suspicion may enable confirmatory diagnosis by immunohistochemical examination with a range of anti-cytokeratin antibodies (at least one broad spectrum and a high molecular weight cytokeratin, such as MNF116 and LP34). Immunohistochemistry may prove unhelpful and the multidisciplinary approach must be applied to the clinical, radiological and histopathological features. When a definitive histological diagnosis cannot be made the abnormality should be reported as a spindle cell lesion of uncertain histogenesis or nature and classified as B3.

### 5.6.6 *Fibroepithelial tumours*

As noted above, phyllodes tumours may rarely be difficult to distinguish from other stromal lesions. More commonly, the differential diagnosis lies between a cellular benign fibroadenoma and a phyllodes tumour. Features including stromal atypia, if present, can be useful, but the degree of cellularity of the stroma is the most valuable feature to assess. In rare cases it is not possible to distinguish between these two lesions and the sample should be reported as a 'fibroepithelial lesion' and classified as B3, to avoid underdiagnosis of a phyllodes tumour. These cases should be discussed at multidisciplinary meetings.

**Table 5** Common causes of false positive and negative diagnoses

**Common causes of false positive diagnosis**

Sclerosing adenosis or radial scar/CSL mistakenly diagnosed as tubular carcinoma  
Apocrine atypia in lobules, ducts or sclerosing lesions mistakenly diagnosed as DCIS  
Chronic inflammation mistakenly diagnosed as infiltrating lobular carcinoma  
Invasion mistakenly diagnosed in DCIS  
Radiotherapy effect mistakenly diagnosed as carcinoma

**Common causes of false negative diagnosis**

Tubular carcinoma mistakenly diagnosed as sclerosing adenosis or radial scar/CSL  
Infiltrating lobular carcinoma mistakenly interpreted as chronic inflammation or missed  
Radiotherapy effect with missed foci of carcinoma  
Metaplastic carcinoma mistakenly diagnosed as a stromal proliferation/fibroblastic scar

---

**5.6.7** *Radiation induced changes*

Radiotherapy changes to the breast may be difficult to differentiate from foci of recurrent or residual carcinoma, both in situ and invasive. The radiation induces a degree of atypia of the breast epithelium but also in the histiocyte population, which is prominent as a result of the radiotherapy and also recent surgery. The macrophages may also show degenerative features. Thus, carcinoma cells can conversely mimic macrophages. Immunocytochemistry can be helpful in difficult cases as irradiated neoplastic cells retain cytokeratin expression whereas macrophages demonstrate a histiocytic phenotype, for example CD68 reactivity.

**5.6.8** *Infiltrating lobular carcinoma*

Small foci of invasive lobular carcinoma can be missed in histological sections and be dismissed as chronic inflammation or stromal cells. The targetoid infiltrative pattern of classical lobular carcinoma may be of assistance, but a reactive lymphocyte process can also have a periductal or perilobular distribution. Cytokeratin immunohistochemistry, to demonstrate the neoplastic cells, is of value in difficult cases, but recognition of the abnormal cell proliferation requires vigilance as the features can be subtle.

**5.7** **Rare lesions**

**5.7.1** *Lymphoma*

As noted above, malignant lymphoma may rarely be identified in core biopsies and should be classified as B5 malignant.

The majority of these lesions are of high grade B-cell morphology, and these may mimic epithelial malignancy. As in other organs, the cells frequently show less cohesion and a higher nuclear to cytoplasmic ratio and do not demonstrate the architectural features of carcinoma, such as tubule formation. To avoid misclassification as carcinoma, however, the correct diagnosis must be considered and can be supported by immunohistochemistry (CD45, CD20, CD3, CD30, etc) to demonstrate the appropriate phenotype.

Low grade lymphomas may be more difficult to distinguish, mimicking a chronic inflammatory process. Infiltration of the lobular epithelium should be sought, and the degree of lymphoid infiltrate, if high, should raise the possibility of a neoplastic process. A panel of lymphoid markers may be necessary to demonstrate the immunophenotype of the cells present and to allow correct diagnosis.

### 5.7.2 *Metastasis to the breast*

Metastasis to the breast from malignancies derived elsewhere is well recognised although rarely biopsied. A full clinical history is essential to avoid misdiagnosis of a metastatic adenocarcinoma as a primary breast carcinoma. Lesions which are recognised as metastasising to the breast include lung, ovarian and renal carcinomas, but non-epithelial malignancies such as melanoma, myelomas and rhabdomyosarcomas may also be seen.

A panel of antibodies frequently allows identification of the likely site of a metastatic adenocarcinoma and enables appropriate clinical investigation/management. Breast carcinomas usually express cytokeratin 7 and 18 (and not cytokeratin 20), epithelial membrane antigen and carcinoembryonic antigen (CEA)/non-specific cross-reacting antigen (NCA), and approximately 80% will express oestrogen receptor.

### 5.7.3 *Sarcomas*

Primary breast sarcomas are rare. They most commonly originate in association with phyllodes tumours, but in core biopsy specimens an epithelial component is often not present. The most common phyllodes associated sarcomas seen are liposarcoma and fibrosarcoma, although other differentiation, including osteosarcoma, chondrosarcoma and rhabdomyosarcomas, can be identified. Angiosarcomas may be a cause of false negative diagnosis as they may be relatively subtle and bland and may be mistaken for radiotherapy changes, particularly when they occur in this situation in the treated breast. Primary leiomyosarcoma (and leiomyoma) may be found in the breast; the latter most commonly in a retroareolar site. All these lesions can be difficult to diagnose definitively in core samples. A high index of suspicion and judicious use of immunohistochemistry can facilitate or support a diagnosis, but non-diagnostic classification as B3 or B4 is often prudent.

## 5.8 **Assessment of prognostic information**

Grading on core biopsy can be performed and is reasonably accurate. Current evidence suggests that concordance between grade on core biopsy and that in the definitive excision specimen can be achieved in approximately 75% of cases. It should, however, be made clear to the clinicians that the grade may differ (almost invariably by only one level) from that in the subsequent resection specimen. Mitotic count in particular may be lower in the core biopsy than in the excision specimen, therefore leading to underscore on the core. Tumours may also often be typed according to the most common categories, such as ductal/no specific type (NST) or classical lobular carcinoma. Invasive carcinoma of special type, however, cannot be accurately predicted although this may be suggested with some degree of accuracy in the core biopsy report.

**5.9 Oestrogen receptor (ER) assessment**

ER assessment on core biopsies has been shown to correlate with the subsequent surgical excision specimen<sup>46</sup> and also to predict response to hormone therapy.<sup>47</sup> As with determination on excision biopsy samples, a standard protocol and method of assessment should be used (see Appendix 2).

Archived on 22/03/2017

## 6. QUALITY ASSURANCE

### 6.1 Definitions

The definitions shown in Table 6 are intended to relate to the clinical evaluation of the effectiveness of FNAC or core biopsy rather than specifically to evaluation of laboratory performance. Thus, inadequate (C1) FNAC or normal (B1) core biopsy results are not excluded from the calculations as in some evaluations in the literature. Pathologists wishing to evaluate their statistics purely to see their own accuracy in diagnosis may wish to calculate the figures slightly differently.

**Table 6** Definition of quality assurance measures for cytology and core biopsy

Absolute sensitivity	The number of carcinomas diagnosed as such (C5 or B5) expressed as a percentage of the total number of carcinomas sampled
Complete sensitivity	The number of carcinomas that were not definitely negative or inadequate on FNAC or core expressed as a percentage of the total number of carcinomas
Specificity (full)	The number of correctly identified benign lesions (the number of C2 or B2 results minus the number of false negatives) expressed as a percentage of the total number of benign lesions aspirated
Positive predictive value of a C5/B5 diagnosis	The number of correctly identified cancers (number of C5 or B5 results minus the number of false positive results) expressed as a percentage of the total number of positive results (C5 or B5)
Positive predictive value of a C4/B4 diagnosis	The number of cancers identified as suspicious (number of C4 or B4 results minus the number of false suspicious results) expressed as a percentage of the total number of suspicious results (C4 or B4)
Positive predictive value of a C3/B3 diagnosis	The number of cancers identified as atypia (number of C3 or B3 results minus the number of benign atypical results) expressed as a percentage of the total number of atypical results (C3 or B3)
False negative case	A case that turns out (within a period of 3 years) to be carcinoma despite a negative cytology or core result (this will by necessity include some patients in whom an area different from the lesion was sampled but who present with an interval cancer)
False positive case	A case that was given a C5 or B5 result and which turns out at open surgery to be a benign lesion (including atypical hyperplasia)
False negative rate	The number of false negative results expressed as a percentage of the total number of carcinomas sampled
False positive rate	The number of false positive results expressed as a percentage of the total number of carcinomas sampled
Inadequate rate for FNAC	The number of inadequate FNAC specimens expressed as a percentage of the total number of cases aspirated

### 6.2 How to calculate quality assurance statistics

Most of the computer systems in use in the National Health Service Breast Cancer Screening Programme (NHSBSP) can calculate quality assurance (QA) statistics automatically from the data recorded in the screening database, cross-referenced with the histology or subsequent outcome. A software routine (CQA in the case of cytology, BQA in the case of core biopsy) can generate reports for quality assurance purposes. Examples of the reports are shown in Tables 7 and 8. There is also a further routine (NDQA) that combines the two routines, and calculates performance measures for non-operative diagnostic procedures. This routine takes the worst diagnosis of the two techniques where both have been performed on the same patient and calculates the same parameters as the CQA and BQA routines.

## Non-operative diagnostic procedures and reporting

### 6.2.1 Further rules used in deriving quality assurance statistics

Cases with both a non-invasive cancer and an invasive cancer in the pathology database should count as invasive unless they are on opposite sides, in which case they should be counted twice (once in each).

In cases with a malignant diagnosis the malignant findings override benign findings unless they are on opposite sides.

Cases with open episodes are listed at the bottom of the report.

Tables 7 and 8 can be produced for internal QA purposes for all clients, all tests, all cases/tests performed by any one aspirator, all cases/tests reported by any one pathologist and all cases/tests by any one localisation method (palpable, ultrasound, x-ray guided (perforated plate) or stereotactic). The tables can also be produced for any date range, the date taken being the date of needling (or, if that is not available, the date of reporting) and for any geographic location.

The tables can be produced for any or all of the radiological appearances: spiculated mass, rounded opacity, microcalcification, stellate lesion or asymmetrical density.

It is possible to request a report that lists the screening numbers of clients involved in any of the cells in Table 7. For example, a list of cases in cell no 26 is produced with the title: 'Cases with C4 cytology (B4 results) not biopsied but with closed episodes – please check'.

Note that all cases in box 25 are regarded as malignant and that all cases in box 27 are regarded as benign.

**Table 7** Cytology /core biopsy quality assurance standard report

TOTAL CASES SCREENED IN PERIOD .....

TOTAL ASSESSED .....

TOTAL FNA (WBN) PERFORMED .....

<b>Cytology</b>						
FNAC	C5	C4	C3	C2	C1	Total
WBN	B5	B4	B3	B2	B1	Total
<b>Histology</b>						
Total malignant	Box 1	Box 2	Box 3	Box 4	Box 5	Box 6
Invasive	Box 7	Box 8	Box 9	Box 10	Box 11	Box 12
Non-invasive	Box 13	Box 14	Box 15	Box 16	Box 17	Box 18
Total benign	Box 19	Box 20	Box 21	Box 22	Box 23	Box 24
No histology	Box 25	Box 26	Box 27	Box 28	Box 29	Box 30
Total C/B results	Box 31	Box 32	Box 33	Box 34	Box 35	Box 36



The entry in each box (numbered 1 to 36) in Table 7 is calculated either from the numbers of FNA with a C code (C1, C2, etc) cross-referenced with the worst histology diagnosis or from the numbers of WBN with a B code (B1, B2, etc) cross-referenced with the worst histology diagnosis.

The table should be produced for all FNA tests (headed 'all tests') and also for all patients (headed 'all patients'): if two FNA or WBN records are present, the highest C or B number is taken. Only closed episodes should be used.

The figures in the tables are then used to calculate values for each of the QA measures in the cytology document. The calculations are shown in Table 8 (numbers in bold correspond to box numbers in Table 7).

It is recognised that the specificities and false negative rates are approximate and will be more accurate the longer the date range of the analysis is from the date printed.

### 6.3 Cytology and core biopsy performance figures

Suggested thresholds for cytology and core biopsy performance are shown in Tables 9 and 10 respectively. These figures will obviously depend on sampling techniques and the experience and care of the aspirator<sup>48</sup> and will vary widely between units.

The previous version of the *Guidelines for Cytology Procedures and Reporting in Breast Cancer Screening*,<sup>3</sup> now incorporated in this text, gave figures for performance of cytology drawn from the literature and reviewed also in the *European Journal of Cancer*.<sup>49</sup> Since that time there have been two published surveys of performance of, firstly, cytology<sup>50</sup> and, subsequently, both cytology and needle core biopsy.<sup>51</sup> Currently, a further study of performance is under way, and provisional figures of current performance are given in Tables 9 and 10.

### 6.4 How to interpret the results

The performance measures are interrelated, and strategy to improve one aspect of performance will affect others. Thus, an attempt to reduce the inadequate rate will often increase the number of suspicious reports, attempts to improve the sensitivity are likely to increase the false positive rate, attempts to improve the specificity will increase the false negative rate, and so on. Also, attempts to reduce the benign biopsy rate by not biopsying the majority of lesions called benign on cytology will reduce the specificity where this is based on benign histology results rather than on all aspirated cases.

The most common problem encountered in the NHSBSP surveys<sup>50,51</sup> appears to be low sensitivities combined with high false negative rates and high inadequate rates from lesions that subsequently turn out to be cancer. This combination of statistics suggests a problem with the accurate localisation of lesions for aspiration.<sup>49</sup> A significant proportion of these lesions will have been palpable or thought to be palpable as an area of thickening; aspiration of these areas without radiological guidance may account for some of the problems. It is of interest to note that, in centres where cytology has not been as useful in non-operative



## Non-operative diagnostic procedures and reporting

---



---

**Table 8** Calculation of cytology performance measures

<b>Absolute sensitivity</b> (this assumes that all unbiopsied C5 or B5 results are carcinoma and are treated with primary chemotherapy or hormonal therapy)	$\frac{1+25}{6+25} \times 100\%$
<b>Complete sensitivity</b>	$\frac{1+2+3+25}{6+25} \times 100\%$
<b>Specificity</b> (biopsy cases only)	$\frac{22}{24} \times 100\%$
<b>Specificity</b> (full) (this assumes that all cases of atypia (C3 or B3) which are not biopsied are benign)	$\frac{22+28}{24+27+28+29} \times 100\%$
<b>Positive predictive value</b> (C5/B5 diagnosis)	$\frac{31-19}{31} \times 100\%$
<b>Positive predictive value</b> (C4/B4 diagnosis)	$\frac{2}{32-26} \times 100\%$
<b>Positive predictive value</b> (C3/B3 diagnosis)	$\frac{3}{33} \times 100\%$
<b>Negative predictive value</b> (C2/B2) (at present this parameter is not calculated by the various routines)	$\frac{34-4}{34} \times 100\%$
<b>False negative rate</b> (this excludes inadequate results)	$\frac{4}{6+25} \times 100\%$
<b>False positive rate</b>	$\frac{19}{6+25} \times 100\%$
<b>Inadequate FNA rate and B1 core biopsy rate</b>	$\frac{35}{36} \times 100\%$
<b>Inadequate FNA rate and B1 core biopsy rate from cancers</b>	$\frac{5}{6+25} \times 100\%$
<b>Suspicious rate</b>	$\frac{32+33}{36} \times 100\%$
<b>Core biopsy miss rate from cancers</b>	Sum of false negative rate and B1 core biopsy rate from cancers

**Table 9** Suggested thresholds for cytology performance (where therapy is partially based on FNAC)

	<b>Minimum (%)</b>	<b>Preferred (%)</b>	<b>Current median (%)</b>
Absolute sensitivity (AS)	>60	>70	57.1
Complete sensitivity (CS)	>80	>90	81.5
Specificity (full) (SPEC) (including non-biopsied cases) (as calculated above)	>55	>65	58.4
Positive predictive value (+PV)	>98	>99	99.6
False negative rate (F-)	<6	<4	6.3
False positive rate (F+)	<1	<0.5	0.2
Inadequate rate (INAD)	<25	<15	23.4
Inadequate rate from cancers	<10	<5	9.8
Suspicious rate	<20	<15	15.8

**Table 10** Suggested thresholds for core biopsy performance

	<b>Minimum (%)</b>	<b>Preferred (%)</b>	<b>Current median (%)</b>
Absolute sensitivity (AS)	>70	>80	76.4
Complete sensitivity (CS)	>80	>90	84.5
Specificity (full) (SPEC) (including non-biopsied cases) (as calculated above)	>75	>85	81.2
Positive predictive value (+PV)	>99	>99.5	100
False positive rate (F+)	<0.5	<0.1	0
Miss rate (B1 + B2) from cancer	<15	<10%	15.1
Suspicious rate	<10	<5	4.8

diagnosis, there has been a swing towards the use of core biopsy,<sup>52</sup> as is commonly reported in publications from the United States.<sup>53</sup> Audit of core biopsy in the NHSBSP shows similar variability in practice.<sup>51</sup> Some units are using the two techniques to complement each other and are achieving higher non-operative diagnosis rates in difficult cases.<sup>54</sup> This can be especially useful in lobular and tubular carcinomas where cytology is less able to give an unequivocal diagnosis.<sup>36,51,55</sup>

In general, the cytological performance of pathologists as assessed by the positive predictive values is good, although some pathologists are clearly being cautious in diagnosis. This caution can be inferred from the statistics in the units with high positive predictive values for C4 and C3 diagnoses and also in units which have a high suspicious rate. It

should be noted that caution by pathologists may be a function of their experience in the technique, previous experience of false positive and false negative results, poorly cellular samples or local differences in treatment protocols when faced with a C5 diagnosis.

High inadequate rates without a corresponding increase in the inadequate rate from cancers can be seen in occasional units. In these units, a high proportion of the women who were recalled for assessment had a needling procedure. This suggests that, in these units, the clinicians were needling lesions with a low predictive value for malignancy in order to reassure either the patient or themselves. This is not necessarily a problem, and therefore the crude inadequate rate may not be a good measure of aspiration technique. A better measure appears to be the inadequate rate from lesions which turn out subsequently to be cancer or, for core biopsy, the miss rate (see above).

### 6.5 Education and training

The Training and Education Subgroup of the National Coordinating Group for Breast Screening Pathology is responsible for organising breast screening pathology courses including a biannual non-operative diagnosis course. Information on these courses can be obtained from Nottingham International Breast Education Centre. In addition, the British Society for Cervical Cytology (BSCC) and other specialist centres organise workshops or courses in fine needle aspiration cytology in Edinburgh, Guildford, Nottingham and at the Royal Marsden Hospital. Additional experience may be gained by secondment to neighbouring centres of expertise and participating in external quality assurance (EQA) schemes. It is recognised that courses can only provide baseline knowledge, and acceptable levels of performance, particularly in cytological diagnosis, can only be realistically achieved by experience in routine practice. Regular self-audit of non-operative diagnosis results should be undertaken and is of educational value.

## APPENDIX 1: HOW THE NATIONAL SCREENING SYSTEM TREATS CYTOLOGY DATA

Please note that, owing to a conversion error in the National Breast Screening System, some FNAC results recorded before January 1991 may be miscoded. See below for further details.

The National Breast Screening Computer System (NBSS), designed in Oxford and used in most regions for the recording of breast screening, stores fine needle aspiration results as a diagnostic set (FINE) and core biopsy results as a diagnostic set (WIDE). These diagnostic sets are part of the assessment module. Specimen type and FNAC/core biopsy diagnosis are recorded with the comment field, and radiological information is also recorded. The method of localisation of the lesion, whether by clinical, ultrasound, perforated plate or stereotactic, is recorded and the radiation dosage (number of exposures, films, kV and mAs) is similarly recorded. The system records an FNAC/core biopsy opinion (C1/B1, C2/B2, etc) and also an overall opinion after full assessment, which is entered after a multidisciplinary decision is taken. This opinion then forms the basis for an action, which may range from routine recall (RR) to surgical treatment (ST) depending on the outcome of assessment. The date of the sampling and report, the pathologist, operator and specimen number are also recorded.

The FNAC/core biopsy opinion forms a part of a field in the software, which is called the 'episode endpoint'. In this FNAC/core biopsy is not treated the same as in the program itself, being separated from assessment. Examples of the coding of this field would be S+, Aabn, C-, W-, H- where a lesion was thought positive on screening films (S), was thought benign in nature after assessment (A), was thought overall to be benign after cytology (note that this does not necessarily mean that cytology was benign) (C), was thought to be benign after core biopsy (W) (this does not necessarily mean that the core was benign) and was histologically benign (H), or S+, A+, C+, W+, H+ for a malignancy identified as such by screening (S), assessment (A), cytology (C) (this does not mean that cytology was necessarily malignant), core biopsy (W) (this does not necessarily mean that core biopsy was malignant) and histology (H). The system uses bespoke downloads ('file of episodes', 'file of assessment details', etc) or the 'Co-Writer'<sup>TM</sup> report generator to produce custom reports on request.

Because of a problem on conversion of the database from the version 2.0 to version 2.1 whereby the assessment and cytology record structures were changed, a number of cytology results that were originally 'benign' on the system were recoded as 'suspicious probably benign (C3)'. This error occurred at date of conversion in each unit, which generally varies between units from August 1990 and December 1990, although in some units may be even later than this. Records entered before that date may

be subject to this error, and data obtained from the computer before 1991 may contain a high number of suspicious results because of this data conversion. It is therefore recommended that data downloaded or patient episodes reviewed from the national system pertaining to results entered before 1991 are treated with caution. Also, some of these records may be lacking certain data items that were not part of the previous software. It is not possible to run a general correction for these results as the dates at which the conversion was done varies from unit to unit, but it is possible to run an FNAC program that will list all FNACs performed, with their dates, to allow correction of these. If this is required then information may be obtained from the local Oxford Level Two Support Team. This error does not apply to other systems, but information on those may be obtained from the appropriate computer management teams.

In version 3 of the software, core biopsy results were removed from the biopsy and treatment records (BT) and converted into WBN results in the new diagnostic set WIDE. Because the facility to code results as B3 or B4 was not possible in the old BT record, some early suspicious core biopsy results may be miscoded as malignant (B5). This can be investigated as a possible cause if a high false positive rate is noted, but many units were not entering core biopsy results onto the system at that time. These converted records will also lack some data items such as operator, number of cores, etc.

Archived on 2008/12/01

## **APPENDIX 2: IMMUNOHISTOCHEMICAL DETECTION OF STEROID RECEPTORS IN BREAST CANCER**

A WORKING PROTOCOL PRODUCED BY THE UK RECEPTOR GROUP, UK NEQAS, THE SCOTTISH BREAST CANCER PATHOLOGY GROUP AND THE RECEPTOR AND BIOMARKER STUDY GROUP OF THE EORTC

The protocol described in this paper reflects an overall method that is currently working well in a number of British and mainland European laboratories. Using this methodology, these laboratories find that results (obtained with the attached scoring system) are highly reproducible. Such a scoring system has also been shown to correlate well with the old biochemical assays and to give at least as significant predictive and prognostic information.<sup>56</sup>

To keep loss of antigenicity to a minimum, excised tissue should be incised (sliced) and placed into an adequate volume of fixative (preferably formol saline or neutral buffered formalin) for about 24 h (the slicing allows the necessary rapid and even penetration of fixative – time of fixation can vary according to the size of tissue slices but should be judged on achievement of good morphological appearance). Wherever possible, adjacent sections of normal parenchyma should be taken to act as internal positive control. Localisation biopsies should be handled according to the published guidelines (eg NHSBSP Publication No 3<sup>5</sup>). Core biopsies may be fixed for a period shorter than 24 h.

Sections should be heated onto slides that are either commercially precoated or hand coated with a strong adhesive such as APES – to avoid sections becoming detached from the slide during antigen retrieval. Antigen retrieval is most reliably achieved with 1–2 min in a pressure cooker using 0.01 mol/l citrate buffer pH 6.0 (though properly controlled microwaving is acceptable and detailed methodology for antigen retrieval, buffer selection etc is available from UK NEQAS-ICC – address below). The anti-receptor antibodies selected should be those that have been validated and have a good record in published work, eg clone 1D5 (available from Dako and others) or clone 6F11 from Novocastra for oestrogen receptor, and clones 1A6 (Novocastra) or PR88 (Biogenix) for progesterone receptor (PR). The use of surfactants in buffers prior to the application of the anti-receptor antibody can reduce the detection of the receptor significantly (shown, for example, for 1D5) and should, therefore, be avoided.

In-house controls should come from a composite block containing receptor rich, receptor poor and receptor negative components. If, as recommended, normal breast epithelial cells in adjacent tissue have been taken, these will provide a good internal, positive control.

Staining of sections by hand can be more reliable for low, positive receptor expression. Where automatic stainers are used, it is essential to check the equivalence of the sensitivity with that produced by manual methods. Experienced users of automatic stainers get good results even for low positive receptor expression, so long as surfactants are avoided. A sensitive method of detection, such as ABC (for example, the Dako Duet K0492 gives consistently good results but others will work equally well), should be used. Counterstaining should not obscure weak, positive staining, but if this is avoided can be valuable. Excessive counterstaining does occur in some automatic stainers though adjustment should be possible. True receptor staining is taken to be nuclear and cytoplasmic staining should be ignored.

All laboratories must take part in an external quality assurance scheme: an appropriate one is run by UK NEQAS (address below).

In reporting the results of steroid receptor immunohistochemistry, simple scoring systems are found to work the best (see reference 57). These use either a direct count of the proportion of epithelial nuclei that take up stain or a simple combination of the percentage cells staining plus a measure of intensity of stain, eg the Quick Score.

The following scoring system is a simple, additive system giving a range from 0 to 8 and has proven to be highly reproducible among readers:

<i>Score for proportion staining</i>	<i>Score for staining intensity</i>
0 = no nuclear staining	0 = no staining
1 = <1% nuclei staining	1 = weak staining
2 = 1–10% nuclei staining	2 = moderate staining
3 = 10–33% nuclei staining	3 = strong staining
4 = 33–66% nuclei staining	
5 = 66–100% nuclei staining	

Adding the two scores together gives a maximum score of 8.

Experience to date suggests that (see also reference 56), using such a simple scoring system, appropriate cut-off values for treatment of advanced disease are as follows:

- a score of zero indicates that endocrine therapies will definitely **not** work
- a score of 2–3 indicates a small (20%) chance of response to endocrine therapies
- a score of 4–6 indicates an even (50%) chance of response
- a score of 7–8 indicates a good (75%) chance of response.



Where progesterone receptor content has also been determined, endocrine therapy is deemed worthwhile in patients with low ER but high progesterone receptor (PR).<sup>58</sup>

In elderly patients, some tumour shrinkage may be seen after endocrine therapy, even though the ER staining is low.<sup>58</sup>

Perhaps the single most valuable observation is that for patients with a breast cancer that is zero on the Quick Score the chances of response to endocrine therapy are essentially nil and these patients should receive an alternative therapy as first-line therapy.

The appropriate cut-off values for adjuvant therapy using steroid receptor determination by immunohistochemistry have yet to be determined, though Harvey et al<sup>56</sup> reported that, using a similar scoring system but slightly different protocol, a value >2 was the optimal cut-off point for predicting improved outcome ( $P < 0.0001$ ).

### Authors

Written on behalf of the associated groups by Robin Leake (Biochemistry, Glasgow), Diana Barnes (Pathology, Guy's Hospital, London), Sarah Pinder and Ian Ellis (Pathology, Nottingham), Liz Anderson (Clinical Research, Christie Hospital, Manchester), Tom Anderson (Pathology, Edinburgh), Ruth Adamson (Pathology, Kilmarnock), Tony Rhodes and Keith Miller (UK NEQAS) and Rosemary Walker (Pathology, Leicester).

Technical advice can be obtained from

UK NEQAS for Immunohistochemistry  
Department of Histopathology  
UCL Medical School  
University Street  
London WC1E 6JJ

Phone +44 (0) 20 7209 6049 Fax +44 (0) 20 7387 3674

Reproduced with permission from *Journal of Clinical Pathology* 2000, 53: 634–635.

## REFERENCES

1. Royal College of Pathologists Working Group for Breast Screening Pathology. *Guidelines for Pathologists*. Sheffield, NHS Breast Screening Programme, 1989 (NHSBSP Publication No 2).
2. Royal College of Pathologists Working Group. Pathology reporting in breast cancer screening. *Journal of Clinical Pathology* 1989, 44: 710–725.
3. Cytology Sub-group of the National Coordinating Committee for Breast Cancer Screening Pathology. *Guidelines for Cytology Procedures and Reporting in Breast Cancer Screening*. Sheffield, NHS Breast Screening Programme and Royal College of Pathologists, 1993 (NHSBSP Publication No 22).
4. European Commission. *European Guidelines for Quality Assurance in Mammography Screening*, 2nd edn. Luxembourg, Office for Official Publications of the European Communities, 1996.
5. Royal College of Pathologists Working Group for Breast Screening Pathology. *Pathology Reporting in Breast Cancer Screening* (2nd edition). Sheffield, NHS Breast Screening Programme, 1997 (NHSBSP Publications No 3).
6. National Coordinating Group for Breast Screening Pathology. *Guidelines for Breast Pathology Services*. Sheffield, NHS Breast Screening Programme, 1997 (NHSBSP Publication No 2).
7. Lamb J, Anderson TJ, Dixon MJ, Levack P. Role of fine needle aspiration cytology in breast cancer screening. *Journal of Clinical Pathology* 1987, 40: 705–709.
8. Zajdela A, Chossein NA, Pillerton JP. The value of aspiration cytology in the diagnosis of breast cancer. *Cancer* 1975, 35: 499–506.
9. Azavedo E, Svane G, Auer G. Stereotactic fine needle biopsy in 2594 mammographically detected non-palpable lesions. *Lancet* 1989, 1: 1033–1035.
10. Wilson ARM, Asbury D, Cooke J et al (eds). *Clinical Guidelines for Breast Cancer Screening Assessment*. Sheffield, NHS Cancer Screening Programmes, 2001 (NHSBSP Publication No 49).
11. Britton P. Fine needle aspiration or core biopsy. *The Breast* 1999, 8: 1–4.
12. Philpotts LE, Shaheeh NA, Carter D et al. Comparison of rebiopsy rates after stereotactic core needle biopsy of the breast with 11-gauge vacuum suction probe versus 14-gauge needle and automatic gun. *American Journal of Roentgenology* 1999, 172: 683–687.
13. Warren R. Team learning and breast cancer screening. *Lancet* 1991, 338: 514.
14. Kaminsky DB. Aspiration biopsy in the context of the new Medicare fiscal policy. *Acta Cytologica* 1984, 28: 333–337.
15. Kocjan G. Evaluation of the cost effectiveness of establishing a fine needle aspiration cytology clinic in a hospital out-patient department. *Cytopathology* 1991, 2: 13–18.
16. McKee G, Thomas B, Cooke J. Stereotactic cytology – results of the first 250 cases. In: *3rd Annual BSCC Meeting, Sheffield. 1991*. BSCC.
17. Burkhardt JH, Sunshine JH. Core-needle and surgical breast biopsy: Comparison of three methods of assessing cost. *Radiology* 1999, 212: 181–188.
18. Liberman L, Feng TL, Dershall DD. US-guided core breast biopsy: use and cost-effectiveness. *Radiology* 1998, 208: 717–723.
19. Zakhour H, Wells C. *Diagnostic Cytopathology of the Breast*. London, Churchill Livingstone, 1999.
20. Zajdela A, Zillhardt P, Voillemot N. Cytological diagnosis by fine needle sampling without aspiration. *Cancer* 1987, 59: 1201–1205.
21. Catania S, Boccato P, Bono A et al. Pneumothorax: a rare complication of fine needle aspiration of the breast. *Acta Cytologica* 1989, 33: 140.

22. Liberman L, Smolkin JH, Dershaw DD et al. Calcification retrieval at stereotactic, 11-gauge, directional, vacuum-assisted breast biopsy. *Radiology* 1998, 208: 251–260.
23. Liberman L, Vuolo M, Dershaw DD et al. Epithelial displacement after stereotactic 11-gauge directional vacuum-assisted breast biopsy. *American Journal of Roentgenology* 1999, 172: 677–681.
24. Preece PE, Hunter SM, Duguid HLD, Wood RAB. Cytodiagnosis and other methods of biopsy in the modern management of breast cancer. *Seminars in Surgical Oncology* 1989, 5: 69–81.
25. Peterse JL, Koolman-Schellekens MA, van-de-Poppel-van-de-Ham T, van-Heerde P. Atypia in fine-needle aspiration cytology of the breast: a histological follow-up study of 301 cases. *Seminars in Diagnostic Pathology* 1989, 6: 126–134.
26. Simpson JF, Page DL, Dupont WD. Apocrine adenosis – a mimic of mammary carcinoma. *Surgical Pathology* 1990, 3: 289–299.
27. Salhany KE, Page DL. Fine needle aspiration of mammary lobular carcinoma in situ and atypical lobular hyperplasia. *American Journal of Clinical Pathology* 1989, 92: 22–26.
28. Bibbo M, Scheiber M, Cajulis R et al. Stereotaxic fine needle aspiration cytology of clinically occult malignant and premalignant breast lesions. *Acta Cytologica* 1988, 32: 193–201.
29. Abendroth CS, Wang HH, Ducatman BS. Comparative features of carcinoma in situ and atypical ductal hyperplasia of the breast on fine-needle aspiration biopsy specimens. *American Journal of Clinical Pathology* 1991, 96: 654–659.
30. Sneige N, Staerkel GA. Fine needle aspiration cytology of ductal hyperplasia with and without atypia and ductal carcinoma in situ. *Human Pathology* 1994, 25: 485–492.
31. Oertel YC, Galblum LI. Fine needle aspiration of the breast: diagnostic criteria. *Pathology Annual* 1983, 18 Pt 1.
32. Wells CA, Wells CW, Yeomans P et al. Spherical connective tissue inclusions in epithelial hyperplasia of the breast ('collagenous spherulosis'). *Journal of Clinical Pathology* 1990, 43: 905–908.
33. Tyler X, Coghill SB. Fine needle aspiration cytology of collagenous spherulosis of the breast. *Cytopathology* 1991, 2: 159–162.
34. Evans AT, Hussein KAH. A microglandular adenosis like lesion simulating tubular adenocarcinoma. *Cytopathology* 1990, 1: 311–316.
35. Lamb J, Anderson TJ. Influence of cancer histology on the success of fine needle aspiration of the breast. *Journal of Clinical Pathology* 1989, 42: 733–735.
36. Bondesan L, Lindholm K. Aspiration cytology of tubular breast carcinoma. *Acta Cytologica* 1990, 34: 15–20.
37. Sneige N, Zachariah S, Fanning TV et al. Fine needle aspiration cytology of metastatic neoplasms in the breast. *American Journal of Clinical Pathology* 1989, 92: 27–35.
38. Redard M, Vassilakos P, Weintraub J. A simple method for oestrogen receptor antigen preservation in cytologic specimens containing breast carcinoma cells. *Cytopathology* 1989, 5: 188–193.
39. Hunt CM, Ellis IO, Elston CW et al. Cytological grading of breast carcinoma – a feasible proposition? *Cytopathology* 1990, 1: 287–295.
40. Thomas JSJ, Mallon EA, George WD. Semi-quantitative analyses of fine needle aspirates from benign and malignant breast lesions. *Journal of Clinical Pathology* 1989, 42: 28–34.
41. Robinson IA, McKee G, Nicholson A et al. Prognostic value of cytological grading of fine-needle aspirates from breast carcinomas. *Lancet* 1994, 343: 947–949.
42. Mapstone NP, Zakhour HD. Morphometric analysis of fine needle aspirates from breast lesions. *Cytopathology* 1990, 1: 349–355.

43. Dahlstrom JE, Sutton S, Jain S. Histologic–radiologic correlation of mammographically detected microcalcification in stereotactic core biopsies. *American Journal of Surgical Pathology* 1998, 22: 256–259.
44. Liberman L, Cohen MA, Dershaw DD et al. Atypical ductal hyperplasia diagnosed at stereotaxic core biopsy of breast lesions: an indication for surgical biopsy. *American Journal of Roentgenology* 1995, 164: 1111–1113.
45. Liberman L, Dershaw DD, Rosen PP et al. Stereotaxic core biopsy of breast carcinoma: accuracy at predicting invasion. *Radiology* 1995, 194: 379–381.
46. Zidan A, Brown JSC, Peston D, Shousha S. Oestrogen and progesterone receptor assessment in core biopsy specimens of breast carcinoma. *Journal of Clinical Pathology* 1997, 50: 27–29.
47. Goulding H, Pinder S, Cannon P et al. A new immunohistochemical antibody for the assessment of estrogen receptor status on routine formalin-fixed tissue samples. *Human Pathology* 1995, 26: 291–294.
48. Barrows GH, Anderson TJ, Lamb JL, Dixon JM. Fine needle aspiration of breast cancer – relationship of clinical factors to cytology results in 689 primary malignancies. *Cancer* 1986, 58: 1493–1498.
49. Wells CA. Quality assurance in breast cancer screening cytology: A review of the literature and a report on the UK National Cytology Scheme. *European Journal of Cancer* 1995, 31A: 273–280.
50. Wells CA, Perera R, White FE, Domizio P. Fine needle aspiration cytology in the UK Breast Screening Programme – a national audit of results. *The Breast* 1999, 8: 261–266.
51. Britton PD, McCann J. Needle biopsy in the NHS Breast Screening Programme 1996/1997: How much and how accurate? *The Breast* 1999, 8: 5–11.
52. Crotch-Harvey MA, Loughran CV. Combined stereotactic wide core needle biopsy and fine needle aspiration cytology in the assessment of impalpable mammographic abnormalities detected in a breast screening programme. *The Breast* 1996, 5: 48–49.
53. Meyer JE. Value of large core biopsy of occult breast lesions. *American Journal of Roentgenology* 1992, 158: 991–992.
54. Yeoman LJ, Michel MJ, Humphreys S et al. Radiographically guided fine needle aspiration cytology and core biopsy in the assessment of impalpable breast lesions. *The Breast* 1996, 5: 41–47.
55. Sadler GP, McGee S, Dallimore NS et al. Role of fine needle aspiration cytology and needle core biopsy in the diagnosis of lobular carcinoma of the breast. *British Journal of Surgery* 1994, 81: 1315–1317.
56. Harvey JM, Clark GM, Osborne CK, Allred DC. Oestrogen receptor status by immunohistochemistry is superior to the ligand-binding assays for predicting response to adjuvant therapy in breast cancer. *Journal of Clinical Oncology* 1999, 17: 1474–1485.
57. Barnes DM, Millis RR, Beex L et al. Increased use of immunohistochemistry for oestrogen receptor measurement in mammary carcinoma: the need for quality assurance. *European Journal of Cancer* 1998, 34: 1677–1682.
58. EBCTCG. Tamoxifen for early breast cancer: an overview of randomised trials. *Lancet* 1998, 351: 1451–1467.

Archived on 22/03/2017