



Public Health
England



NHS Breast Screening Programme

Screening women with breast implants

July 2017

Public Health England leads the NHS Screening Programmes

About Public Health England

Public Health England exists to protect and improve the nation's health and wellbeing, and reduce health inequalities. It does this through world-class science, knowledge and intelligence, advocacy, partnerships and the delivery of specialist public health services. PHE is an operationally autonomous executive agency of the Department of Health.

Public Health England, Wellington House, 133-155 Waterloo Road, London SE1 8UG

Tel: 020 7654 8000 www.gov.uk/phe

Twitter: [@PHE_uk](https://twitter.com/PHE_uk) Facebook: www.facebook.com/PublicHealthEngland

About PHE Screening

Screening identifies apparently healthy people who may be at increased risk of a disease or condition, enabling earlier treatment or better informed decisions. National population screening programmes are implemented in the NHS on the advice of the UK National Screening Committee (UK NSC), which makes independent, evidence-based recommendations to ministers in the four UK countries. The Screening Quality Assurance Service ensures programmes are safe and effective by checking that national standards are met. PHE leads the NHS Screening Programmes and hosts the UK NSC secretariat.

PHE Screening, Floor 2, Zone B, Skipton House, 80 London Road, London SE1 6LH

www.gov.uk/topic/population-screening-programmes

Twitter: [@PHE_Screening](https://twitter.com/PHE_Screening) Blog: phescreening.blog.gov.uk

Prepared by C Borrelli, Z Vegnuti

For queries relating to this document, please contact: phe.screeninghelpdesk@nhs.net

© Crown copyright 2017

You may re-use this information (excluding logos) free of charge in any format or medium, under the terms of the Open Government Licence v3.0. To view this licence, visit [OGL](https://www.ogil.io) or email psi@nationalarchives.gsi.gov.uk. Where we have identified any third party copyright information you will need to obtain permission from the copyright holders concerned.

Published July 2017

PHE publications gateway number: 2017011



Contents

About Public Health England	2
About PHE Screening	2
Executive summary	4
Screening and implants	4
Imaging process overview	5
Communicating with the woman	6
Visual observation of the breasts	7
If a ruptured implant is suspected	8
High risk screening	9
Imaging types of implants	9
Subglandular implant	9
Subpectoral implant	11
Undertaking the Eklund view	12
Displaying the images	14
Improving cancer detection	14
Injectable enhancements	16
Radiation dose	16
Breast awareness	17
Subcutaneous mastectomy	17
Realistic client expectations	18
Training and education	18
Appendix 1: BCSS 'special appointment'	19
Appendix 2: BCSS notes	20
Appendix 3: protocol for mammographic imaging of women with breast implants	21
Appendix 4: consent form	25
Appendix 5: draft proforma letter	26
References	27

Executive summary

This guidance specifies that the Eklund technique should be offered to all women with breast implants, where appropriate. This is supported by a national imaging auditⁱ and is stated in the **national service specification** for breast screening.

Breast augmentation is a common surgical procedure and women may undergo breast augmentation with implants for a variety of reasons ranging from purely aesthetic choice to reconstructive surgery following mastectomy. It is important to remember that women with breast implants are prone to the same range of diseases as those without implants and the management of those problems is similar. The main differences are that the physical presence of the implant can make mammography more difficult.

Whilst mammography remains the gold standard for breast cancer imaging, the presence of breast implants in women represents an important imaging challenge. Breast implants may interfere with the accurate imaging of breast tissue and could also expose patients to risk factors such as implant rupture during the mammography procedure (although there is no reliable current evidence to support this). Mammography performed by an experienced radiographer reduces the likelihood of rupture and other complications during the mammogram procedure. In addition, specialized techniques are available to achieve successful breast imaging in women with implants^{ii,iii,iv}

Screening and implants

The NHS Breast Screening Programme (NHSBSP) is a cancer detection service and does not provide an implant checking service. Women with specific concerns about implant integrity (suspected rupture) or the feel or appearance of their implants should consult their GP. Screening should not take place. Any discussion at screening between a radiographer and a woman who has concerns about her implants should be recorded by the radiographer at that time. Screening women with implants is not a routine imaging procedure and requires the knowledge and expertise of a registered radiographer.

These guidelines should form the basis of a local protocol for each breast screening service. Their aim is to standardise procedures in the NHSBSP.

Mammography is the most accurate method of early detection of breast cancer although some of the breast tissue in clients who have had augmentation is obscured by the radiopaque implant during routine mammography. Detection of breast cancer at an early stage is therefore more difficult due to the impaired view of the breast tissue^v.

The Eklund technique is mandatory for all women with implants who attend for breast screening and proceed with routine mammography with the option to further consent to the additional procedure. The Eklund technique is an internationally recognised method to optimise cancer detection in women with breast implants. It is used in services within Australia, the USA and other countries to promote high quality breast screening.

All radiographers undertaking this technique should have evidence that they have been educated and trained in the Eklund technique. This education is obtained via the training DVD which is available at all breast screening services, and also from colleagues who may have practical experience in the technique. In line with IRMER 2000 and clinical governance, internal training records must be kept for those undertaking this technique. The superintendent radiographer or radiographic service manager should maintain these records.

It is possible to screen women with implants on mobile units as the images can be seen instantly when using digital equipment. Additional appointment time may need to be allocated. This would be a local decision.

Imaging process overview

Imaging women with breast implants should only be undertaken by a registered radiographer.

Before proceeding, the radiographer should do the following.

1. Take the relevant breast history and, if possible, ascertain the type of implant.
2. The radiographer or member of the administration team should record the history (and type of implant) on the breast screening computer system as per the local protocol (see Appendices 1 and 2).
3. Record the site of the implant if known, for example subglandular or submuscular.

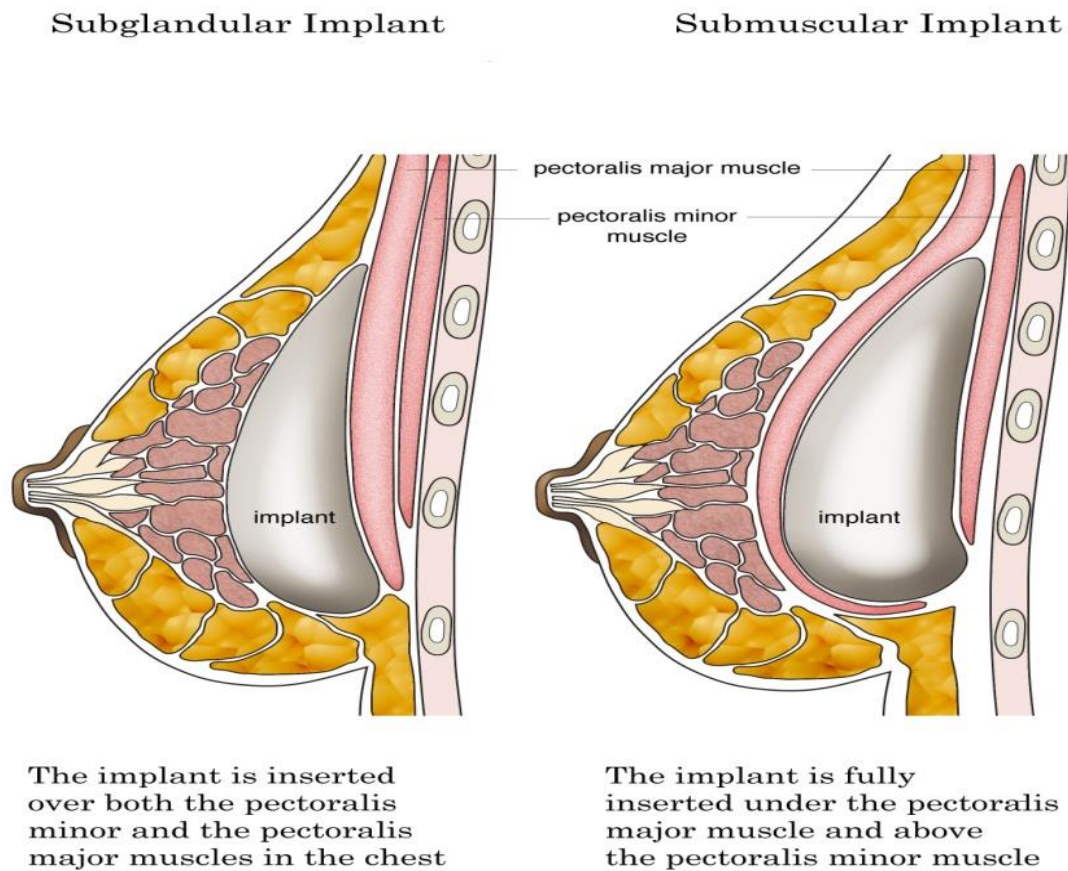


Figure 1: Subglandular and submuscular implants (*Images sourced from C Borrelli*)

Communicating with the woman

The following should be considered when communicating with a woman with implants:

Women who have attended previously may have a record flag as 'needing a special appointment'. Using this flag is a local decision, but may help units to allocate suitable appointment times and provide information.

Provide the woman with a copy of the NHSBSP leaflet on breast screening and breast implants (<https://www.gov.uk/government/publications/breast-screening-breast-implant-guidelines>)

Explain the significantly reduced sensitivity of screening due to the presence of an implant. Guidance from the Medicines and Healthcare Regulatory Agency (MHRA) regarding

breast implants is that women should be advised that the presence of an implant may interfere with standard mammography used to detect breast cancer^{vi}. The NHSBSP implant leaflet also explains this.

Full compression should not be used. Explain the use of minimal compression. Minimal compression is required to keep the woman still during mammography because the breast tissue is already under compression from the inserted implant. Explain that there is no evidence that compression has ever ruptured an implant and that this is unlikely, but that care will be taken throughout the examination.

Explain the need for additional images to be able to visualise as much breast tissue as possible so that as much detailed information as possible is available.

Advise the woman that she may stop the examination at any time if she wishes.

It is essential that all radiographers document that an explanation of the technique and its limitations has taken place prior to undertaking the examination. The protocol for use of the Eklund technique is shown in Appendix 3. A client consent form is considered good practice and should be completed by the radiographer and client prior to the examination being undertaken (see Appendix 4).

Visual observation of the breasts

The radiographer should observe the breasts and record before and after the mammographic examination to note any change. This is an observational check and no specific training is required. If change is noted, seek guidance from a radiologist and follow local protocols.

Unusual breast changes that may indicate damage to the implant may include:

- differences in the size and shape of the breasts
- position of the nipple
- contour of the breast

As with all women attending for mammography, any differences observed should be pointed out to the woman with sensitivity and care prior to mammography being undertaken.

Suspected rupture or known, stable rupture of an implant

Following insertion of a breast implant, a capsule forms around it. Most implant ruptures or leaks will be identified as **intra-capsular** (within the capsule). Women may be unaware of this and they may remain asymptomatic. This is unlikely to be identified at screening as there is no evidence of intra-capsular rupture identified on mammography, the woman **can** still be screened at this and future screening appointments.

Gross extra-capsular spread of silicone is another type of rupture. It is seen more rarely and would usually appear symptomatically, (including sometimes to enlarged axillary lymph nodes). This would usually merit further assessment and advice if the woman chooses to contact her GP. If this is the case, she should be advised to consult her GP.

Information for radiographic practitioners

1. Suspected rupture – don't screen

When a woman identifies symptoms of breast change and suspects that implant leakage may be the underlying cause.

The radiographer should:

- explain that we will not continue with a mammogram until they have confirmation from the woman's GP or surgeon that it is safe to continue with screening mammography
- record this information on the electronic national database via notepad (Appendix 2 in guidance document)
- Following discussion with the client, give a letter to the woman to confirm that the examination will not be undertaken and that she should seek further guidance from her GP (see Appendix 5).

This approach helps protect the radiographer from potential claims that the mammogram caused the rupture.

The NHSBSP is not suggesting that all women with suspected implant leakage should be referred for surgery. We will screen all women with implants, if they consent, unless they are concerned that they have an unconfirmed rupture.

2. Known stable or longstanding rupture – screen

When a woman has a known implant rupture (from the woman having informed the radiographer).

Mammographic screening may be offered and the woman can consent. Positioning for the Eklund view may be more challenging under these circumstances and may not be achievable on the breast with the ruptured implant. Routine mammography should therefore be undertaken on that individual breast and the radiographer document this via the electronic national data base via notepad (Appendix 2 in guidance document).

3. Rupture identified during the mammographic examination

When a woman does not identify a known rupture prior to the examination but rupture is identified during imaging, the radiographer should:

- complete the examination
- not be expected to share this information with the woman

The screening service does not report on implant integrity. If the woman has any queries about implant integrity she should seek advice from her GP. The GP may recommend investigation via the symptomatic service or her previous surgeon.

High risk screening

All women that are routinely invited via high risk screening who present with breast augmentation should be offered both a routine mammogram and the Eklund technique at each attendance.

Imaging types of implants

Subglandular implant

A subglandular implant is positioned posterior to the breast parenchyma and superficial to the pectoral muscle. This presentation is the most challenging for the radiographer to position to demonstrate maximum breast tissue.

The subglandular position in patients with thin soft-tissue coverage is more likely to show ripples or wrinkles of the underlying implant. The implant edges may be more visibly noticeable under the skin but are helpful to feel when encouraging the breast tissue away from the implant when undertaking the Eklund view. For women who present with subglandular implants that are many years old, there is the potential for the implant to migrate or displace. If women raise concerns regarding implant migration, they should be advised to discuss this with their GP.

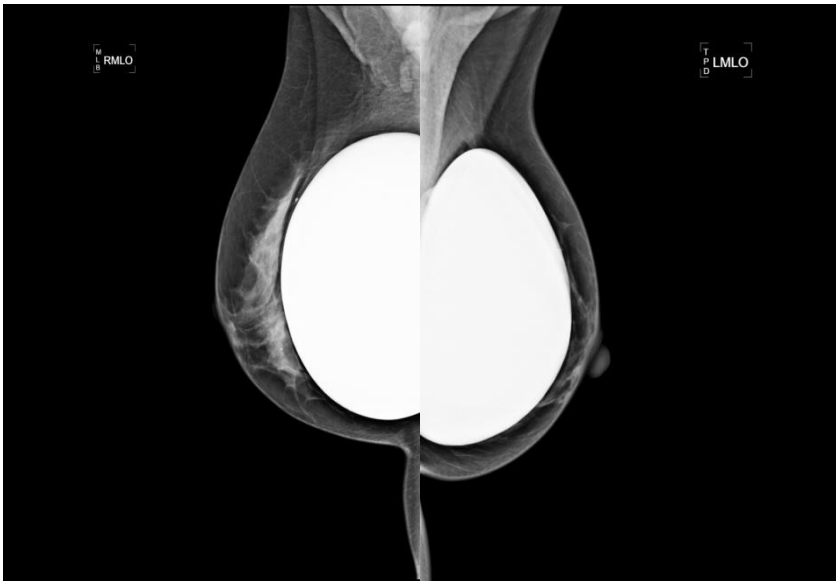

Figure 2: Subglandular implant - medio-lateral oblique (mlo) view

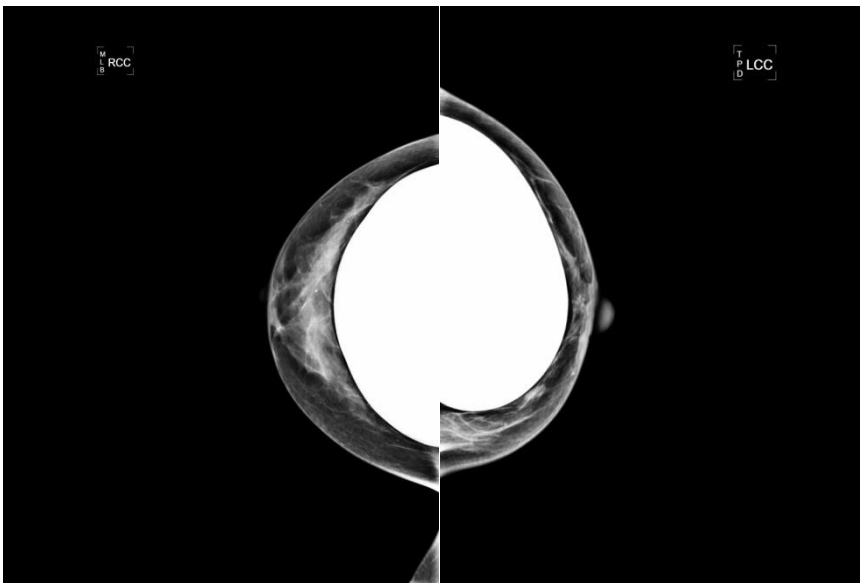


Figure 3: Subglandular implant – routine cradio-caudal (cc) view

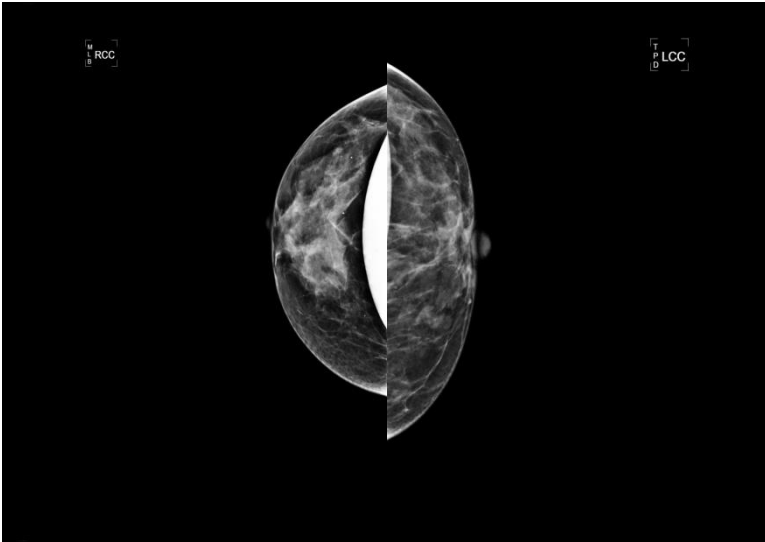

Figure 4: Subglandular implant – Eklund technique

Subpectoral implant

A subpectoral implant is placed under the pectoralis major muscle and over the pectoralis minor muscle (pocket placement). This may often be less challenging for the radiographer to position and obtain high quality imaging with good visualisation of breast tissue, as the implant may push the breast tissue forward and enhance breast tissue visualisation. Subpectoral placement may reduce the chances of breast implants being felt through the skin, and it may help reduce the chance of scar tissue hardening around breast implants.

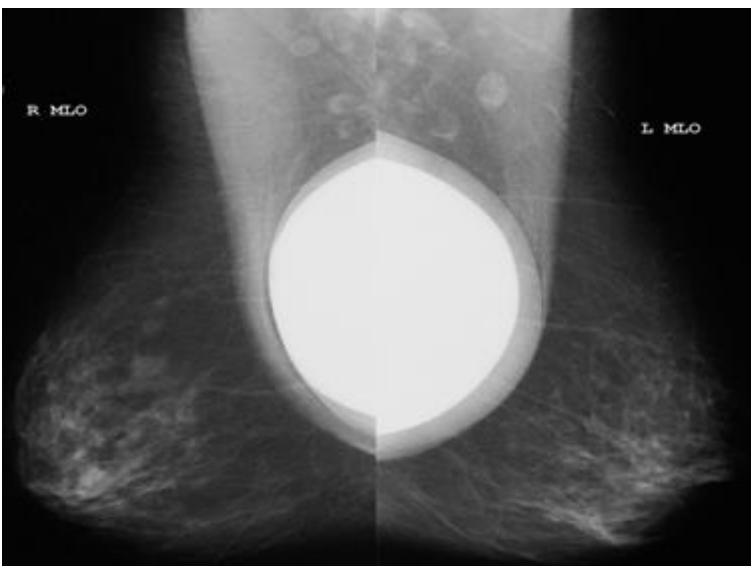


Figure 5: Subpectoral implant (mlo view)

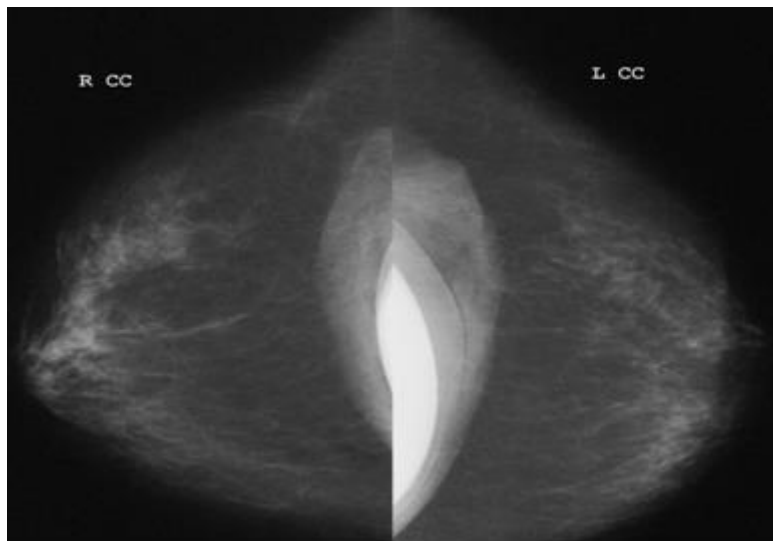


Figure 6: Subpectoral implant (cc view)

Undertaking the Eklund view

All women attending for breast screening that present with breast augmentation must be offered the Eklund technique. The recommended views include the following.

- Standard mediolateral-oblique (MLO) views first to establish the position of the implant (subpectoral or subglandular). This will help with decisions about imaging of that client
- If the implant is subglandular, perform standard cranial-caudal (CC) views to get as far back onto the chest wall as possible
- Perform Eklund CC views to demonstrate the anterior breast tissue with the implant displaced posteriorly
- If the implant is subpectoral, it is still considered beneficial to perform both standard CC views and Eklund CC views, the only difference being the implant edge is less likely to be felt during positioning.
- If the implant is immobile (encapsulated), a true lateral view may be considered a helpful alternative. There is no evidence to support this as an alternative however and it remains a local decision. Clear guidance should be given by the clinical lead and protocols should be in place prior to undertaking this. It is not acceptable that this view is undertaken instead of the Eklund CC view just as an easier positioning option for the radiographer.

- In addition to routine views, the Eklund technique may be used to pull the breast tissue forward and away from the implant to improve breast tissue visualisation. However, if the implant feels firmly fixed in position, this technique may not be suitable. Even under ideal circumstances, such as a 'soft' breast and an experienced radiographer, some breast tissue may still be obscured by the implant^{vii}.

Teams have a responsibility to monitor and audit a proportion of these women with implants to determine the effectiveness of this technique. Local and national audits will be performed over the next three years. Future practice can then be amended appropriately with consideration of the evidence when reviewing any impact on cancer detection rates.

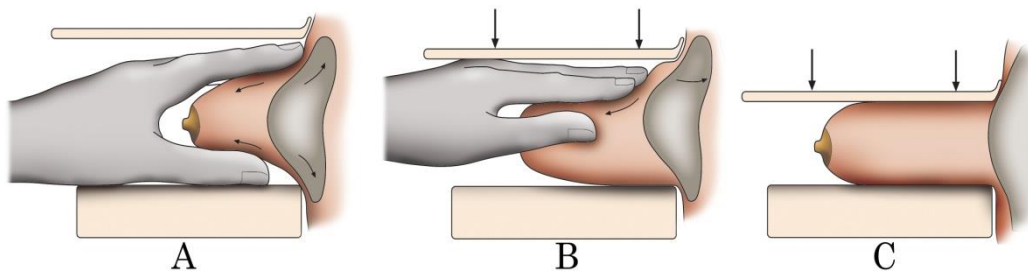


Figure 7: Illustration of the Eklund View (*Images sourced from C Borrelli*)

A Tissue is pulled over and away from implant (leaning the woman forward may help in some cases)

B As implant is displaced backwards, more compression is possible.

C With the implant excluded, optimum compression of breast tissue is possible and therefore more breast tissue is visualised in greater detail to aid image interpretation.

Despite the best efforts made to maximise the amount of breast tissue visualised free of the implant, there will be some compromise in visualisation of all breast tissue in most patients who have breast implants.

The radiographer should record all details of the examination. Views taken, exposure, breast thickness and compression force should all be available in the Digital Imaging and Communications in Medicine (DICOM) header.

As with all women, it is important to emphasise breast awareness and advise them that they should contact their GP immediately if they have any concerns:

- following mammography
- about new symptoms
- regarding implant integrity

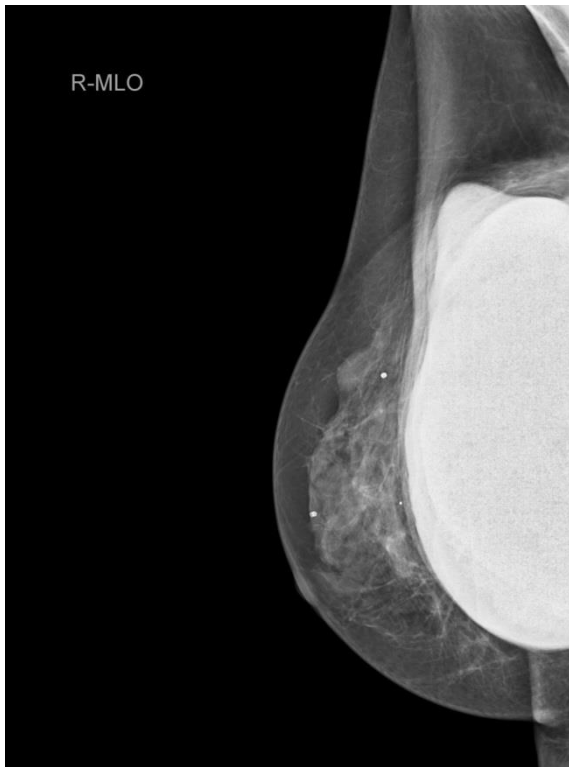Displaying the images

Guidance on displaying images is currently work in progress. Each breast screening unit may choose to 'hang' their images in a different way and there are various breast specific picture archiving and communication systems (PACS) in use. The addition of extra images in a study can change the way the images display in PACS. Bespoke display protocols can be created for most series of images that are undertaken. One of the most important aspects of 'hanging' is to display previous images, like for like, for comparison with the current series.

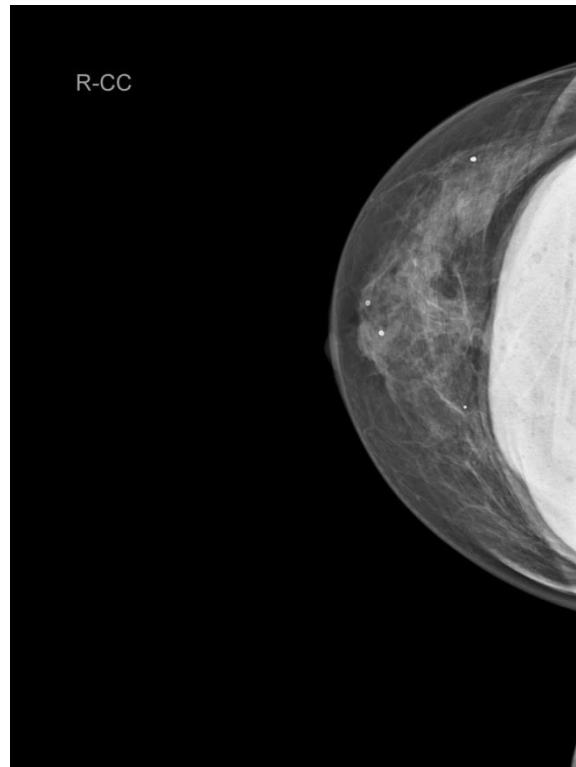
The creation of these display protocols within PACS has allowed for nearly all imaging to fall into the correct order for reporting, and this then facilitates the smooth reporting of images. New protocols created in PACS can 'hang' these images but may not display like for like. For Eklund and CC images, these series will need to be checked and manually hung if necessary. The 'knock on' effect is an increase in workload and a change in workflow, with training implications for all staff involved. Discussions with the PACS provider is an essential consideration for teams prior to writing an internal protocol to document the guidance agreed upon locally.

Improving cancer detection

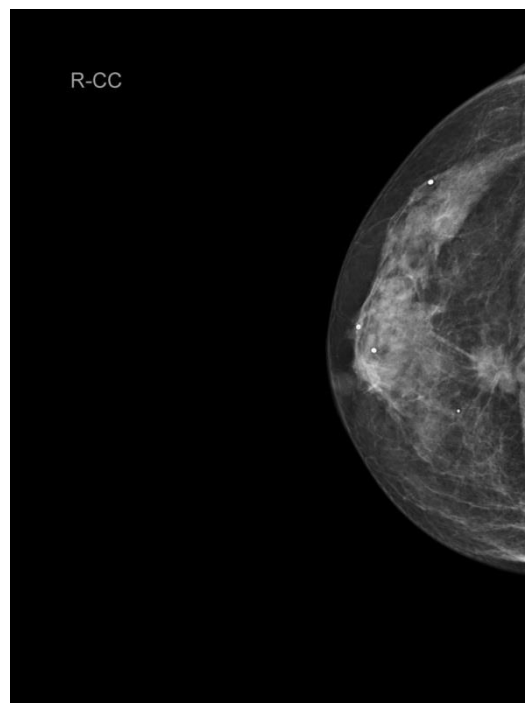
For women presenting to the breast screening service with breast implants, the Eklund technique must be used (for all women consenting to the additional views) to pull the breast tissue forward away from the implant and improve breast tissue visualisation. This may lead to improved cancer detection rates for this cohort of women^{viii}. All units are encouraged to audit this to inform future practice.



Routine MLO view



Routine CC view



Eklund CC view

Figure 8: Images of a client with breast augmentation where a lesion is clearly demonstrated on the Right CC view only using Eklund technique

Injectable enhancements

Women may opt for injectable fillers for volume restoration and body contouring as an alternative to breast augmentation with implants. Prior to breast imaging, it is important for the radiographer to know in advance if breast fillers or fat transfer have been used. Some products may compromise the visualisation of breast tissue and may therefore significantly reduce the diagnostic quality of the mammograms. The radiographer should record this discussion and identify if fillers have been used. This information is essential for consideration by the film readers when reporting on the images as breast tissue is likely to be obscured.

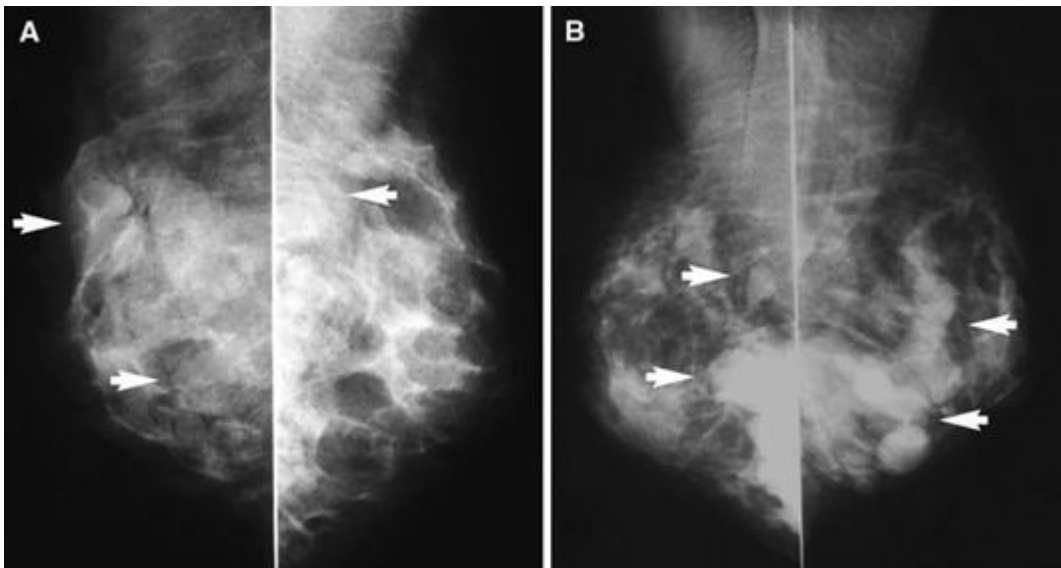


Figure 9: Mammograms in the medio-lateral oblique projection at 12 months from two different patients. The arrows indicate the location of the enhancement filler.

Radiation dose

Major factors affecting radiation dose include:

- the amount of compression applied during imaging
- the thickness and structure of the breast
- the amount of views undertaken for the examination

Breast compression during a screening mammogram reduces the radiation dose significantly since a thinner amount of breast tissue absorbs less radiation. It also separates overlapping folds of breast tissue that may obscure small abnormalities. Minimal

compression is used for women presenting with breast implants to help keep the woman still rather than compression to minimise dose and breast thickness. The Eklund view will enable further compression and therefore improve breast tissue visualisation^{ix}.

Breast implants can block a clear view of the breast tissue making mammograms less effective in breast cancer detection. Therefore, radiation exposure will be greater in women with implants, because more X-rays need to be taken and less compression is used. The benefit of early diagnosis and treatment of breast cancer far outweighs the risk of the small amount of radiation received during a screening mammogram with the addition of Eklund views.

Breast awareness

Breast awareness is about encouraging women to become more aware of their bodies generally and to get to know their own breasts. This is an important issue for all women as learning how their breasts look and feel at different times will help women know what is normal for them and to recognise any irregular changes.

A leaflet, 'Be breast aware' is available (including online large print and translated versions). It recommends the Touch, Look, Check (**TLC**) method:

Touch your breast. Can you feel anything unusual?

Look for changes. Is there any change in shape or texture?

Check anything unusual with your doctor

[‘TLC’ is reproduced with permission from Breast Cancer Now]

Subcutaneous mastectomy

If a woman has had a unilateral subcutaneous mastectomy and an implant, the radiographer should advise that it **not necessary** to perform mammography on that side since it is expected that all breast tissue has been removed. The other breast should be screened as usual.

Realistic client expectations

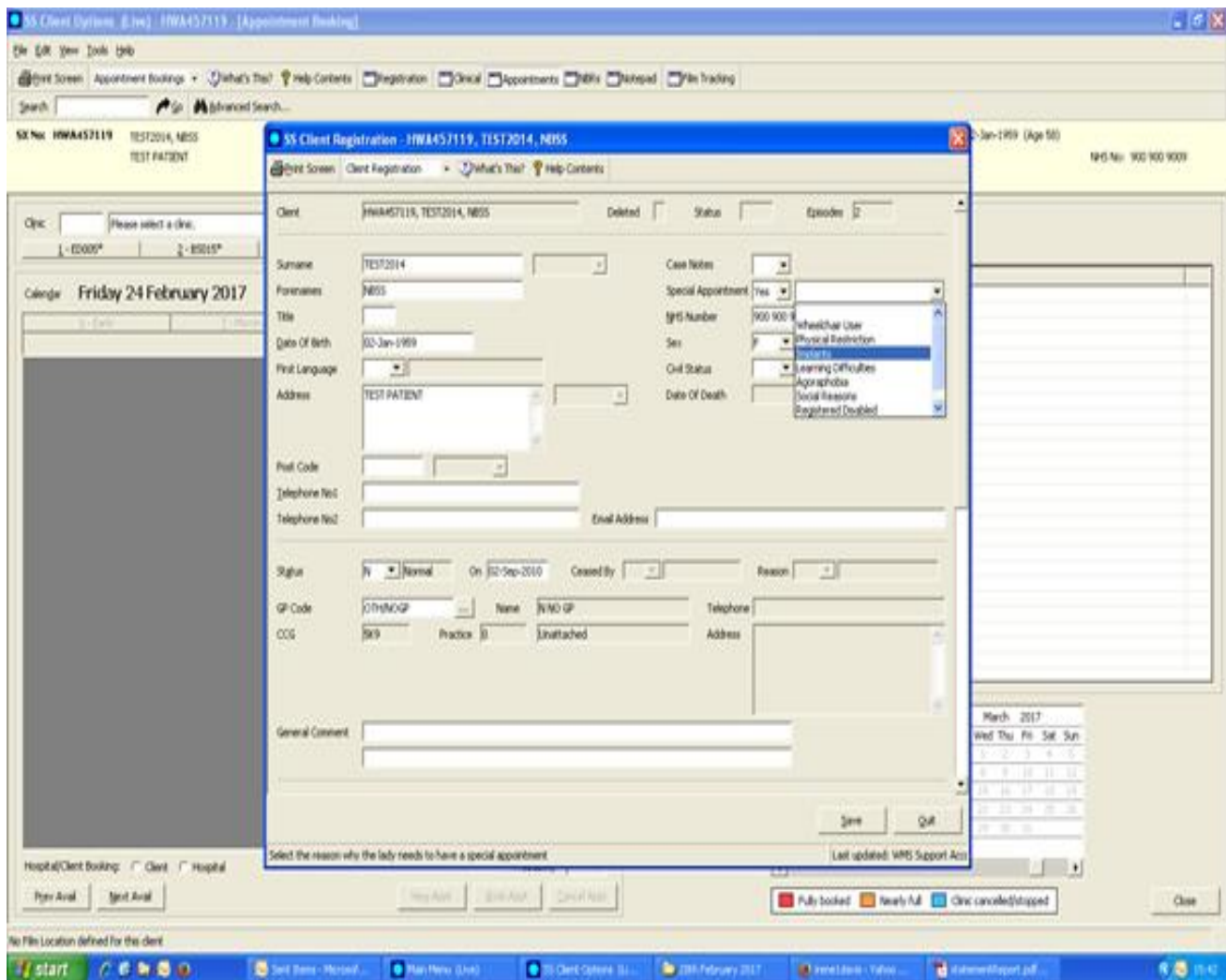
Women with breast augmentation should be aware that the presence of implants will slightly increase the length of their mammography examination and will require additional imaging using the Eklund technique to improve the visualisation of the breast tissue. Women with implants may be concerned about the implant rupturing during the examination and should be reassured that:

- currently there is no evidence of mammography causing implant rupture
- great care will be taken during the examination

Training and education

Radiographers have a professional responsibility to ensure that they seek appropriate education and training to undertake imaging women with implants. A training DVD on implant imaging techniques is available at each breast screening unit within the NHSBSP^x.

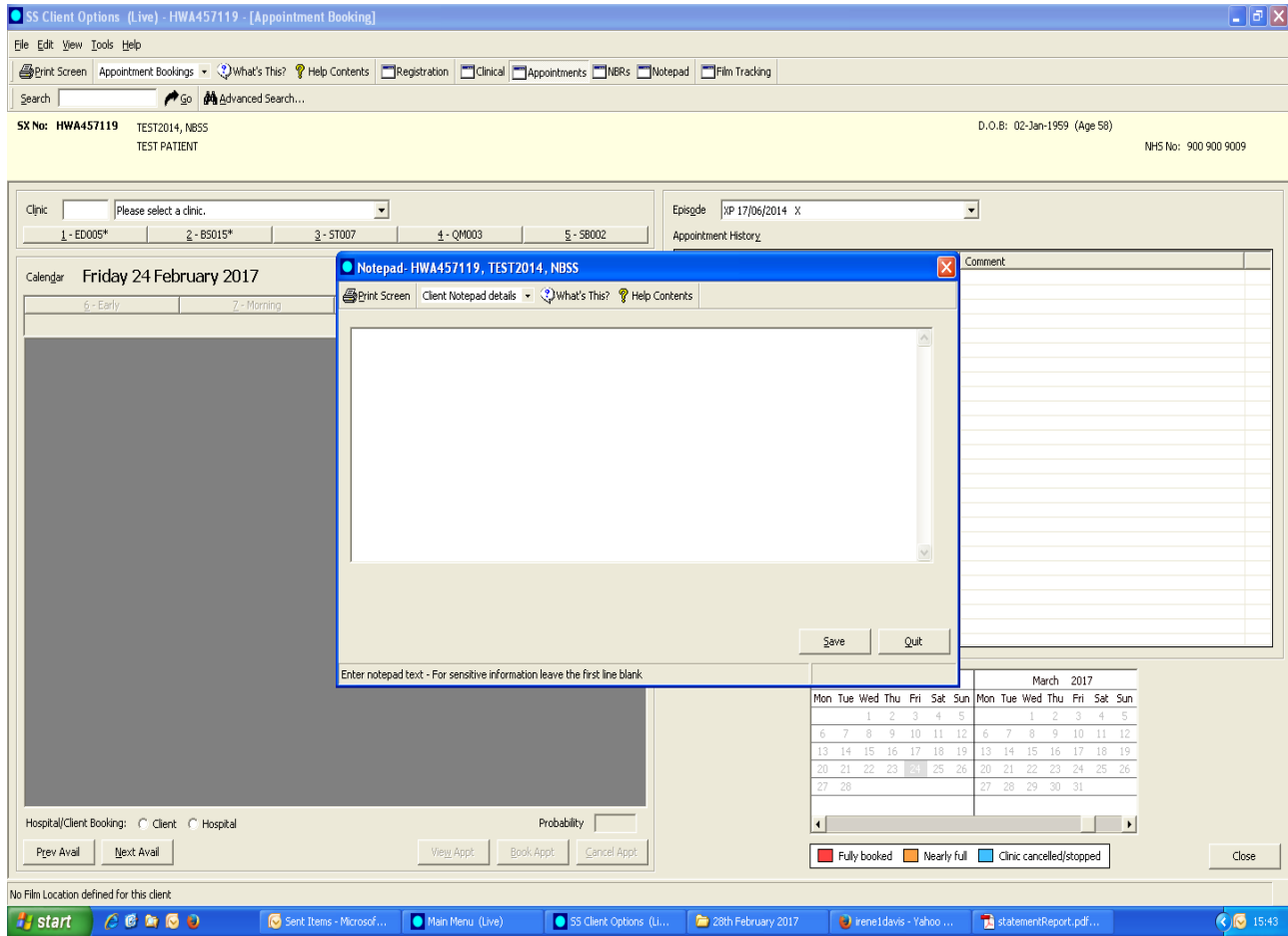
Appendix 1: BCSS 'special appointment'



Comments

The radiographer or administration team member should ensure that a special appointment is identified on the client registration and within the dropdown list, 'implants' should be selected.

Appendix 2: BCSS notes



Comments

The radiographer or administration team member should record any specific notes relating to the implant examination in notepad, for example 'consent withdrawn'.

If a woman suspects she has a ruptured implant, information should be entered on notepad to say that she has been advised to speak to her GP and that mammography will not be performed.

Appendix 3: protocol for mammographic imaging of women with breast implants

Version:	
Ratifying Committee:	
Date ratified:	
Name of originator/author/job title:	
Name of responsible committee/individual:	
Date published on intranet:	
Review date:	
Target audience:	

VERSION CONTROL SCHEDULE

Version number	Issue Date	Revisions from previous issue	Date of Ratification by Committee
1			
2			
3			
4			

CONTENTS

SECTION

- 1 Purpose of the document
- 2 Duties and Responsibilities of individuals and groups
- 3 Procedure for Mammographic Imaging of Women with Breast Implants

APPENDICES

- A Consent Form
- B Proforma letter

1. Purpose

The purpose of this document is to outline the procedure for obtaining diagnostic mammographic images of women with breast implants in a caring and safe manner

2. Duties and Responsibilities

The protocol team are responsible for appropriate ratification of the protocol.

The lead radiographer is responsible for the dissemination of this protocol to all appropriately trained and trainee mammographers. Ensure a framework exists for assessing individuals' competency.

The radiographers are responsible for:

- ensuring that they are adequately educated and trained in the Eklund technique. This education is obtained via the training DVD which is available at all breast screening services and also from colleagues who may have practical experience in the technique
- adhering to the national guidance
- ensuring they have seen the training DVD that is available
- adhering to the procedural guidelines and working within them
- understanding their limitations and when to seek advice
- being familiar with trust consent and mental capacity policies
- explaining the procedure fully to the woman
- signing the consent form prior to start of procedure
- ensuring the woman has signed consent form prior to procedure
- recognizing when consent has been withdrawn and stopping procedure immediately
- understanding that should rupture be suspected, not to undertake the examination but refer the client to her GP and ensure a letter is given to the client explaining the discussion

3. Procedure for Mammographic Imaging of Women with Breast Implants

1. Check ID and demographic details.
2. Take relevant clinical history and record on appropriate documentation/NHSBSP computer system.
3. Ensure a Consent Form is available.
4. The performing radiographer must explain to woman:
 - that there is an extremely small risk of rupturing the implant as a result of compressing the breast during mammography
 - that great care will be taken during compression, and the compression will be applied slowly and gently to the breast and only minimum compression to hold the breast will be used
 - that the examination is to assess breast tissue and not the condition of the implant
 - that 3 images of each breast will be taken – routine mammogram and Eklund or lateral view (where Eklund not achievable)
 - what the Eklund view will entail (consider the use of terminology: it is considered that 'easing the breast tissue forward away from the implant' is received better by the woman than 'manipulating the implant back onto the chest wall')
5. If the woman suggests that there may be a possibility that the implant/s is already damaged/ruptured **do not proceed** and ask her to speak with her G.P. She will be recorded as Attended Not Screened (ANS) on NBSS.
6. Once the woman has made an informed decision to continue they should sign the consent form (deleting sections as appropriate) prior to any imaging.
7. If the woman decides not to continue, then they should sign the consent form indicating this on the form
8. The radiographer should also sign the appropriate section of the consent form, whether the woman wishes to continue or not. This is the responsibility of the performing radiographer.
9. Perform medio-lateral views to identify the position of the implants as this may help to inform your practice.
10. Ensure the correct setting is selected on the equipment as per manufacturers' guidelines for imaging breast implants.

11. Perform Eklund views in the cranio-caudal position, explaining fully the technique to the woman. If you are unable to perform these images please document this on the breast screening computer system and client paperwork.
12. On completion of examination, inform the woman when to expect the results, then complete details on the national computer system.

Appendix 4: consent form

CONSENT TO SCREENING FOR SPECIAL IMAGES WITH BREAST IMPLANTS

Name:	Date of Examination:
Address:	Type of Implant (if known):
D.O.B:	Age of Implant (if known):
NHS No:	

Radiographer

I confirm that I have explained the procedure proposed

Name.....
 Signature.....
 Designation.....
 Date.....

Client/Patient

The radiographer has explained to me:

1. The technical and interpretational difficulties associated with imaging implants.
2. That there may be a small risk of rupturing the implants as a result of compressing the breasts for imaging although there is currently no evidence to support this.

I have therefore made an informed decision to *consent / *not consent to this additional examination (delete as appropriate)

Signature.....
 Date.....

Appendix 5: draft proforma letter

Thank you for attending your routine breast screening appointment today. While the radiographer was checking your details you said that you have breast implants and thought that one or both may be damaged (leaking or burst).

Checking breast implants is not undertaken by the breast screening service. We cannot screen women with suspected damaged implants, so we did not screen you today.

We recommend that you make an appointment with your GP to discuss your implants. He / she will be able to assess you and provide advice on what should happen next. This may be a referral for other breast tests, or a referral back to your previous surgeon.

The radiographer will note on the computer system that you have concerns about your implants and what we have recommended.

We are sorry we are unable to screen you today, but your safety is important to us. You are welcome to re-book a screening appointment once you know that your implants are not damaged.

References

- ⁱ Curtis, J & Borrelli C. (2013) Developing a national standard. *Imaging & Therapy Practice* ISSN: 1360 – 5518 <http://www.sor.org>
- ⁱⁱ Fajardo LL, Harvey JA, McAleese KA, Roberts CC, Granstrom P. (1995). Breast cancer diagnosis in women with subglandular silicone gel-filled augmentation implants. *Radiology* 1995;194:859-62.
- ⁱⁱⁱ Hayes H Jr, Vandergrift J, Diner WC. (1988) Mammography and breast implants. *Plastic Reconstructive Surgery* 82:1-8.
- ^{iv} Eklund GW, Busby RC, Miller SH, Job JS (1988). Improved imaging of the augmented breast. *AJR Am J Roentgenology* 151:469-73
- ^v Silverstein MJ, Handel N, Gamagami P. (1991) The effect of silicone-gel-filled implants on mammography. *Cancer* 1991;68 (suppl 5):1159-63.
- ^{vi} www.mhra.gov.uk/home/groups/dtsbi/documents/websiteresources/con2022634.pdf (Accessed on 5th December 2016)
- ^{vii} Guidance on screening and symptomatic breast imaging; third edition; Faculty of Clinical Radiology: RCR; June 2013
- ^{viii} Lavigne E, Holowaty E, Yi Pan S, Villeneuve PJ, Johnson KC, Fergusson DA, Morrison H, Brisson J. (2013) Breast cancer detection and survival among women with cosmetic breast implants: systematic review and meta-analysis of observational studies; *BMJ* 2013; 346 doi: <https://doi.org/10.1136/bmj.f2399>
- ^{ix} <http://wommen.org.uk/> (Accessed 14th February 2017)
- ^x Implant imaging techniques training DVD – St George's National Breast Education Centre & the Jarvis Training Centre