

Ministry of Defence

Synopsis of Causation

Acute and Chronic Soft Tissue Injuries: The Shoulder and Elbow

Author: Mr Donald Buchanan, Nottingham University Hospital, Nottingham
Validator: Mr Steve Mannion, Victoria Hospital, Blackpool

September 2008

Disclaimer

This synopsis has been completed by medical practitioners. It is based on a literature search at the standard of a textbook of medicine and generalist review articles. It is not intended to be a meta-analysis of the literature on the condition specified.

Every effort has been taken to ensure that the information contained in the synopsis is accurate and consistent with current knowledge and practice and to do this the synopsis has been subject to an external validation process by consultants in a relevant specialty nominated by the Royal Society of Medicine.

The Ministry of Defence accepts full responsibility for the contents of this synopsis, and for any claims for loss, damage or injury arising from the use of this synopsis by the Ministry of Defence

1. Definition

- 1.1. Acute soft tissue injury is a disruption of ligament, tendon or muscle as a result of a single episode of significant trauma in the recent past (usually interpreted as symptoms of less than 6 weeks duration).
- 1.2. Chronic soft tissue injury is a disruption of ligament, tendon or muscle as a result of a single or multiple episodes of significant trauma that continue to produce symptoms after 6 weeks.
- 1.3. Overuse injury refers to symptoms arising in tendon, muscle or ligament that are attributed to multiple insignificant trauma or repeated normal use.
- 1.4. Significant trauma is trauma sufficient to cause bruising, swelling and some loss of function of the limb at the time of injury.
- 1.5. Insignificant trauma is trauma not sufficient to cause bruising, swelling and loss of function at the time of injury.
- 1.6. Anatomical instability of a joint is movement of a joint in an abnormal plane, which can be demonstrated on clinical examination or stress x-rays.
- 1.7. Functional instability of a joint is a subjective feeling by the patient that the joint is unreliable.

2. Anatomy

2.1. Shoulder joint

- 2.1.1. The shoulder joint is a ball and socket joint formed by the head of the humerus and the glenoid cavity of the scapula. The glenoid cavity or socket is deepened by a fibrous ring, the glenoid labrum, which is attached to its margin.
- 2.1.2. Surrounding the shoulder joint is a fibrous capsule or sack. Anteriorly (i.e. at the front) and inferiorly the capsule is thickened to form ligaments which strengthen the capsule and reduce the risk of shoulder dislocations.
- 2.1.3. Stability is also provided by the rotator cuff. The rotator cuff consists of the supraspinatus, infraspinatus, teres minor, and subscapularis muscles.
- 2.1.4. The shoulder joint works in concert with the sternoclavicular, acromioclavicular and scapulothoracic joints, which also form part of the shoulder girdle. Any discussion of shoulder injuries will also refer to these other joints.

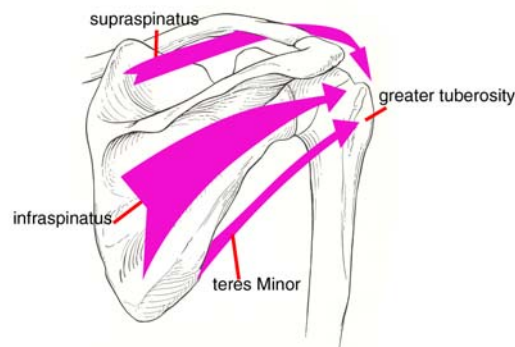


Figure 1: The shoulder joint

2.2. Elbow joint

- 2.2.1. The elbow joint is a hinge joint formed between the ulna and humerus. The radius articulates with the ulna and the humerus thereby forming part of the elbow joint.
- 2.2.2. The hinge like articulation of the elbow joint coupled with the opposing tension of the muscles at the front and back of the elbow create a stable elbow.

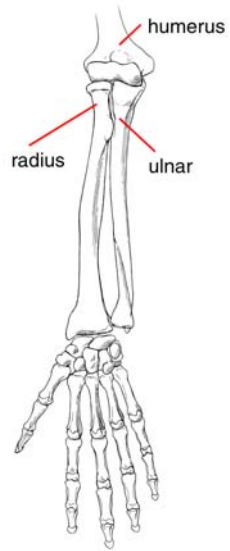


Figure 2: The elbow joint

3. Clinical Features

- 3.1. The cumulative annual incidence of shoulder disorders ranges from 7 to 25 per 1000 general practice consultations.¹ Five per cent of general practice consultations are related to shoulder disorders.² Of all the joints in the body, the shoulder joint has the greatest range of movements. Joint stability is sacrificed to achieve this excellent range of movement. This predisposes the shoulder to a variety of injuries.
- 3.2. **Shoulder instability** is defined as the inability to maintain the humeral head centred in the socket of the shoulder joint.³ There is variation in the degree of instability from apprehension through subluxation to dislocation.
- 3.2.1. **Apprehension** refers to the fear that the shoulder will subluxate or dislocate. This may prevent the individual from participating fully in work or sports.
- 3.2.2. **Subluxation** is defined as displacement of the humeral head away from the glenoid without complete separation of the joint surfaces. This is usually transient.
- 3.2.3. **Dislocation.** The shoulder joint may dislocate at the front (anterior dislocation) or back (posterior dislocation).
- 3.2.4. The patient with an **anterior dislocation** presents with pain in the shoulder. The shoulder is held with the arm by the side and there is loss of the normal shoulder contour. The acromion is prominent and a bulge is often seen on the anterior aspect of the shoulder. There may be associated neurological and vascular injuries around the shoulder with this injury.
- 3.2.5. Anterior dislocation is the most common variety. **Posterior dislocations** make up only 2-4% of all dislocations. However they are frequently locked and are often misdiagnosed. Posterior dislocations are missed in over 60% of cases.
- 3.2.6. In a posterior dislocation the arm is held at the side and rotated inwards. The classic features on examination are:
- Restriction in the ability to rotate the arm outward
 - Limitation in lifting of the arm
 - Prominence and rounding of the back of the shoulder in comparison to the normal side
 - Flattening of the front of the shoulder
 - Prominence of the coracoid process on the dislocated side
 - The head of the humerus is often impaled on the posterior rim of the glenoid
- 3.3. **Impingement syndrome and rotator cuff disease**
- 3.3.1. **Primary impingement.** Outlet or primary subacromial impingement is caused by encroachment of the rotator cuff between the greater

tuberosity and the coracoacromial arch or the acromioclavicular joint. Neer classified subacromial impingement into 3 stages: ⁴

- Stage 1. This is categorised by swelling of and bleeding into the subacromial bursa and supraspinatus tendon as a result of repeated minor injury
- Stage 2. The inflammatory process produces fibrosis and tendonitis in the supraspinatus tendon insertion
- Stage 3. There is tendon failure and tearing of the rotator cuff

3.3.2. **Secondary impingement.** In young patients, particularly in athletes, impingement is frequently caused by problems such as unrecognised instability of the shoulder joint, contracture at the back of the shoulder capsule, thickening of the subacromial bursa and rotator cuff dysfunction. It is a common cause of shoulder pains in athletes and often results from pre-existing ligamentous laxity or acquired laxity following trauma.

3.3.3. **Internal impingement.** At extremes of shoulder movement when the arm is brought above the head and backwards, the head of the humerus and rotator cuff abut against the glenoid. Such repetitive contact results in damage to the joint surface.

3.3.4. **Rotator cuff disease.** Injury to the rotator cuff in younger athletes typically results from overuse or occasionally from acute traumatic rupture.

3.4. **Biceps tendon disorders**

3.4.1. **Biceps tendonitis.** Patients with biceps tendonitis have pain at the front of the shoulder which is made worse by overhead activity. This usually occurs in association with subacromial impingement. On examination there is pain and tenderness over the front of the shoulder.

3.4.2. **Biceps subluxation.** Examination reveals pain with clicking and palpable subluxation of the tendon with rotation of the arm.

3.4.3. **Superior labral lesions.** The tendon of the long head of the biceps attaches to the labrum at the superior glenoid tubercle. The superior labrum anterior posterior (SLAP) lesion involves the glenoid attachment of the superior labrum posteriorly and extends anteriorly into the biceps anchor and anterior superior labrum. These lesions are classified into 4 groups:

- Type 1. Lesions demonstrate fraying of the superior labrum
- Type 2. The biceps anchor is disrupted
- Type 3. Lesions have a bucket handle tear of the labrum with central displacement of the intact biceps anchor
- Type 4. Lesions have a bucket handle tear of the labrum with detachment of the biceps anchor

3.4.4. Patients usually complain of a popping sensation in the shoulder and have deep shoulder pain with overhead activity. Careful assessment of

shoulder stability should be performed in these patients as the shoulder may be unstable and this may be a cause of treatment failure if not recognised. The diagnosis may be confirmed by magnetic resonance imaging (MRI) and MR arthrography, but the preferred definitive method of diagnosis is by arthroscopic examination.

3.5. Injuries to the acromioclavicular joint

3.5.1. **Acute injuries.** Post (1985) described 6 types of acromioclavicular dislocations:

- In Type 1 injuries there is a sprain to the acromioclavicular ligaments. The acromioclavicular and coracoclavicular ligaments remain intact
- In Type 2 injuries the acromioclavicular ligaments are disrupted but the coracoclavicular ligaments remain intact
- In Type 3 injuries there is disruption of both the acromioclavicular and the coracoclavicular ligaments with resulting complete separation of the acromioclavicular joint and displacement of between 50% and 100%
- Type 4 injuries involve posterior displacement and penetration of the trapezius muscle by the outer end of the collar bone
- Type 5 injuries are characterised by marked superior displacement and more than a 100% increase in the coracoclavicular distance
- In Type 6 injuries the outer end of the collar bone dislocates to a subcoracoid position

3.5.2. In Type 1 and Type 2 acromioclavicular dislocations there is pain and swelling over the region of the acromioclavicular joint. Examination reveals tenderness at the acromioclavicular joint and pain on moving the arm across the chest.

3.5.3. Patients with a Type 3 dislocation have pain and a significant deformity of the acromioclavicular joint. The outer end of the collar bone is unduly prominent.

3.5.4. **Chronic injuries.** Patients present with pain localised to the superior aspect of the shoulder and frequently point to the acromioclavicular joint. Dislocation may be clinically evident.

3.5.5. The pain is more pronounced in overhead activities particularly during the follow through phase of a pitch. X-rays show narrowing of the acromioclavicular joint, spurs or osteolysis of the outer part of the collar bone.

3.6. Rupture of muscles around the shoulder

3.6.1. **Rupture of the pectoralis major.** This is an uncommon injury; the majority of cases occur between the ages of 20 and 40 years. Classification is as follows:

- Type 1 ruptures consist of a contusion or sprain

- Type 2 includes partial ruptures
 - Type 3 includes complete rupture of the muscle origin, muscle belly, the junction of the biceps muscle and its tendon, the biceps tendon, or avulsion of the insertion of its tendon
- 3.6.2. Patients present with a severe sharp pain or tearing sensation at the site of the rupture. There is significant swelling and bruising. If the rupture occurs in its proximal portion, the swelling and bruising are noted on the front of the chest wall. There is a prominent bulge of the front of the armpit due to the retraction of the muscle. Rupture of the distal portion causes swelling and bruising of the arm. The muscle retracts towards the sternum and the fold at the front of the armpit becomes thin. There is tenderness at the site of the rupture and often a visible or palpable defect is noticed. Resisted adduction and internal rotation of the arm is weak and accentuates the defect and pain. Although plain x-rays and CT scans help to confirm the diagnosis, MRI scan is the investigation of choice.
- 3.6.3. **Rupture of the biceps.** Patients report a tearing or popping sensation in the arm with an indirect injury. This is followed by severe pain, swelling and loss of strength. A visible and palpable defect in the muscle may be noted if the patient is seen before significant haematoma and swelling occur. The humerus may be palpable through the defect. The overlying skin may show contusion or abrasion. In Heckman and Levine's series injury to the musculocutaneous nerve was common;⁶ however permanent paralysis of the muscle rarely occurs. The diagnosis may be confirmed by ultrasound or MRI scans.
- 3.6.4. **Rupture of the subscapularis.** Patients present with pain on the front of the shoulder that is troublesome at night. There is weakness when the arm is used above and below the shoulder level. If the shoulder is passively rotated outward, the range of movement is increased. Internal rotation is restricted and weak. The long head of the biceps is often dislocated towards the midline or it may be ruptured. The diagnosis is confirmed by ultrasound, CT arthrography or MRI scanning.

3.7. Neurovascular injuries

- 3.7.1. **Suprascapular nerve compression.** The suprascapular nerve supplies the supraspinatus and infraspinatus muscles. The patient presents with pain at the back of the shoulder and weakness of the shoulder. On examination there may be wasting of the supraspinatus and infraspinatus muscles. Weakness of the supraspinatus and infraspinatus is noticed.
- 3.7.2. **Long thoracic nerve palsy.** Patients present with pain. However, with early or incomplete weakness, symptoms may be subtle and include an uncomfortable feeling of pressure from a chair against the winged scapular while sitting, difficulty with weight lifting or elevation of the shoulder. With complete lesions, shoulder elevation is limited to about 110°. Patients may present with pain which mimics impingement. On examination, winging of the shoulder blade is provoked by resisted

active elevation of the arm or by pushing against the wall with both hands.

3.7.3. **Spinal accessory nerve paralysis.** Patients present with sagging of the shoulder with an inability to raise the shoulder beyond a horizontal position. There is pain from chronic strain on the muscles around the shoulder girdle. Patients may also present with evidence of impingement because of the inability to rotate the acromion away from the greater tuberosity. On examination there is drooping of the shoulder and deepening of the supraclavicular fossa as a result of atrophy of the trapezius muscle. Winging of the shoulder blade occurs when the arm is raised against resistance. EMG examination is used to confirm the diagnosis and to document recovery of the nerve.

3.8. **Lateral tendonosis (tennis elbow)**

3.8.1. Tennis elbow commonly presents between the age of 35 and 50 years. It is equally common in males and females.

3.8.2. Patients present with pain over the outer aspect of the elbow which may radiate to the forearm. The pain is usually chronic and bothersome rather than disabling. There is weakness with grasping; shaking hands and carrying a cup aggravate the pain.

3.8.3. Physical examination reveals tenderness over the outer aspect of the elbow. Pain is produced by extending the wrist against resistance particularly when the palm faces downwards.

3.8.4. Microscopic evaluation of tissue from patients with tennis elbow has shown proliferation of blood vessels and fibrous tissue rather than evidence of inflammation.⁷ The origin of the extensor carpi radialis brevis muscle is most commonly involved but the extensor digitorum communis and extensor carpi radialis longus muscles may also be involved.

3.9. **Medial tendonosis (golfer's elbow)**

3.9.1. This involves the muscles arising from the inner aspect of the elbow specifically the origins of pronator teres and flexor carpi radialis. It is more common in young adults and twice as common in males as in females.

3.9.2. Patients present with medial elbow pain of insidious onset, radiating into the forearm. Weakness of the grip may be noted. Half of the patients have evidence of irritation of the ulna nerve.

3.10. **Posterior tendonosis**

3.10.1. Tendonosis involving the insertion of the triceps tendon is uncommon.

3.10.2. Patients present with acute or chronic onset of pain at the triceps insertion which is aggravated by active or resisted extension of the elbow. The triceps insertion is tender to palpation.

3.11. **Triceps tendon rupture**

3.11.1. Rupture of the triceps tendon is rare; it accounts for about 2% of all tendon injuries. The male to female ratio is 3:2 and the mean age of occurrence is 33 years. Failure of the distal triceps musculotendinous unit usually involves avulsion from the olecranon but may also involve rupture of the muscle belly or musculotendinous junction.

3.11.2. Patients present with sudden onset of pain on the posterior aspect of the elbow following a traumatic event. Physical examination reveals swelling, bruising and a palpable depression proximal to the olecranon. Elbow extension strength is reduced and the patient is unable to extend the elbow against gravity. X-rays may reveal a small avulsion fracture of the olecranon.⁸ When the triceps tendon is weakened by degenerative changes, rupture may follow minor trauma. The rupture may be incomplete and diagnosis may be delayed.

3.12. **Distal biceps tendon injury**

3.12.1. Avulsion of the distal biceps tendon occurs most commonly in middle-aged muscular males.

3.12.2. In an acute injury, patients present with a sudden, sharp, tearing type pain. In a chronic injury there is swelling and activity related pain in the antecubital fossa. Other findings include bruising at the front of the elbow, a palpable defect in the distal biceps, loss of strength of elbow flexion, grip and supination. The rupture can be localised by ultrasound or MRI scan.

3.13. **Acute dislocation of the elbow.** The patient presents with a painful deformed elbow. Assessment of the brachial artery, median and ulnar nerve is carried out. Anterior, posterior and lateral x-rays of the elbow should be reviewed to exclude fractures of the distal humerus, radial head and coronoid process.

3.14. **Ulnar collateral ligament injury.** Patients present with pain of acute or insidious onset on the medial aspect of the elbow. Pain and tenderness are localised to the inner aspect of the elbow. Pain, numbness and tingling are seen frequently in the ring finger and little finger in these patients. With the elbow flexed to 15° to unlock the olecranon from the olecranon fossa, a valgus stress is applied to the elbow. Valgus instability is seen in 50% of the patients. Stress radiographs and MRI may also aid in diagnosis.

4. Aetiology

4.1. Soft tissue injuries of the shoulder commonly arise as a result of involvement in sports and have been estimated to comprise between 8-13% of all athletic injuries.⁹ Adult males are commonly affected. The injuries in contact sports such as football, hockey and wrestling result from direct trauma while sports which involve overhead activity such as tennis, baseball, volleyball and swimming produce repetitive overuse syndromes.

4.2. **Shoulder instability**

Mechanism of instability

4.2.1 Instability may arise from direct trauma to the shoulder with damage to the joint surfaces, labrum, capsule, rotator cuff and/or a combination of ligaments. These shoulders are “torn loose”. Instability may also arise from atraumatic decompensation of the stabilising mechanisms of the shoulder joints. Some of these shoulders were “born loose” whereas in others they are loose because of injury.

4.2.2 Instability seen within the first few days after the onset is referred to as acute, otherwise it is chronic. A locked or fixed dislocation refers to one in which the humeral head is impaled on the rim of the glenoid thereby making reduction of the dislocation difficult. If the shoulder joint is unstable on multiple occasions, this is referred to as recurrent instability.

4.2.3 Patients with recurrent instability fall into two groups. In some there is a clearly defined traumatic cause for the instability and the instability is unidirectional. These have obvious pathology, such as a Bankart lesion, (see section 4.2.8) and frequently require surgery.

4.2.4 There are other patients whose instability is atraumatic in origin, these have multidirectional laxity, both shoulders are involved and they usually respond to a rehabilitation programme. These patients infrequently require surgery; should it be necessary, surgery involves the capsule of the shoulder joint.

4.2.5 In practice, patients present anywhere along the spectrum from traumatic to atraumatic shoulder instability. Many patients show elements of both types.

4.2.6 Some patients can intentionally subluxate or dislocate the shoulder. This is referred to as voluntary instability. If the instability occurs unintentionally, it is referred to as involuntary. Voluntary and involuntary instability often co-exist.

4.2.7 Neuromuscular causes of shoulder instability are infrequent and have been attributed to encephalitis, and cerebrovascular accidents.

Direction of instability

- 4.2.8 **Anterior dislocations.** Ninety per cent of shoulder dislocations are anterior. They commonly occur in young adults as a result of direct trauma such as in falls and sports injuries. In young individuals, anterior dislocations are accompanied by a fracture of the anterior glenoid or the detachment of the glenoid labrum, the so-called Bankart lesion. In individuals more than 40 years old, there is often a tear in the anterior capsule, which is sometimes accompanied by a tear in the subscapularis.^{10,11}
- 4.2.9 **Posterior dislocations.** These dislocations result from axial loading of the adducted internally rotated arm, from violent muscular contraction from electrical shock or from convulsive seizures. The strength of the internal rotators, latissimus dorsi, pectoralis major and subscapularis exceeds that of the external rotators, infraspinatus and teres minor. As a result, with forced involuntary muscle contraction the humeral head is rotated internally and is displaced backwards.
- 4.2.10 **Inferior dislocations.** These are rare injuries which are produced by a hyperabduction force to the shoulder joint resulting in abutment of the neck of the humerus against the acromion. The head of the humerus is levered out of the glenoid and displaced inferiorly. The humerus is locked in a position between 110° and 160° of abduction. Severe soft tissue injury or fractures around the proximal humerus occur with this dislocation.
- 4.2.11 **Superior dislocation.** This uncommon dislocation occurs because of an extreme forward and upward force on an adducted arm. Fractures may occur to the acromion, acromioclavicular joint, clavicle, coracoid process or humeral tuberosities. Soft tissue injuries occur to the capsule, rotator cuff, biceps tendon and surrounding muscles.
- 4.2.12 **Bilateral dislocations.** These are rare injuries which result from convulsions or violent trauma.
- 4.3. **Impingement syndrome and rotator cuff disease**
- 4.3.1. **Primary impingement.** Causes include abnormal acromial morphology, acromial spurs and acromioclavicular joint arthritis.
- 4.3.2. **Secondary impingement.** Repetitive demands of overhead sports can produce attenuation of the capsular ligaments or injury to the rotator cuffs or biceps tendon. The pathological laxity causes the humeral head to translate forward thereby producing impingement of the supraspinatus tendon against the coracoacromial arch.
- 4.3.3. **Internal impingement.** This is seen in individuals who engage in overhead activities, particularly in throwing athletes. Paley et al carried out arthroscopic evaluation of 41 professional overhand throwing athletes with shoulder pain. One hundred per cent of the subjects had either contact between the rotator cuff undersurface and the posterior

superior glenoid rim or osteochondral lesions. Other findings include under surface cuff fraying in 93% and posterior superior labral fraying in 88% of these athletes.¹²

- 4.3.4. **Rotator cuff disease.** Injury to the rotator cuff in younger athletes typically results from chronic subtle injury as a result of overuse or occasionally from acute traumatic disruption. Repetitive stress and subacute injury from the throwing motion can lead to diminished tensile strength and elasticity of the cuff tendons with inflammation, degeneration, calcification and tearing of the cuff.

4.4. **Biceps tendon disorders**

- 4.4.1. **Biceps tendonitis.** This is seen in those who are frequently involved in activities which place the arm at or above shoulder level. The biceps tendon and adjacent areas on the head of the humerus impact against the acromion and coracoacromial arch and cause injury either as a single event or through repetitive injury.
- 4.4.2. **Biceps subluxation.** Forceful extension or external rotation of the adducted shoulder can cause a tear of the subscapularis insertion and disruption of the transverse humeral ligament, thereby allowing the biceps tendon to either subluxate or dislocate from its groove.

4.5. **Injuries to the acromioclavicular joint**

- 4.5.1. **Acute injuries.** The commonest cause of acute traumatic injury to the acromioclavicular joint is a fall onto the shoulder or a direct blow to the acromion. Acute injuries to the acromioclavicular joint commonly occur in sports such as football, ice hockey and rugby. Partial or complete disruption of the acromioclavicular and/or coracoclavicular ligament may occur.
- 4.5.2. **Chronic injuries.** Following chronic repetitive loading or after a traumatic injury to the acromioclavicular joint, degenerative changes may occur.

4.6. **Rupture of muscles around the shoulder**

- 4.6.1. **Rupture of the pectoralis major.** Pectoralis major rupture follows direct trauma, extreme muscle tension, a combination of the above, or it may occur spontaneously. McEntire et al reported 56 cases of pectoralis major rupture; 37 cases were caused by excessive muscle tension, 9 were caused by direct trauma, 4 by a combination of trauma and excessive muscle tension, and spontaneous rupture was reported in 3 cases.¹³
- 4.6.2. The most common mechanism of injury is weight lifting (46%), 30% of injuries result from bench press exercises. Hanna reported on 12 cases of pectoralis major rupture which occurred by playing rugby.¹⁴
- 4.6.3. In the series by Wolfe et al, patients reported that the rupture occurred during the bench press with the bar at its lowest point and the shoulders extended to 30°. The fibres of the lowest portion of the sternal head are then disproportionately stretched. Application of maximum load to the

inferior fibres which are stretched to an extreme mechanical disadvantage leads to rupture of these fibres. Tension within the remaining fibres of the sternal head causes it to fail as a result of continued loading.¹⁵ Pectoralis major rupture also occurs when a person attempts to break a fall and severe force is applied to a maximally contracted pectoralis major muscle.

- 4.6.4. Direct trauma tears the muscle belly, while excessive muscle tension causes avulsion of the humeral insertion or disruption at the musculotendinous junction.
 - 4.6.5. Partial tears of pectoralis major occur at the musculotendinous junction and are more common than complete tears, which occur at the tendon bone interface.
 - 4.6.6. **Rupture of the biceps.** This may occur because of indirect injury from traction applied to a contracting biceps muscle. Direct injury may occur in military parachutists. Heckman and Levine reported on more than 50 patients with closed transaction of the biceps in a population of 40,000 paratroopers taking over 10,000 parachute jumps annually.⁶ The static line is a 2cm wide woven nylon strap which is attached to the paratrooper's pack and aircraft. If the static line is positioned incorrectly in front of the arm, a severe force may be applied over the biceps if the arm is simultaneously abducted after push off.
 - 4.6.7. **Rupture of the subscapularis.** This is caused by violent external rotation of the adducted arm or by violent hyperextension. This injury may also occur in motor vehicle accidents and is frequently seen in association with anterior shoulder dislocations in patients above 40 years of age.
 - 4.6.8. **Rupture of the infraspinatus.** The spontaneous rupture of the infraspinatus muscle from its scapular origin has been reported. It occurred as a result of forced internal rotation and adduction of the shoulder as a result of a fall from a chair. The patient was treated conservatively and had a good outcome.
 - 4.6.9. **Rupture of the teres major.** This is an uncommon injury. A case was reported in which there was an isolated tear of the teres major muscle during a water skiing injury. The injury occurred when a sudden forward force applied to the tow rope jerked the patient's arm forward.
 - 4.6.10. **Rupture of coracobrachialis.** This is an uncommon injury. One case was reported in which the rupture occurred as a result of direct violence. A second case was described in which a parachutist sustained a direct injury as a result of his static line.
- 4.7. **Neurovascular injuries**
- 4.7.1. **Suprascapular nerve compression.** The nerve may be injured by blunt trauma to the suprascapular fossa or by fractures of the scapula which involve the suprascapular notch. It is susceptible to injury with traction, depression, hyperabduction or repetitive movements of the shoulder. Compression may also occur as a result of a ganglion or a tumour.

- 4.7.2. **Long thoracic nerve palsy.** The nerve can be injured by traction on the neck or shoulder or by blunt trauma. Long thoracic nerve palsy may also follow viral illnesses.
- 4.7.3. **Spinal accessory nerve paralysis.** The nerve may be injured by a direct blow or a traction injury. It is also injured during surgical approaches to the posterior triangle of the neck.
- 4.8. **Lateral tendonosis (tennis elbow).** Individuals who perform repetitive wrist extension against resistance are at risk. It is associated with sporting activities such as tennis, baseball, golf, squash, racket ball, swimming, weight lifting and throwing the javelin.
- 4.9. **Medial tendonosis (golfer's elbow).** Throwers, golfers, bowlers, racket sportsmen and swimmers are commonly affected.
- 4.10. **Posterior tendonosis.** It results from excessive overuse and strain of the triceps insertion. There is an association with osteophytes, loose bodies and synovitis of the posterior compartment of the elbow.
- 4.11. **Triceps tendon rupture.** The mechanism of injury is a fall on the outstretched arm or a direct blow to the elbow. Tendon ruptures have been linked with systemic and local steroid usage. Patients with olecranon bursitis and systemic disease such as diabetes, renal osteodystrophy and systemic lupus erythematosus also have a high risk of rupture of the triceps tendon.
- 4.12. **Distal biceps tendon injury.** It is common in weight lifters; the mechanism is a sudden contraction of the biceps against significant load with the elbow in 90° of flexion. It also occurs during catching, lifting or pulling a heavy object. A direct blow to the flexed biceps tendons can also cause it to rupture.
- 4.13. **Acute dislocation of the elbow.** The precise mechanism of dislocation is unknown. It has been postulated that the position of greatest vulnerability is the extended elbow. During a fall, force is transmitted to the extended elbow: an anterior force is generated which levers the ulna out of the trochlea.¹⁵ As the elbow hyperextends, the anterior capsule and collateral ligaments are stressed and eventually fail.
- 4.14. **Ulnar collateral ligament injury.** The anterior bundle of the medial collateral ligament is the major static stabiliser of the elbow against valgus stress. Rupture of the medial collateral ligament may occur acutely in those involved in throwing sports such as baseball, football and javelin throwing. Microscopic tears or attenuation may also lead to insufficiency of the medial collateral ligament.

5. Treatment and Prognosis

- 5.1. Treatment and prognosis for the conditions described in the earlier sections is as follows.
- 5.2. **Shoulder instability**
- 5.2.1. **Anterior dislocations.** Reduction should be performed promptly after the trauma series x-rays have been taken. It is acceptable to reduce the dislocation of a patient in the field prior to obtaining X-rays. X-rays help to exclude associated fractures of the glenoid, tuberosities and ipsilateral neck of the humerus, which may require treatment. Numerous reduction techniques are available.
- 5.2.2. In the self-reduction technique, the patient clasps his or her fingers and places them around the flexed knee. The patient then leans backward and reduction occurs. Alternatively the physician may grasp the patient's arm by the wrist and apply traction at a 45° angle while counter traction is provided by a foot on the patients chest wall or by an assistant wrapping a sheet around the patient's torso.
- 5.2.3. In the gravity method (modified Stimson's method), the patient is placed prone with the affected shoulder supported and the arm hanging over an examination table with a weight strapped to the hand. Five pounds is adequate, however, more muscular patients may require more weight.
- 5.2.4. When reduction is delayed there is significant muscle spasm and there is a greater need for analgesia with narcotics and benzodiazepines. Failure of the above necessitates the use of general anaesthesia.
- 5.2.5. After reduction, the shoulder was traditionally immobilised with the arm in internal rotation in an adducted position. Hovelius showed that there was a high rate of recurrent dislocation irrespective of the duration of the immobilisation.¹⁷ Itoi et al showed that by immobilising the shoulder in external rotation, the Bankart lesion is displaced laterally and opposed towards the glenoid margin. His early studies showed there was a significant reduction in the risk of recurrent dislocation.¹⁸ The incidence of recurrent dislocation of the shoulder has also been reduced by arthroscopic washout of the shoulder and removal of the haemarthrosis.
- 5.2.6. **Posterior dislocations.** Closed reduction of the posterior dislocation should be attempted. This is often unsuccessful because these patients usually present late. Open reduction is then required and stability is achieved through the McLoughlin procedure in which the subscapularis tendon is transferred into the defect in the humeral head. Alternatively in the modified McLoughlin procedure, the lesser tuberosity is osteotomised and transferred into the defect in the humeral head.

Defects of up to 40% of the humeral head may require bone grafting whereas defects greater than 40% will require hemiarthroplasty.

5.2.7. **Recurrent dislocation** of the shoulder can be quite disabling and is associated with a loss of productivity. In patients under 20 years old with an acute anterior dislocation treated conservatively there is an 85% probability of recurrence. Over all ages, there is a mean 67% incidence of recurrent dislocation. It has been shown that there is a high incidence of osteoarthritis of the shoulder in patients with recurrent dislocations. Recurrent dislocations of the shoulder are treated by a variety of procedures including Bankart repair which can be done either as an open procedure or arthroscopically. The redislocation rate may be as low as 6% following arthroscopic repair in patients with anterior dislocations. Advantages of arthroscopic repair include shorter hospitalisation, lower morbidity, less postoperative pain, earlier recovery of strength and minimal loss of movement in the shoulder. A variety of procedures are used for open repair of recurrent anterior dislocations; in some the recurrence rate is as low as 1%.

5.3. **Impingement syndrome and rotator cuff disease**

5.3.1. Treatment of impingement and partial thickness rotator cuff tears consists of a trial of activity modification, anti-inflammatory medication, corticosteroid injections and physical therapy. Physical therapy focuses on capsular stretching as these patients may have posterior capsular contractures. Rotator cuff strengthening enhances the strength of the rotator cuff and increases the dynamic stabilising effect on the glenohumeral joint. Periscapsular muscle strengthening helps to correct any abnormality of scapula movement.

5.3.2. Surgical intervention is indicated when there is a failure of nonoperative management or a full thickness rotator cuff tear is detected. In primary subacromial impingement, arthroscopic subacromial decompression is carried out with 85-90% satisfactory results. Where there is occult instability and secondary impingement, glenohumeral stabilisation should be considered.

5.3.3. Partial thickness rotator cuff tears (less than 50%) would benefit from debridement and subacromial decompression. Partial thickness tears greater than 50% or full thickness tears should be repaired, either arthroscopically or by an open procedure.

5.4. **Biceps tendon disorders**

5.4.1. **Biceps tendonitis**. Initial treatment is directed at the impingement syndrome. In refractory cases, corticosteroid injections into the bicipital sheath may be helpful. Surgical options for treatment include tendon debridement, release or tenodesis.

5.4.2. **Biceps subluxation**. Operative treatment is indicated when there is subluxation or dislocation of the tendon in association with a tear of the

subscapularis or if there are chronic refractory symptoms as a result of the subluxation or dislocation.

- 5.4.3. **Superior labral lesions** (see section 3.4.3 for injury types). Nonoperative treatment modalities include activity modification and physical therapy. Should nonoperative treatment fail, Type 1 and Type 3 lesions are treated with debridement and assessment for glenohumeral instability. Type 2 lesions can be treated with arthroscopic fixation of the biceps anchor. Most patients have a good or excellent outcome following stabilisation of Type 2 SLAP lesions. In Type 4 lesions, tenodesis or repair of the tendon is indicated.

5.5. Injuries to the acromioclavicular joint

- 5.5.1. **Acute injuries** (see section 3.5.1 for injury types). Type 1 and Type 2 injuries are stable and require symptomatic treatment and use of a sling for 1-2 weeks until the pain subsides. Subsequently a range of motion exercises and a shoulder strengthening programme is initiated.
- 5.5.2. Patients with a Type 3 dislocation have pain and a significant deformity of the acromioclavicular joint. The lateral end of the clavicle is unduly prominent. A conservative approach to treatment involves ice and immobilisation followed by exercises to regain motion and strength.
- 5.5.3. Surgical treatment is recommended for Type 4, 5 and 6 injuries in which there is severe displacement of the clavicle. The preferred treatment modality is the Weaver-Dunn procedure which involves resection of the distal clavicle, transfer of the coracoacromial ligament into the distal end of the clavicle and stabilisation of the coracoclavicular interval with sutures. Postoperatively the shoulder is immobilised in a sling for 6 weeks followed by range of motion and strengthening exercises.
- 5.5.4. **Prognosis for acute injuries.** Ninety per cent of patients with Type 1 and Type 2 injuries have a good outcome. Some patients may develop post-traumatic osteoarthritis of the acromioclavicular joint. Should this occur resection of the distal clavicle could be performed. Following Type 1 and Type 2 injuries most patients return to their full pre-injury level of activity.
- 5.5.5. With Type 3 dislocations, most athletes return to unrestricted activities in about 4-6 weeks with little or no symptoms or functional deficits. In labourers and athletes who are involved in high demand overhead activities, and for chronic injuries in which there is a failure of nonoperative treatments, surgical treatment is recommended.
- 5.5.6. Types 4, 5 and 6 injuries are rare and usually require operative treatment.
- 5.5.7. **Chronic injuries.** Nonoperative approaches to treatment include activity modification, use of non-steroidal anti-inflammatory

medication and injection of corticosteroids into the acromioclavicular joint. Those who fail to respond to nonoperative treatment could be treated by distal clavicle excision (Mumford procedure). This may be performed either by open or arthroscopic techniques. The success rate is 90%.

5.6. Rupture of muscles around the shoulder

- 5.6.1. **Rupture of the pectoralis major.** Partial ruptures respond to ice and rest. Heat, ultrasound and shoulder mobilising exercises help to restore shoulder function. Optimum return of function requires early surgical repair for complete rupture of the pectoralis major muscle. Tears of the musculotendinous junction can be repaired directly while tendinous avulsions can be anchored through drill holes in the humerus. Surgical treatment produces excellent results in 80% of patients.¹⁹
- 5.6.2. **Rupture of the biceps.** Heckman and Levine surgically repaired the defect in the biceps in 10 patients. Postoperatively the elbow was immobilised in acute flexion for 4 weeks and at 90° for an additional 2 weeks. In another group of 10 patients the haematoma was aspirated and the elbow was immobilised in acute flexion for 6 weeks. At follow up muscle power was identical, hence the preferred method of treatment for acute cases is to aspirate the haematoma and immobilise the elbow in flexion for 6 weeks.⁶
- 5.6.3. For subacute ruptures, the optimum treatment is open repair and immobilisation in acute flexion for 4 weeks followed by flexion at 90° for 2 weeks. In chronic cases, the decision to repair the muscle is influenced by the patient's occupation, the functional deficit and the concern about the cosmesis. In such cases the prognosis is guarded.
- 5.6.4. **Rupture of the subscapularis.** Operative treatment involves reinsertion of the subscapularis tendon into a bony trough on the lesser tuberosity. In Gerber's series, the Constant score (a measure for assessing outcomes of the treatment of shoulder disorders) increased to 82 following surgery, whilst the capacity of patients to work increased from an average of 59% of full capacity preoperatively to 95% postoperatively. The outcome following surgery was reduced where the delay was more than 36 months.²⁰
- 5.6.5. **Prognosis.** Bak et al in a meta-analysis of 112 cases of **rupture of the pectoralis major** noted that 88% of patients who were treated surgically had excellent or good results compared with 27% of those who were treated conservatively. More patients had an excellent outcome when surgery was performed within 8 weeks of injury.²¹ Nonoperative treatment is accompanied by varying degrees of weakness of adduction and internal rotation. The teres major, subscapularis, deltoid and latissimus dorsi slowly compensate for the deficiency in the pectoralis major. With nonoperative treatment some athletes are able to return to competitive sports but they usually display some weakness of the pectoralis major.

5.6.6. **Subscapularis rupture** is associated with recurrent instability of the shoulder. In a series by Neviasser et al, there were 37 patients older than 40 years who sustained a rotator cuff tear with anterior dislocation of the shoulder. Eleven of these patients developed anterior instability as a result of rupture of the subscapularis tendon and anterior capsule.¹⁰

5.7. Neurovascular injuries

5.7.1. **Suprascapular nerve compression.** Treatment is conservative. Rest from the initiating cause may be helpful. With shoulder rehabilitation a good outcome is possible. Refractory cases require surgical decompression to relieve the pain. Following surgical decompression there is relief of pain followed by return of strength and later return of muscle mass. Functional outcome is better if surgery is carried out before there is marked muscle wasting. The site of compression of the nerve can be localised by MRI scanning.

5.7.2. **Long thoracic nerve palsy.** Patients are treated expectantly. Passive range of motion exercises are required to prevent contracture. Muscle strengthening exercises begin when there is evidence of nerve recovery. For refractory cases, surgical reconstruction is carried out. The pectoralis minor or the sternal head of the pectoralis major may be transferred to the inferior angle of the scapula via a fascia lata graft (connective tissue from the thigh). With conservative treatment recovery may occur even after 2 years. However, it is generally agreed that after one year without clinical or myographic evidence of recovery the prognosis is poor.

5.7.3. **Spinal accessory nerve paralysis.** Closed injuries are treated expectantly for 6 months. Open injuries require exploration and repair of the nerve. If nerve function fails to recover, the disability may be accepted or surgical stabilisation of the scapula could be performed.

5.8. **Lateral tendonosis (tennis elbow).** Ninety percent of patients respond to nonoperative measures such as rest, activity modification, physiotherapy, non-steroidal anti-inflammatory drugs, counterforce bracing and occasional use of steroid injections to the site of maximum tenderness. Surgery is indicated if there is no response to nonoperative treatment over a 6 month period. There are several surgical options for treatment; overall they carry a success rate of 80%.

5.9. **Medial tendonosis (golfer's elbow).** Treatment is similar to that for lateral tendonosis. If nonoperative treatment fails the diseased tendon is excised and the deficit is closed.

5.10. **Posterior tendonosis.** Treatment involves the use of anti-inflammatories and rehabilitation.

5.11. **Triceps tendon rupture.** Partial ruptures may be treated by immobilisation in 30° of flexion for 3-6 weeks followed by physiotherapy. Complete ruptures are repaired primarily and reinforced by a mersilene band which is passed transversely through the olecranon and triceps tendon. The triceps tendon may

be reattached using suture anchors. Active elbow movement is initiated on the first postoperative day. Physiotherapy continues for 4-6 weeks. Full recovery usually occurs in 4 months.

- 5.12. **Distal biceps tendon injury.** Without repair there is a 30% loss of strength of elbow flexion and 40% loss of supination strength. In active individuals, primary repair is the treatment of choice. There are several techniques for reattachment of the avulsed distal biceps tendon. The techniques of Lange, Thomsen, as well as reattachment by suture anchors are the most successful in terms of restoring elbow movement, supination strength and minimising complications.²² Postoperatively the elbow is protected for 6-8 weeks followed by range of motion and gentle strengthening exercises. Unrestricted activities are allowed after 6 months. A partial rupture of the distal biceps is treated nonoperatively. Surgical repair is indicated for persistent symptoms.

5.13. **Acute dislocation of the elbow**

5.13.1. **Treatment.** Reduction is carried out under appropriate anaesthesia after which joint stability and range of motion are assessed. If the elbow is stable at 30° flexion, a sling is used and active motion in the sling is allowed without delay. The elbow that is stable beyond 45° of flexion is splinted in 90° of flexion and neutral pronation/supination. Active movement is allowed after 5-10 days. If the elbow is only stable in extreme flexion, repair of the collateral ligaments is indicated.

5.13.2. **Prognosis.** Most patients have full recovery of motion and strength by 3-6 months. Some patients have flexion contracture of 10-15°. Recurrent dislocation is rare.

- 5.14. **Ulnar collateral ligament injury.** Treatment involves rest, non-steroidal anti-inflammatory drugs and physiotherapy. Surgery should be considered if the patient fails to respond to 3 months of nonoperative treatment. The medial collateral ligament is reconstructed using a palmaris longus tendon graft. About 80% of patients are able to return to their pre-injury sports at one year postoperatively.

6. Related Synopses

Recurrent Dislocation of the Shoulder

Tennis Elbow

7. Glossary

acromioclavicular	The articulation between the clavicle and the acromion of the scapula.
acromion	Triangular projection of the scapula that forms the point of the shoulder and articulates with the clavicle.
arthroscopic	Referring to arthroscopy, a procedure that involves the insertion of a fiberoptic scope into a joint space to examine the internal structures; in some cases surgical repairs may be carried out via this method.
cerebrovascular	Pertaining to the blood vessels of the brain.
coracoid	A process (protrusion) on the scapula.
coracoacromial	Relates to the coracoid and acromial processes.
debridement	The removal of damaged, dead or infected tissue.
encephalitis	Inflammation of the brain.
fossa	Depression or hole within a structure.
glenoid	Socket-like, applied to several joint surfaces of bones, in this case the scapula.
glenoid cavity	Part of scapula in which the humerus articulates (also known as the glenoid fossa).
glenohumeral	Relating to the glenoid cavity and the humerus.
hemiarthroplasty	Arthroplasty (the surgical repair of a joint) where one joint surface is replaced by artificial material.
humerus	Bone of the upper arm.
infraspinatus	Muscle of the shoulder which inserts at the scapula and humerus.
labrum	A lip or edge. In the shoulder, the rim of the shoulder socket is surrounded by fibrocartilaginous thickening known as the labrum. This plays an important role in stabilising the shoulder joint.
latissimus dorsi	Muscle of the back.
ligament	A band of fibrous tissue that joins bones and cartilage.

olecranon	Large process at the proximal end of the ulna which projects behind the elbow joint to form the bony prominence of the elbow.
osteolysis	The dissolving of bone, often due to calcium loss.
osteotomise	Surgical cutting of bone.
refractory	Not readily responding to treatment.
rotator cuff	Tendon which stabilises the head of the humerus within the shoulder joint, and which is formed by the teres minor, supraspinatus and infraspinatus muscles.
scapula	Large, flat, triangular bone at the back of the shoulder.
sternoclavicular	Relating to the sternum and clavicle.
subscapularis	Muscle of the shoulder which inserts at the scapula and humerus.
supraspinatus	Muscle of the shoulder which inserts at the scapula and humerus.
synovitis	Inflammation of a synovial membrane, a fluid-producing membrane that lines some joints and allows free movement of the joint.
tendonitis	Inflammation of a tendon.
tendonosis	Tendon injury relating to overuse and not to inflammation.
tenodesis	Stabilisation of a joint by anchoring the tendons that move it.
teres minor	Muscle of the shoulder which inserts at the scapula and humerus.
tuberosity	A large rounded elevation on the surface of a bone.

8. References

1. Van der Windt D, Koes BW, De Jong BA, Bouter LM. Shoulder disorders in general practice: incidence, patient characteristics and management. *Ann Rheum Dis* 1995;54:959-64.
2. Peters D, Davies P, Pietroni P. Musculoskeletal clinic in general practice: study of one year's referrals. *Br J Gen Practice* 1994;44:25-9.
3. Rockwood CA Jr, Matsen FA III, Wirth MA, Lippitt SB. The shoulder. 3rd ed. Philadelphia, PA: Saunders; 2004.
4. Neer CS 2nd. Impingement lesions. *Clin Orthop Relat Res* 1983:70-7.
5. Baker CL, Uribe JW, Whitman C. Arthroscopic evaluation of acute initial anterior shoulder dislocations. *Am Journal Sports Med* 1990;18:25-8.
6. Heckman JD, Levine MI. Traumatic closed transection of the biceps brachii in the military parachutist. *J Bone Joint Surg Am* 1978;60:369-72.
7. Nirschl RP, Pettrone FA. Tennis elbow. The surgical treatment of lateral epicondylitis. *J Bone Joint Surg Am* 1979;61:832-9.
8. Farrar EL 3rd, Lippert FG 3rd. Avulsion of the triceps tendon. *Clin Orthop Relat Res* 1981;161:242-6.
9. Hill JA. Epidemiological perspective on shoulder injuries. *Clin Sports Med* 1983;2:241-5.
10. Neviasser RJ, Neviasser TJ, Neviasser JS. Anterior dislocation of the shoulder and rotator cuff rupture. *Clin Orthop Relat Res* 1993;291:103-6.
11. Gerber C, Krushell RJ. Isolated rupture of the tendon of the subscapularis muscle. Clinical features in 16 cases. *J Bone Joint Surg Br* 1991;73:389-94.
12. Paley KJ, Jobe FW, Pink MM, Kvitne RS, ElAttrache NS. Arthroscopic findings in the overhand throwing athlete: evidence of posterior internal impingement of the rotator cuff. *Arthroscopy* 2000;16(1):35-40.
13. McEntire JE, Hess WE, Coleman S. Rupture of the pectoralis major muscle. A report of eleven injuries and review of fifty-six. *J Bone Joint Surg Am* 1972;54:1040-6.
14. Hanna CM, Glenny AB, Stanley SN, Caughey MA. Pectoralis major tears: comparison of surgical and conservative treatment. *Br J Sports Med* 2001;35:202-6.
15. Wolfe SW, Wickiewicz TL, Cavanaugh JT. Ruptures of the pectoralis major muscle. An anatomic and clinical analysis. *Am J Sports Med* 1992;20:587-93.
16. Rockwood CA Jr, Green DP, editors. Rockwood and Green's fractures in adults. 4th edition. London: Lippincott-Raven; 1996.

17. Hovelius L, Augustini BG, Fredin H, Johanssen O, Norlin R, Thorling J. Primary anterior dislocation of the shoulder in young patients. A ten-year prospective study. *J Bone Joint Surg Am* 1996;78:1677-84.
18. Itoi E, Sashi R, Minagawa H, Shimizu T, Wakabayashi I, Sato K. Position of immobilisation after dislocation of the glenohumeral joint. A study with use of magnetic resonance imaging. *J Bone Joint Surg Am* 2001;83:661-7.
19. Park JY, Espiniella JL. Rupture of pectoralis major muscle. A case report and review of literature. *J Bone Joint Surg Am* 1970;52:577-81.
20. Gerber C, Hersche O, Farron A. Isolated rupture of the subscapularis tendon. Results of operative repair. *J Bone Joint Surg Am* 1996;78:1015-23.
21. Bak K, Cameron EA, Henderson IJ. Rupture of the pectoralis major: a meta-analysis of 112 cases. *Knee Surg Sports Traumatol Arthrosc* 2000;8:113-9.
22. Surgical techniques in orthopaedics and traumatology. Volume 4. Arm, forearm and elbow. Co-ordinated by Professor Jacques Duparc. Oxford: Elsevier; 2002.
23. Post M. Current concepts in the diagnosis and management of acromioclavicular dislocations. *Clin Orthop Relat Res* 1985;200:234-47.