

Ministry of Defence

Synopsis of Causation

Eye Injuries

Author: Dr Douglas Dingwall, Medical Author, Medical Text, Edinburgh

Validator: Mr Wagih Aclimandos, Kings College Hospital, Denmark Hill, London

April 2010

Disclaimer

This synopsis has been completed by medical practitioners. It is based on a literature search at the standard of a textbook of medicine and generalist review articles. It is not intended to be a meta-analysis of the literature on the condition specified.

Every effort has been taken to ensure that the information contained in the synopsis is accurate and consistent with current knowledge and practice and to do this the synopsis has been subject to an external validation process by consultants in a relevant specialty nominated by the Royal Society of Medicine.

The Ministry of Defence accepts full responsibility for the contents of this synopsis, and for any claims for loss, damage or injury arising from the use of this synopsis by the Ministry of Defence.

1. Definition

- 1.1. The eyes are globular structures positioned within the bony [orbital cavities](#) in the front of the skull [lateral to](#) the nasal bones. Each globe occupies approximately 20% of the orbital volume and the contents of the remaining 80% include fat, muscles, blood vessels, nerves, and the [lachrymal gland](#).
- 1.2. Each globe consists of a fibrous outer layer, the sclera, that covers the whole surface except for the transparent cornea anteriorly and the emerging optic nerve and its central retinal artery posteriorly.
- 1.3. The posterior chamber of the globe contains vitreous humour, a transparent gel that fills the inner portion of the eyeball between the lens and the retina, the light-sensitive membrane that lines the chamber. The retina is separated from the sclera by the light-proof, pigmented, vascular layer of the choroid.
- 1.4. The anterior chamber contains aqueous humour, a transparent fluid that fills the inner portion of the eyeball between the cornea and the iris and lens.

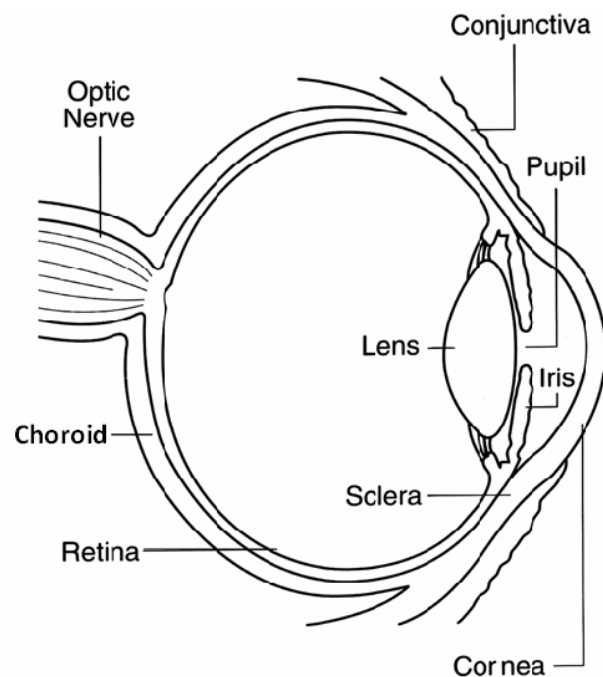


Fig. 1. Anatomy of the eye.

Courtesy: National Eye Institute, National Institutes of Health.

- 1.5. Light entering through the cornea passes through the aperture in the iris, the pupil, and is focussed by the lens onto the central part of the retina, the macula, where the specialised neurones respond by transmitting electrical impulses along the optic nerve to the brain. The macula consists of a very small but highly sensitive zone that enables detailed examination of a very circumscribed area of view directly in front of the eye. However, the peripheral areas of the retina also detect light that, although not accurately focussed, allows awareness of a much wider field of vision.

- 1.6. The eyelids and eyelashes offer some direct protection to the eye and eyelid blinking aids the spread of tears from the lachrymal gland over the corneal surface. The conjunctiva lines the inner aspect of the lids and extends over the visible sclera anteriorly to the limbus, the zone where the sclera merges with the cornea.
- 1.7. Movement of the eye is performed by the 4 rectus and 2 oblique extraocular muscles, that are supplied by [cranial nerves](#) III (oculomotor), IV (trochlear), and VI (abducens).
- 1.8. Most of the sensory supply to the eyelids, conjunctiva and cornea is delivered by the upper two divisions of cranial nerve V (trigeminal).
- 1.9. The orbital bones separate the eye and its surrounding tissues from the maxillary [sinus inferiorly](#), the frontal lobe of the brain [superiorly](#), the ethmoidal and sphenoidal sinuses and lachrymal sac [nasally](#), and the temporal fossa laterally.
- 1.10. **Types of trauma** that can affect the eye and nearby structures include:
 - **Impact of superficial foreign bodies** on the cornea or under the lids
 - **Abrasion** from light tangential contact with an external object
 - **Ulceration** by a variety of harmful agents and sometimes following abrasive trauma
 - **Burns** from chemical, thermal or radiation sources
 - **Blunt trauma** from a non-sharp object
 - **Laceration**, usually by a sharp object
 - **Penetration** of the globe by an object that remains within the globe
 - **Perforation** of the globe by an object that punctures the globe and passes right through
 - **Rupture** of the globe from excessive traumatic force
- 1.11. **Open-globe injuries** involve full-thickness wounds of the eye wall while **closed-globe injuries** do not.

2. Clinical features

- 2.1. The clinical features of eye injuries vary with the type and severity of the trauma, ranging from the irritating pain and minimal visual disturbance of a small foreign body on the cornea to total loss of vision and extreme pain from traumatic destruction of the globe.
- 2.2. Traumatic damage to the **eyelids and conjunctiva** can vary from minor scratches, lacerations, and burns to severe lacerations, considerable loss of tissue, and full thickness burns. Swelling and temporary or permanent visual impairment can be substantial.
- 2.3. Damage to the **cornea** causes a degree of visual impairment that varies with the severity of the damage or swelling of the corneal tissue that results. It may be accompanied by [hyphaema](#) of varying degrees.
- 2.4. Minor trauma to the **sclera** can occur but severe injury may cause penetration, perforation or rupture of the globe. Visual impairment can be substantial in such circumstances.
- 2.5. Injury to the **iris and its supportive structures** can cause [miosis](#) or [mydriasis](#), and tears in the iris can be minor and radial or can involve [dehiscence](#) from the ciliary body around part or all of its circumference (iridodialysis). This can give the appearance of a “secondary pupil” and can often be accompanied by hyphaema. Traumatic mydriasis can arise following blunt injury that compresses the anterior chamber, forcing rapid dilatation of the pupil with tearing of areas of the [pupillary sphincter](#) and its nerve supply. Injuries to the iris may cause [photophobia](#) and may be accompanied by blurring of vision.
- 2.6. **Lens** damage may cause [cataract](#) formation, [subluxation](#), or, rarely, total dislocation. Traumatic cataract may arise following blunt or penetrating injury, sometimes developing within hours if the lens capsule has been disrupted, but subacute and late onset can also occur. Substantial impairment of visual acuity may result. The topic of cataract is considered in more detail in the Synopsis *Cataract*.
- 2.7. Injury to the **retina** resulting from direct trauma, swelling (commotio) or from [detachment](#) causes the parts of the [visual field](#) corresponding to the damaged areas of the retina to be impaired. Where mechanical force is involved, damage to the **choroid** is also likely, with haemorrhage into the **vitreous humour**. Symptoms of this may include [floaters](#) of various shapes and sizes, shadows, and hazy vision. Substantial haemorrhage can cause severe visual loss.
- 2.8. **Optic nerve** injury can cause visual impairment in varying degrees from blurring to total blindness. The rare condition of [luxation](#) of the globe causes traction on the optic nerve with consequent injury.
- 2.9. Damage to any of the **external muscles of the eye** or to the **intraorbital cranial nerves** that supply may result in [diplopia](#) and reduced range of eye movement.
- 2.10. Injury to the **upper two divisions of the trigeminal nerve** as they traverse the orbit impairs sensation in the eyelids, the conjunctiva and cornea, and in areas of the face, [nasopharyngeal mucosa](#) and sinuses. Muscles of [mastication](#) may also be weakened on the corresponding side.

- 2.11. **Lacrimal gland** injury can impair production of tears, reducing their protective effect, and damage to the **intraorbital blood vessels and soft tissues** can produce haemorrhage and swelling that may result in substantial distortion and displacement of the eye, with marked impairment of vision. In addition, blood supply to the eye structures may be impaired causing [ischaemic](#) damage that can have additional effects on vision and on eye sensation and movement.
- 2.12. Any damage to the **orbital bones** carries a corresponding risk to the adjoining extraorbital structures.
- 2.13. To determine the extent and severity of damage to the eye and its surrounding tissues, **clinical examination** may include assessment of [visual acuity](#), colour vision, range of eye movement, pupillary reactions including [relative afferent pupillary defect](#), brightness perception, and [intraocular](#) pressure. Ophthalmoscopy and slit lamp examination are essential. Radiography and computed tomography (CT) are useful tools, as is ultrasonography, although it is not normally used if rupture of the globe is suspected. Magnetic resonance imaging is contraindicated if an iron-containing intraocular foreign body is suspected.¹
- 2.14. **Clinical features that may be associated with different types of trauma** are discussed in the following paragraphs.
- 2.14.1. **Foreign bodies** under the lids cause marked irritation and can result in abrasion of the cornea. Foreign bodies that become embedded in the surface layers of the cornea produce pain and may deposit toxic particles in the surrounding tissue and, if not quickly removed, may cause a stained ring.
- 2.14.2. **Abrasion** of the cornea is very painful, but if superficial and non-infected will usually be short-lived. Abrasion of the conjunctiva is less painful. Subconjunctival haemorrhage will usually resolve within days. Fluorescein instillation can be useful in visualising abrasions.
- 2.14.3. **Ulceration** of the cornea is very painful and may be prolonged. If so, inflammation of deeper tissues may ensue, particularly [iridocyclitis](#), causing photophobia and some impairment of vision. Corneal scrapes to identify likely organisms is essential..
- 2.14.4. **Burns** to the eye vary in severity according to the causative agent and to the depth of damage inflicted. The eyelids may give some protection, but any damage to the eye itself results in substantial pain, photophobia, conjunctivitis and excessive [lachrymation](#). More severe exposure can cause:
- Corneal and conjunctival damage and scarring
 - Cataract
 - [Glaucoma](#)
 - Perforation of the globe
- Severe visual impairment may result.
- 2.14.5. **Blunt trauma** can result in varying degrees of damage depending on the force

involved and the size of the blunt object. The rim of the orbit may reduce the traumatic forces applied to the orbital content if the offending object is larger than the orbital orifice. A light blow can cause [contusions](#), subconjunctival haemorrhage or superficial corneal abrasion, while heavier blows may cause:

- **Contusions** associated with significant underlying injury such as skull fractures
- **Corneal oedema**
- **Hyphaema** of varying degrees
- **Iridocyclitis**, traumatic mydriasis, radial tears in the iris, sphincter or varying degrees of dehiscence of the iris from the ciliary body
- **Subluxation or dislocation of the lens**, with resulting blurring or distortion of vision. [Posterior](#) dislocation of the lens may be accompanied by a tremor of the iris after rapid eye movements (iridodonesis)
- **Acute glaucoma** due to narrowing of the anterior chamber or to reduction of aqueous humour outflow. This can be secondary to hyphaema, scarring, or dislocation of the lens anteriorly
- **Cataract formation** due to lens capsule disruption allowing the lens [stroma](#) to absorb fluid and become cloudy
- **Vitreous detachment** with floaters or flashing lights.
- **Retinal and choroidal damage** with haemorrhage into the posterior chamber
- **Retinal detachment** which produces symptoms that may include floaters, flashing lights and visual field defects
- **Comotio retinae** which presents as an area of milky white retinal [oedema](#) that is usually most obvious in the area diametrically opposite the impact
- **Rupture of the globe**, which may present with reduced visual acuity, hypotony, severe subconjunctival haemorrhage, altered depth of the anterior chamber, and reduced range of eye movements. There may also be an irregularly shaped pupil, iridodialysis, and vitreous haemorrhage. CT scanning can be helpful for evaluation and is particularly important for detection of intraocular foreign bodies
- **Optic nerve damage** can substantially reduce visual acuity on the injured side and the [afferent pupillary defect](#) that occurs can be detected by testing for relative afferent pupillary defect by examining the light reaction of both pupils. Red/Green colour vision is affected.
- **Damage to other intraorbital tissues** including muscles, nerves, blood

vessels and other soft tissues. If the orbital bones are intact, [retrobulbar](#) haemorrhage may lead to acute increase in intraorbital pressure with risk of retinal artery [occlusion](#) and optic nerve ischaemia, in addition to [exophthalmos](#), reduced range of eye movement, and afferent pupillary defect. Substantial visual loss may result. Intraorbital foreign bodies may be present with or without global penetration

- **Fracture of the orbital bones.** The most vulnerable of the orbital walls are the floor and [medial](#) wall, and a blow on the globe can cause a fracture in either of these walls without a fracture of the orbital rim, a “**blowout**” fracture. [Prolapse](#) of some orbital content inferiorly or medially may occur. Characteristic features of this type of fracture include [periorbital](#) bruising, [epistaxis](#), facial tissue swelling on nose blowing, [subcutaneous emphysema](#), [enophthalmos](#) or exophthalmos, diplopia, limitation of eye movements (particularly looking up), [ptosis](#), and [maxillary hypoesthesia](#). Radiography may show the classic teardrop sign of orbital tissue herniated into the maxillary sinus. CT and ultrasound scanning may also be helpful.

2.14.6. **Lacerations of the eyelids** may be superficial, affecting only the skin layers, but if they involve the lid margins, muscles, tendons or ligaments, or encroach on the [canalicular system](#) or the [orbital septum](#) then more serious consequences may result for both appearance and function. Laceration of eyelids, bulbar conjunctiva, or cornea may accompany foreign body penetration of the globe.

2.14.7. The damage caused to the eye by **penetration** of the globe depends on the size, shape, and speed of the penetrating object and on its composition. A small, sharp object, such as a piece of shrapnel, projected at high speed may cause relatively little damage as it may slice through the eye tissues without distorting them significantly, while medium velocity bullets from handguns or pellets from air guns do distort the tissues as they pass through and can cause substantial damage. High velocity bullets from rifles can cause extensive damage to tissues as the missile is rapidly slowed, dissipating large amounts of energy. Types of damage that may be caused by penetrating objects are the same as those described for blunt trauma, but in addition, local toxic effects can result from **foreign bodies** containing:

- **Iron.** These may cause [siderosis](#) with staining of the iris, cataract, glaucoma, and retinopathy
- **High concentrations of copper.** These may cause violent inflammatory reaction within the globe. Alloys with relatively low concentrations of copper such as brass and bronze have a much milder effect
- **Lead.** These may cause lead poisoning if not removed
- **Organic material.** These are associated with a high risk of infection

Radiography is important in the detection of foreign bodies after a penetrating injury. Ultrasonography and computed tomography can also be useful but magnetic resonance imaging is contraindicated.¹ Ultrasonography may be contraindicated if global rupture is suspected.

2.14.8. The injuries resulting from **perforation** and the possible retention of foreign body particles are the same as those described for penetration.

2.14.9. **Further complications** that may occur following serious injury to the eye include:

- **Tissue destruction** from ischaemia
- **Glaucoma** from interference with aqueous flow
- **Secondary infection**, such as [endophthalmitis](#).² This may arise within a few hours but may be delayed for several months. It carries an increased risk of further deterioration in visual function and is described in more detail in the Synopsis *Eye Infections*
- **Sympathetic ophthalmia**.^{3,4} This inflammatory process that arises in the uninjured eye may occur weeks or even years after the initial trauma

3. Aetiology

- 3.1. The causes of different types of eye trauma are described in the following paragraphs.
- 3.2. **Foreign bodies** impinging on the surface of the eye include many types of dust particles, sand, or small insects, wood splinters from chiselling, and metal splinters from low speed grinding.
- 3.3. **Abrasion** can result from light tangential contact with objects such as tree twigs, plants, finger nails and clothing, or from persistent irritation from a foreign body under the eyelids.
- 3.4. **Corneal ulceration** can arise from a variety of causes including secondary infection of an abrasion, wearing of contact lenses, corneal exposure associated with unconsciousness, or corneal anaesthesia due to [neurological](#) disorder. These and other causes of corneal ulceration are described in the Synopsis *Eye Infections*.
- 3.5. **Burns** of eye tissues can be due to chemicals, heat, or radiation.^{5,6} The eyelids and cornea are most commonly affected but the depth of damage is dependent on the severity of exposure.
 - 3.5.1. **Chemical burns** usually result from industrial accidents or assault with strong acids or alkalis, but can also occur in the home due to powerful cleaning agents or solvents. The damaging action of the chemical tends to continue until it is removed, usually by flushing with water.
 - 3.5.2. **Acids** tend to produce a thickened layer of damaged corneal [epithelium](#) but rarely penetrate much further as neutralisation by tears and tissue proteins can be quite rapid.
 - 3.5.3. **Alkalis** penetrate quickly through the corneal tissue, destroying one layer after another. Anhydrous ammonia, for example, can reach the anterior chamber in less than 1 minute.
 - 3.5.4. Chemicals with particularly damaging effects include:
 - **Cement**, which reacts with water to form an alkali
 - **Petroleum** and other hydrocarbons, which dissolve lipids and damage cell membranes
 - **Sulphur mustard**, also known as mustard gas, yperite, or HD. It has been used in military conflict and is extremely damaging to [ocular](#) tissues⁷
 - **Phosphorus**, mainly the white form, which is also used in munitions
 - 3.5.5. **Thermal burns** usually arise from scalding, contact with a hot object, flames, or from flashes. These causes are discussed in more detail in the following paragraphs.
 - 3.5.6. **Scalding** from splashes of hot liquids is a common cause of thermal damage to the eyelids and cornea. Liquids involved include:
 - Water, which can be heated to 100 degrees C

- Water-based liquids such as soup or gravy, which are thicker than water and may remain on the eyelids or cornea for longer
- Cooking oils, which can be heated to 200 degrees C or more, are viscous, and adhere readily to eye tissues
- Grease from engines
- Tar used for road construction or for roofing. For road construction, tar has to be heated to 135 to 150 degrees C, while for roofing purposes, temperatures of 230 to 260 degrees C are needed. Also, tar is very viscous and cools rapidly into a solid form that adheres firmly to scalded tissues and can be very difficult to remove
- Molten metals used in industrial processes
- Scalding from **steam** can be particularly damaging as steam under pressure can reach temperatures much higher than 100 degrees C.

3.5.7. **Contact burns** of eye tissues may result from any hot material including sparks from fires or furnaces, ignited gunpowder from fireworks, and hot materials from industrial processes.

3.5.8. **Flame burns** of eye tissues can result from house fires, accidental contact with burning flammable liquids, bonfires, automobile accidents, military conflict, and many other causes. The eyelids can provide some degree of protection but are inadequate to prevent damage to deeper eye tissue in severe fire exposure situations.

3.5.9. **Flash burns** to eye tissues are usually due to explosions of flammable gases or liquids and are characterised by intense heat lasting for a very short time.

3.5.10. **Ultraviolet radiation** from sunlight or arc welding may damage the retina if allowed to penetrate the eye through failure to use adequate protection.⁸ Looking at the sun through binoculars or a telescope is particularly dangerous.

3.5.11. **Laser** technology is used in a wide variety of circumstances including industry, medicine, entertainment, and in a number of military applications. Although damage to the cornea can occur, the retina is particularly vulnerable to laser radiation within the visible and near infra-red wavelength range, and accidental exposure can readily lead to blindness which may be permanent.⁹ Laser weaponry designed to cause blindness in enemy troops has been banned under international law.^{10,11}

3.6. **Blunt trauma** to the eye can arise from a very wide variety of causes. Some of these are blows from assault, from impact with objects or people during sport, from motor vehicle accidents, from gunshot, and from the blast of explosions. These items are described in more detail in the following paragraphs.

3.6.1. **Assault** is a common cause of eye injury and the blows can be from fist, head, pointed finger, elbow, knee, shod foot, or from a variety of blunt weapons. The blows can have sufficient force to cause blowout fractures or rupture of the globe.

3.6.2. Similar injuries can arise during a variety of contact **sports** or from accidental impact

with the implements used, including golf and baseball clubs, tennis, badminton, and squash racquets, and hockey and lacrosse sticks.^{12,13,14,15,16,17,18} Balls used in golf, cricket, baseball, football, rugby, tennis, squash, lacrosse, and paintball games, hockey pucks and badminton shuttlecocks can all cause serious eye trauma varying with their hardness and size, and with the force of the impact that they make. The orbital rim may give partial protection to the globe when larger objects such as football and rugby balls are involved.

3.6.3. **Motor vehicle accidents** can give rise to serious eye trauma, including the rare injury of globe [luxation](#), probably caused by extreme deceleration of the head.³ Deployment of airbags in motor vehicle accidents can also cause blunt trauma to the eye,^{19,20} often resulting in contusions only but sometimes injuring the retina and optic nerve.

3.6.4. **Gunshot injuries** to the eye are usually severe, whether the missile is an air pellet, a bullet ball, a paintball, a rubber bullet, or a bullet from a high-powered rifle.^{21,22,23,24,25} Characteristics of severe blunt trauma including globe rupture are frequently accompanied by penetration or perforation.

3.6.5. Exposure to the **blast from explosions** caused by industrial accidents or exploding munitions can result in serious injury and death.^{26,27,28} In those who survive, it is difficult to be sure whether eye damage was due to the blast pressures alone or to the impact of accompanying fragments of material from the site of the explosion.²⁹ In such circumstances, globe penetration or perforation and the presence of intraocular foreign bodies is common.

3.7. **Lacerations** can be caused by a knife, a bayonet or other sharp object. Shrapnel from munitions explosions may cause lacerations only but the possibility of penetration or perforation of the globe is quite high.²⁸

3.8. **Penetration or perforation** can be caused by sharp weapons such as a knife or bayonet and by small, sharp objects such as shrapnel and metal fragments from high speed grinding or drilling. Gunshot projectiles can cause these types of injury as well as damage characteristic of blunt trauma.^{26,27,28,30} Multiple penetration injuries associated with multiple facial lacerations are often caused by 'Windscreen' injuries. These have become less frequent with the introduction of seat-belt regulations.

4. Prognosis

- 4.1. While closed-globe injuries generally have a better prognosis than open-globe injuries, modern ophthalmological techniques, including microsurgery and use of lasers, can produce very good results in the repair of some severely damaged eyes, provided delay in treatment is kept to a minimum.
- 4.2. However, trauma to the eye can vary enormously in its effects on visual outcome, and it can be very difficult for ophthalmologists to achieve consistency in estimating the prognosis in individual cases. In an attempt to overcome this problem, workers analysed over 2500 eye injury reports extracted from the databases of the United States and Hungarian Eye Injury Registries.³¹ Statistical analysis of over 100 variables eventually enabled them to devise the **ocular trauma score (OTS)** that allows reliable prediction of the long-term visual acuity achievable in the injured eye.
- 4.3. To obtain the OTS, each of 6 identifiable factors relating to the eye at the time of injury is allocated a numerical value. The value for level of initial visual acuity is positive and that for each of the other factors present is negative. The total of these values is the ocular trauma score, which is indicative of the likely final visual acuity, the highest score being the best.
- 4.4. The 6 factors assessed are:
 - Initial visual acuity
 - Rupture of the globe
 - Endophthalmitis
 - Perforation of the globe
 - Retinal detachment
 - Afferent pupillary defect
- 4.5. A later study of eye injuries sustained in combat by troops in Iraq, Afghanistan, and other theatres,³² concluded that the OTS is a valid tool that enables the severity of eye injury to be correlated with the final visual acuity.
- 4.6. The study also found that in these combat zones the poorest visual prognosis was for open-globe injuries combined with damage to surrounding structures or to nerve tissue associated with ocular function.
- 4.7. The damaged tissues causing traumatic mydriasis may heal over several months but full recovery does not always ensue.

5. Summary

- 5.1. Injuries to the eye and surrounding structures can arise from several different types of trauma, the main ones being impact of superficial foreign bodies, abrasion, ulceration, burns, blunt trauma, laceration, penetration, perforation, and rupture.
- 5.2. Clinical features of such injuries vary widely according to the parts of the eye and its surrounding structures that are damaged, and with the type of trauma inflicted.
- 5.3. Damage may include corneal injury, hyphaema, injury to the iris, cataract, lens dislocation, vitreous haemorrhage, retinal injury or detachment, optic nerve injury, intraocular or intraorbital foreign body, injury to any of the extraocular orbital contents, fracture of orbital bones, or disruption of the integrity of the globe.
- 5.4. Visual impairment encompasses reduced visual acuity, blurring, diplopia, field defects, reduced eye movements, and total blindness.
- 5.5. Causes of eye trauma include superficial foreign bodies, light contact with eye surfaces, undue corneal exposure, burns from chemicals, hot substances, and ultraviolet or laser radiation, assault, sport injuries, sharp objects, motor vehicle accidents, gunshot injuries, and blast from explosions.
- 5.6. The prognosis for visual outcome varies with the type and severity of the injuries and can be reliably assessed using the ocular trauma score.

6. Related Synopses

Cataract

Eye infections

Glaucoma

7. Glossary

afferent pupillary defect	A condition of the eye where the pupil fails to react appropriately to the level of light passing through it.
canalicular system	The tubes of the tear drainage system.
cataract	Opacity within the lens.
cranial nerves	Nerve trunks that connect directly with the brain.
contusions	Bruises.
detachment (of the retina)	Loss of contact of part of the retina with the choroid.
dehiscence	Detachment along natural lines.
diplopia	Double vision.
endophthalmitis	Inflammation of tissues within the eye.
enophthalmos	Sunken eyeball. Cf <i>exophthalmos</i> .
epistaxis	Nose bleed.
epithelium	Cellular lining.
exophthalmos	Protruding eyeball. Cf <i>enophthalmos</i> .
extraocular	Outside the eyeball. Cf <i>intraocular</i> .
floaters	Spots that appear to drift in front of the eye, caused by a shadow cast on the retina by vitreous debris or separation of the vitreous humour from the retina.
glaucoma	Eye disease characterised by an increase in intraocular pressure.
hyphaema	Haemorrhage into the anterior chamber.
inferiorly	In a downward direction. Cf <i>superiorly</i> .
intraocular	Inside the eyeball. Cf <i>extraocular</i> .
iridocyclitis	Inflammation of the iris and its adjacent

	structures.
ischaemic	Suffering from a deficiency in the arterial blood supply.
lachrymal gland	Gland that produces tears.
lachrymation	Production of tears.
lateral to	To the outside of i.e. further away from the midline.
luxation	Complete dislocation.
mastication	Chewing.
maxillary hypoaesthesia	Reduced sensation in the cheek area.
medial	Nearer the midline.
miosis	Contraction of the pupil.
mydriasis	Dilatation of the pupil.
nasally	Towards the nose.
nasopharyngeal mucosa	Lining of the nose and throat.
neurological	Pertaining to the nervous system.
occlusion	Blockage.
ocular	Pertaining to the eye.
oedema	An abnormal build up of fluid between tissue cells in the body.
ophthalmoscopy	Examination of the inner structures of the eye.
orbital cavities	Bony eye sockets in the skull.
orbital septum	Fibrous membrane attached to the margin of the orbit and extending to the lids.
periorbital	Situated around the eye socket.
photophobia	Abnormal visual intolerance of light.
posterior	Towards the back.
prolapse	Displacement of tissue.

ptosis	Drooping of the upper eyelid.
pupillary sphincter	Ringlike band of muscle fibres in the iris that constrict the pupil.
relative afferent pupillary defect	An abnormal reaction of both pupils to testing with light.
retrobulbar	Behind the eyeball.
siderosis	Tissue reaction around iron particles.
sinus	Air space within bone.
stroma	Fibrous structure.
subcutaneous emphysema	Accumulation of air under the skin.
subluxation	Partial dislocation.
superiorly	In an upward direction. Cf <i>inferiorly</i> .
visual acuity	Ability to see fine detail.
visual field	Area simultaneously visible to one eye without movement of the eye.

8. References

- ¹ Ta CN, Bowman RW. Hyphema caused by a metallic intraocular foreign body during magnetic resonance imaging. *Am J Ophthalmol* 2000;129(4):533-4.
- ² Reynolds DS, Flynn HW Jr. Endophthalmitis after penetrating ocular trauma. *Curr Opin Ophthalmol* 1997;8(3):32-8.
- ³ Bord SP, Linden J. Trauma to the globe and orbit. *Emerg Med Clin North Am* 2008;26(1):97-123, vi-vii.
- ⁴ Ramadan A, Nussenblatt RB. Visual prognosis and sympathetic ophthalmia. *Curr Opin Ophthalmol* 1996;7(3):39-45.
- ⁵ Renard G. Physiopathology of eye burns. *J Fr Ophtalmol* 2004;27(10):1164-9.
- ⁶ Borderie V. Clinical aspects of corneal burns. *J Fr Ophtalmol* 2004;27(10):1170-4.
- ⁷ Solberg Y, Alcalay M, Belkin M. Ocular injury by mustard gas. *Surv Ophthalmol* 1997;41(6):461-6.
- ⁸ Sliney DH. Risks of occupational exposure to optical radiation. *Med Lav* 2006;97(2):215-20.
- ⁹ Barkana Y, Belkin M. Laser eye injuries. *Surv Ophthalmol* 2000;44(6):459-78.
- ¹⁰ Seet B, Wong TY. Military laser weapons: current controversies. *Ophthalmic Epidemiol* 2001;8(4):215-26.
- ¹¹ Hudson SJ. Eye injuries from laser exposure: a review. *Aviat Space Environ Med* 1998;69(5):519-24.
- ¹² Rodriguez JO, Lavina AM, Agarwal A. Prevention and treatment of common eye injuries in sports. *Am Fam Physician* 2003;67(7):1481-8.
- ¹³ Jones NP. Orbital blowout fractures in sport. *Br J Sp Med* 1994;28(4):272-5.
- ¹⁴ Townley D, Kirwan C, O'Keefe M. Golf – recognising the risk of severe eye injury. *Ir Med J* 2008;101(6):167-9.
- ¹⁵ Kent JS, Eidsness RB, Colleaux KM, Romanchuk KG. Indoor soccer-related eye injuries: should eye protection be mandatory? *Can J Ophthalmol* 2007;42(4):605-8.
- ¹⁶ Capao-Filipe JA, Fernandes VL, Barros H et al. Soccer-related ocular injuries. *Arch Ophthalmol* 2003;121(5):687-94.
- ¹⁷ Horn EP, McDonald HR, Johnson RN et al. Soccer ball-related retinal injuries: a report of 13 cases. *Retina* 2000;20(6):604-9.
- ¹⁸ Knorr HL, Jonas JB. Retinal detachments by squash ball accidents. *Am J Ophthalmol* 1996;122(2):260-1.
- ¹⁹ Kenney KS, Fanciullo LM. Automobile air bags: friend or foe? A case of air bag-associated ocular trauma and a related literature review. *Optometry* 2005;76(7):382-6.
- ²⁰ Pearlman JA, Au Eong KG, Kuhn F, Pieramici DJ. Airbags and eye injuries: epidemiology, spectrum of injury, and analysis of risk factors. *Surv Ophthalmol* 2001;46(3):234-42.
- ²¹ Shuttleworth GN, Galloway P, Sparrow JM, Lane C. Ocular air gun injuries: a one-year surveillance study in the UK and Eire (BOSU). 2001-2002. *Eye* 2008. [Epub ahead of print].
- ²² McGwin G Jr, Hall TA, Xie A, Owsley C. Gun-related eye injury in the United States, 1993-2002. *Ophthalmic Epidemiol* 2006;13(1):15-21.
- ²³ Lavy T, Asleh SA. Ocular rubber bullet injuries. *Eye* 2003;17(7):821-4.
- ²⁴ Fineman MS. Ocular paintball injuries. *Curr Opin Ophthalmol* 2001;12(3):186-90.
- ²⁵ Thach AB, Ward TP, Dick JS 2nd et al. Intraocular foreign body injuries during Operation Iraqi Freedom. *Ophthalmology* 2005;112(10):1829-33.
- ²⁶ Weichel ED, Colyer MH. Combat ocular trauma and systemic injury. *Curr Opin Ophthalmol* 2008;19(6):519-25.
- ²⁷ Thach AB, Johnson AJ, Carroll RB et al. Severe eye injuries in the war in Iraq, 2003-2005. *Ophthalmology* 2008;115(2):377-82.
- ²⁸ Biehl JW. Military and civilian penetrating eye trauma: anesthetic implications. *AANA J* 2001;69(1):31-7.
- ²⁹ Abbotts R, Harrison SE, Cooper GL. Primary blast injuries to the eye: a review of the evidence. *J R Army Med Corps* 2007;153(2):119-23.
- ³⁰ Weichel ED, Colyer MH, Ludlow SE et al. Combat ocular trauma visual outcomes during Operations Iraqi and Enduring Freedom. *Ophthalmology* 2008;115(12):2235-45.
- ³¹ Kuhn F, Maisiak R, Mann L et al. The Ocular Trauma Score (OTS). *Ophthalmol Clin North Am* 2002;15(2):163-5, vi.

³² Globocnik-Petrovic M, Lumi X, Drnovsek-Olup B. Prognostic factors in open eye injury managed with vitrectomy: retrospective study. *Croat Med J* 2004;45(3):299-303.